



AOGD BULLETIN

Volume 18; Issue No.5; September 2018

Price: ₹ 30 only

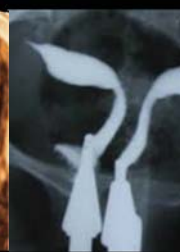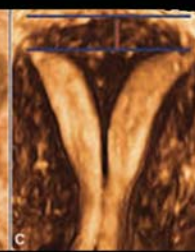
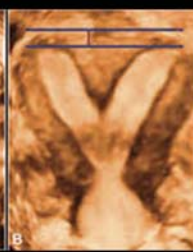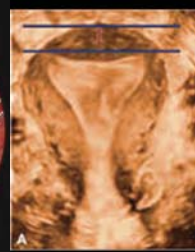


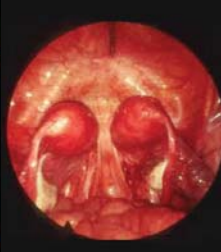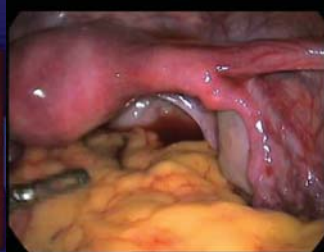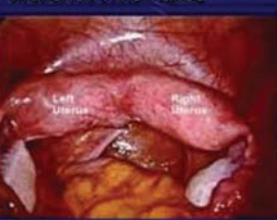AOGD Theme 2018-19
Empowering Providers:
Enhancing Women's Health

Issue: Current Update
Medicolegal Issues & Ethics
Mullerian Anomalies



Mullerian Anomalies



AOGD SECRETARIAT

Department of Obstetrics and Gynecology
Lady Hardinge Medical College & Smt. Sucheta Kriplani Hospital, New Delhi-110001
secretarylhaogd2018@gmail.com

www.aogd.org

AOGD Office-Bearers 2018-19



Dr Abha Singh
President



Dr Manju Puri
Vice President



Dr Reena Yadav
Scientific Advisor



Dr Kiran Aggarwal
Hon. Secretary



Dr Anuradha Singh



Dr Nishtha Jaiswal

Joint Secretaries



Dr Prabha Lal
Treasurer



Dr Shilpi Nain
Co Treasurer

Editorial Board



Dr Ratna Biswas
Editor



Dr Manisha Kumar
Web Editor



Dr Pikee Saxena



Dr Sharda Patra



Dr Swati Agrawal

Co-Editors



Dr Vidhi Chaudhary
Co-Web Editor



Dr Meenakshi Singh
Clinical Secretary



Dr Muntaha



Dr Amrita



Dr Aastha Shrivastava
Public Relations & Hospitality



Dr Deepika Meena



Dr Aishwarya Kapur

AOGD Executive Committee 2018-19

President

Dr Abha Singh

Vice President

Dr Manju Puri

Scientific Advisor

Dr Reena Yadav

Hony. Secretary

Dr Kiran Aggarwal

Treasurer

Dr Prabha Lal

Editor

Dr Ratna Biswas

Web Editor

Dr Manisha Kumar

Joint Secretaries

Dr Anuradha Singh

Dr Nishtha Jaiswal

Co-Treasurer

Dr Shilpi Nain

Co-Editors

Dr Pikee Saxena

Dr Sharda Patra

Dr Swati Aggarwal

Co-Web Editor

Dr Vidhi Chaudhary

Clinical Secretary

Dr Meenakshi Singh

Public Relations & Hospitality

Dr Muntaha

Dr Vidhi Chaudhary

Dr Amrita

Dr Aastha Shrivastava

Dr Deepika Meena

Dr Aishwarya Kapur

Executive Members

Dr Achala Batra

Dr Amita Suneja

Dr Anjali Tempe

Dr B K Goyal

Dr Dinesh Kansal

Dr Indu Chawla

Dr J B Sharma

Dr Kanwal Gujral

Dr Manju Khemani

Dr Malavika Sabharwal

Dr Nirmala Aggarwal

Dr Ranjana Sharma

Dr Renu Misra

Dr Sadhna Gupta

Dr Sangeeta Gupta

Dr S N Basu

Dr Suman Lata

Dr Vijay Kadam

AOGD Secretariat

Department of Obstetrics and Gynecology

Lady Hardinge Medical College & Smt. Sucheta Kriplani Hospital, New Delhi 110001

Tel No: 011-23408297; Email: secretary@haogd2018@gmail.com

www.aogd.org

Patrons

Dr S N Mukherjee

Dr Urmil Sharma

Dr Kamal Buckshee

Dr Neera Aggarwal

Advisors

Dr Gauri Devi

Dr Geeta Radhakrishnan

Dr Reva Tripathi

Dr S B Khanna

Dr Sharda Jain

Dr Usha Gupta

Ex Officio

Executive Past Presidents

Dr P Chadha (1990-94)

Dr Neera Agarwal (1994-97)

Dr Maya Sood (1997-99)

Dr D Takkar (1999-2001)

Dr Sudha Salhan (2001-03)

Dr Swaraj Batra (2003-05)

Dr N B Vaid (2005-06)

Dr S S Trivedi (2006-07)

Dr Suneeta Mittal (2007-08)

Dr I Ganguli (2008-09)

Dr Shashi Prateek (2009-10)

Dr U Manaktala (2010-11)

Dr Neeraj Goel (2011-12)

Dr C Raghunandan (2012-13)

Dr Alka Kriplani (2013-14)

Dr U P Jha (2014-15)

Dr Pratima Mittal (2015-16)

Dr Sudha Prasad (2016-17)

Immediate Past President (2017-2018)

Dr Shalini Rajaram

Immediate Past Secretary (2017-2018)

Dr Abha Sharma

President Elect (2019-2020)

Dr Sunesh Kumar

Vice President FOGSI

Dr Pratima Mittal

Chairpersons

AOGD Sub-Committees

Dr Susheela Gupta

Dr Surveen Ghuman

Dr Abha Sharma

Dr A G Radhika

Dr Amita Jain

Dr Shakuntla Kumar

Dr Ashok Kumar

Dr Vatsla Dadhwal

Dr Rupinder Sekhon

Dr Anjali Tempe

Dr Renu Misra

Dr Nalini Mahajan



AOGD BULLETIN

Vol. 18, No.5; September, 2018

Contents

| | |
|--|----|
| BEST PRACTICES - Informed Consent in Obstetrical Procedures | 7 |
| <i>Devender Kumar, Asmita Patil</i> | |
| RECENT ADVANCES - Ethics of In-Utero Prenatal Diagnosis and Therapy | 10 |
| <i>Dipika Deka</i> | |
| CONTROVERSY - Hysterectomy in A Mentally Challenged Girl | 14 |
| <i>Sunita Malik, Mukta Rawat</i> | |
| CASE APPROACH - Breaking Bad News in Sudden Intrauterine Death/Sudden Maternal Death | 17 |
| <i>Manisha Kumar</i> | |
| DISTRESS TO DE-STRESS - A Beautiful Mind | 20 |
| <i>Mohit D Gupta</i> | |
| CROSSWORD - The Maze of Knowledge and Pictorial Quiz | 22 |
| <i>Swati Agrawal</i> | |
| BEST PRACTICES - Management of Mullerian Agenesis | 31 |
| <i>Karoon Agrawal, Deepti Gupta</i> | |
| RECENT ADVANCES - Uterine Transplantation | 35 |
| <i>Varsha Priyadarshini, Amita Suneja</i> | |
| CONTROVERSY - Surgical Treatment in Nulliparous Women with Intrauterine Septum | 39 |
| <i>Pramathes Das Mahapatra, Mayoukh Kumar Chakraborty</i> | |
| CASE APPROACH - Cervical Agenesis/ Dysgenesis | 41 |
| <i>Rashmi Ahuja, Usha Gupta</i> | |
| JOURNAL SCAN | 46 |
| <i>Ratna Biswas</i> | |
| Proceedings of AOGD Monthly Clinical Meeting | 49 |

Disclaimer

The advertisements in this bulletin are not a warranty, endorsement or approval of the products or services. The statements and opinions contained in the articles of the AOGD Bulletin are solely those of the individual authors and contributors, and do not necessarily reflect the opinions or recommendations of the publisher. The publisher disclaims responsibility of any injury to persons or property resulting from any ideas or products referred to in the articles or advertisements.

Plagiarism Disclaimer

Any plagiarism in the articles will be the sole responsibility of the authors, the editorial board or publisher will not be responsible for this.

Publisher/Printer/Editor

Dr Ratna Biswas on behalf of Association of Obstetricians & Gynecologists of Delhi.

Printed at

Process & Spot C-112/3, Naraina Industrial Area, Phase-1, New Delhi 110 028

Published from

Department of Obstetrics and Gynecology

Lady Hardinge Medical College & Smt. Sucheta Kriplani Hospital, New Delhi - 110001

Editor

Dr Ratna Biswas

Ph. No. 011-23408297; Email: secretary@haogd2018@gmail.com

Total number of pages = 52

President's Message



Dear Friends,

Warm Seasons greetings!

Our young and enthusiastic team of office bearers are trying to put tireless efforts to match the efforts of our predecessors. I hope all of you benefitted from reading the previous issue on “Urogynecology and Labour room practices”, a subject common in day to day practice. Urogynaecological problems has considerable impact on the quality of life of woman and yet is not appropriately addressed. Management of labour is a real challenge, inculcating healthy labour room practices can be a useful step in this direction.

The theme for this month's issue “Medicolegal & ethical issues in Obstetrics and Gynaecology and Mullerian anomalies” are extremely important with challenges in its management. Understanding the importance of medicolegal & ethical issues in day to day practice will be enlightening for everyone. There is an urgent need for reinforcing the value of proper counselling of patients and their relatives with informed written consent, so as to curb litigations.

Preparations for the 40th Annual Conference of AOGD (24th & 25th November, 2018) are in full swing. You will be kept updated through the bulletin, WhatsApp, sms, website etc. Registration and paper submissions are open to all. We request all the members to avail early bird registration. Every year there are new entrants to the profession at Delhi so the members are requested to enrol at least two members each for further strengthening our association. We hope for an active participation by all the AOGD members in the upcoming Annual Conference. I urge all of you to register in large numbers, participate actively by paper presentations and while updating yourselves enjoy this academic feast with your friends.

Best Wishes

Warm regards

Dr Abha Singh
President AOGD (2018-19)

Secretary's Message



Greetings to all the members,

The change in the feel of the air must have been felt by all Delhites. Yes the season is changing and we are heading for the most pleasant time in the year in Delhi.

It also is the time for preparing for the Annual academic feast the AOGD Annual conference to be held on 24th and 25th November with the preconference workshops planned on 22nd and 23rd November 2018. The preconference workshops are on two days so that you can attend more than one workshop if you want to do so.

The organizing team is working hard to present a scientific program addressing all facets of our speciality from preventive to latest in the field. We request all the AOGD members to register well in time. You can send in your cheques/drafts/ or do RTGES payment for the registration.

All seniors and juniors who want to present their work, research and new inventions should not miss this opportunity and put in their abstracts for free papers and posters. Submission for the abstracts is open including for the competition papers. The details are on the website aogd.org.

Last month was a happening time for AOGD. From VBAC CME at Sitaram Bharatiya, Breast and cervical cancer screening camps and CME at DDU Hospital, Exhaustive CME on Oncology at Apollo Hospital, the house was full in all.

The Postgraduate teaching module started by the Infertility committee AOGD deserves special mention. The quest for knowledge is amply indicated by a full Medical Education Hall at LHMC bursting from its extended capacity. We congratulate Dr Surveen Ghumman chairperson Infertility committee, Dr Manju Puri the course coordinator for the conception and implementation of the idea and especially Dr Abha Singh President AOGD to guide and support the program.

The DGES conference spearheaded by Dr Malavika Sabharwal was a treat for anyone interested in minimally invasive Gynecology. The continuous live demonstration of endoscopic cases was a visual and academic feast

The bulletins brought out by Dr Ratna Biswas and her team have been well appreciated by the members. The present issue on Medico legal ethical issues and Mullerian duct anomalies addresses the challenging and difficult situations in our day to day practice. Hope you will enjoy reading it.

Once again reminding the members to register for the conference so that we can organize better.

Please communicate on secretarylhagod018@gmail.com for any inputs or suggestions.

Dr Kiran Aggarwal
Secretary AOGD (2018-19)

Monthly Clinical Meeting

Monthly Clinical Meet will be held at Deen Dayal Upadhyay Hospital, New Delhi
on Friday, 28th September, 2018 from 04:00pm to 05:00pm.

Editorial Team's Message



Dr Ratna Biswas
Editor



Dr Pikee Saxena



Dr Sharda Patra
Co-Editors



Dr Swati Agrawal

Dear Friends,

The September issue has brought forth two important topics, “Medico-Legal Issues & Ethics” and “Mullerian Anomalies”. Informed consent is a vital document in our practice and should contain all necessary information like the description of procedure including the chances of success, alternative methods of management, complications, follow up etc. Our opening article is on “Best Practices in Informed Consent in Obstetrical Procedures” which will be very useful to our readers.

Recent advances section covers “Ethics of In-Utero Prenatal Diagnosis and Therapy”. Since majority of these procedures are invasive so the benefit versus risk should be carefully weighed before deciding on the procedure. The therapies which are experimental should be only undertaken under research setting with proper informed written consent. This article provides new insights on rights of the women and the unborn child.

“Is there a role of hysterectomy in a mentally challenged girl ?” This is covered in the controversy section.

When an adverse event like an unexpected maternal or fetal death occurs it is an extremely sad moment for the relatives. Coping mechanism are not in force and reactions may be extreme. It calls for lot of compassion, wisdom and empathy in “Breaking sudden and unexpected bad news” which has been dealt in our case approach section

The motivational article is on “A Beautiful Mind”. Mind represents a set of cognitive faculties. A strong mind represents strength of character and our focus should be on developing a strong and beautiful mind.

The gynecology section deals with Mullerian anomalies. “Best Practices in Management of Mullerian Agenesis” is the opening article in this section. Vaginal reconstruction is the mainstay in the management of this condition, where the aim is to provide a functional vagina for sexual activity. This article provides an in - depth account of the nonsurgical and surgical procedures for vaginal reconstruction.

With the advent of “Uterine Transplantation” newer avenues have opened for women without uterus to give birth to a child. The procedure is complex and requires good vascular anastomosis of the uterine artery and vein with the external iliac vein. Post procedural immuno-suppressants are required with a close follow up to prevent graft rejection. Pregnancy by IVF and natural conception both have occurred in recipients of uterine transplant.

Whether or not to intervene in a “Nulliparous women with uterine septum” is dealt in the controversy section. “Management of cervical agenesis and dysgenesis” is covered under the case approach section. Standard management of cervical agenesis has been hysterectomy but recent ventures on utero-vaginal anastomosis has been promising. The restoration of normal menstruation and also pregnancies have resulted after such procedures.

Advances in management in this field is outstanding but not without shortfalls and complications. Key to success is meticulous adherence to safe and appropriate surgical principles, regular follow up's and repeat surgeries if needed.

The maze of knowledge-crossword and the pictorial quiz is very interesting and worth attempting.

Journal scan has brought to you recent reviews on uterine transplantation and uterovaginal anastomosis, both procedure still in their infancy but with promising results.

Those who missed out attending the monthly clinical meeting can refer to the proceeding to get an account of the interesting cases deliberated.

Each and every article is a masterpiece and we sincerely thank all our authors for their contribution. Do post us your comments and suggestions.

Happy Reading !!!

Editorial Team

Informed Consent in Obstetrical Procedures

Devender Kumar¹, Asmita Patil²

¹Professor, Obs & Gynae, MAMC, New Delhi; ²Associate Professor, Physiology, AIIMS, New Delhi



Dr Devender Kumar

The process of communication between a patient & physician that results in the patient's authorization or agreement in full knowledge of the possible consequences i.e. benefits and risks, to undergo a specific medical intervention is called informed consent. This technical term was first used by attorney, Paul G. Gebhard in a medical malpractice court case in United States in 1957¹. It is a written, signed, and dated vital document in patient's record. The concept of consent arises from autonomy of patient, basic human rights and part of the ethical medical practices and research. Any act, done without permission, is classified as "battery"- physical assault and is punishable excluding emergency life-saving procedures like cardio-pulmonary resuscitation.

Consent is considered implied when a patient enters a doctor's chamber and expressing his/her problem for general physical examination and routine investigations. But, internal or genital examination (especially in a female), invasive tests and risky procedures require specific expressed consent. Expressed (explicit or informed) consent can be oral or written. Written consents are preferable in situations involving long-term follow-up, high-risk interventions, cosmetic procedures and surgeries.

History of informed consent in medical practice goes back to 500 BC when the Hippocratic Oath gave guidelines for the conduct of medical professionals². In that era, physicians used to conceal information from patients citing best care (doing good). The rationale of beneficence model for care was that doctor knew better than the patient. "Promise of cure to every patient" was rationalized in the hope that good prognosis would inspire a good outcome to treatment. It was accepted that the physician could lie or withhold information on the premises of providing better treatment.

In 18th-century Benjamin Rush advocated that doctors ought to share as much information as possible with patients². He recommended that doctors educate the public and respect a patient's informed decision to accept therapy. Thomas Percival in his book entitled Medical Ethics said that patients have a right to truth.

In 1847, American Medical Association published first edition of American Medical Association Code of Medical Ethics^{3,4}. On December 9, 1946 in Nuremberg, Germany a series of trials were held to hold members of the Nazi party responsible for a multitude of war crimes (known as the Nuremberg trials)⁵. In one of the

trials, which became known as the "Doctors' Trial," German physicians responsible for conducting unethical medical procedures on humans during the war were tried, focusing on inhumane and unethical human experiments in concentration camps in addition to 3,500,000 sterilizations. While the trials were being held, 10 points defining legitimate medical research were created by Counsel for War Crimes called "Nuremberg Code" which included informed consent, absence of coercion, properly formulated scientific experimentation, and beneficence towards experiment participants^{5,6}.

Nuremberg Codes^{5,6} were as follows:

1. Participation in experiments should be voluntary, well-informed consent with understanding of the human subject in a full legal capacity.
2. The experiment should aim at positive results for society that cannot be procured in any other way.
3. It should be based on previous knowledge (e.g., an expectation derived from animal experiments) that justifies the experiment.
4. The experiment should be set up in a way that avoids unnecessary physical and mental suffering and injuries, except, in experiments where the experimental physicians also serve as subjects.
5. It should not be conducted when there is a reason to believe that it implies a risk of death or disabling injury.
6. The risks of the experiment should be in proportion to (that is, not exceed) the expected humanitarian benefits.
7. Preparations and facilities must be provided that adequately protect the subjects against the experiment's risks.
8. The staff who conduct or take part in the experiment must be fully trained and scientifically qualified.
9. The human subjects must be free to immediately quit the experiment at any point when they feel physically or mentally unable to go on.
10. Likewise, the medical staff must stop the experiment at any point when they observe that continuation would be dangerous.

In response to the criticism of unethical human experimentation, "Guidelines for New Therapy and Human Experimentation" were issued in Germany. Those guidelines were based on beneficence and non-maleficence, but also stressed legal doctrine of informed consent forbidding any intervention

without consent. Nuremberg Codes are considered to be the most important document in the history of clinical research ethics and had a massive influence on global human rights. Nuremberg Code and the Declaration of Helsinki were the regulations issued by the United States Department of Health and Human Services for the ethical treatment of human subjects, and are used in Institutional Review Boards (IRBs)⁷. In addition, the idea of informed consent was universally accepted and now constitutes Article 7 of the United Nations' International Covenant on Civil and Political Rights. It also served as the basis for International Ethical Guidelines for Biomedical Research Involving Human Subjects proposed by the World Health Organization. Medical practice today is not simple because of various factors impinging on the doctor-patient relationship and sometimes patient approach doctors with unreasonable demands and unrealistic expectations.

Valid informed consent has three essential components^{8,9}

- Disclosure: the information necessary to make an autonomous decision and also to ensure that the subject adequately understands the information provided. This latter requirement implies that a written consent form be written in lay language suited for the comprehension skills of subject population, as well as assessing the level of understanding through conversation.
- Capacity: pertains to the ability of the subject to both understand the information provided and form a reasonable judgment based on the potential consequences of his/her decision.
- Voluntariness refers to the subject's right to freely exercise his/her decision making without being subjected to external pressure such as coercion, manipulation, or undue influence.

Patient's perception of risk of a medical intervention is also highly individualistic, variable and unpredictable. The information provided to a patient should include all material risks. But the list of risks and side effects cannot be exhaustive to the level of absurdity and impracticality. A prudent or reasonable patient would expect to make a knowledgeable decision about the course of action to be taken in the presence of alternatives after adequate information. It's not easy to determine the extent of information disclosure to patient and there is no level defined to say "Everything informed". Informed consent must include disclosure of following information to patient / guardian^{10,11}.

- The condition/disorder/disease that the patient is having/suffering from
- Necessity for further testing
- Natural course of the condition and possible complications
- Consequences of non-treatment
- Treatment options available
- Potential risks and benefits of treatment options

- Duration and approximate cost of treatment
- Expected outcome
- Follow-up required

Braddock et al in 1999, published that only 9% (n=1052) of decisions were completely informed¹². In another study Bottrel et al found that only 26% (n=540) included all 4 elements (nature of procedure, risk, benefits & alternative) in informed consent¹³. Low literacy, stress, confusion, lack of time and wrong assumptions are few known fallacies of informed consent. Regarding informed consent, ACOG 2009 has mentioned two major elements and they are comprehension and freedom to express¹⁴.

Consent given under fear of injury, intimidation, misconception or misrepresentation of facts can be held invalid. Patient should be given opportunity to ask questions and clarify all doubts. There must not be any kind of coercion. Consent must be voluntary and patient should have the freedom to revoke the consent. Patient must be an adult, competent and in sound mind to give consent. In case of minor, consent must be obtained from a parent or legal guardian. In case of incapacitated persons, close family members or legal guardians can give consent. If a patient knowingly prefers not to get full information that attitude also needs to be respected as a part of patient's right to autonomy. Doctor's duty is to explain the possible consequences of non-treatment and benefits of treatment and leave the decision to the patient. If patient refuses due to personal reasons, such informed refusals must be documented clearly. It's known as "Informed Refusal". A patient's freedom cannot impinge on the rights of others or cause harm to a third party or community. Discharge against medical advice also falls into this category and needs to be properly recorded.

Informed consent in Obstetrics^{15,16,17}

Pre-Natal Diagnostic Techniques (Regulation and Prevention of Misuse) Act, 1994 (PNDT), was amended in 2003 to Pre-Conception and Pre-Natal Diagnostic Techniques (PCPNDT) Act. It is essential informed agreement to use ultrasonography and to prohibit the use of technology sex determination. Cafeteria approach with autonomy to choose contraception by couple is another important informed consenting for patient satisfaction and to prevent litigation. Autonomy of patient is priority in these non-therapeutic uses of medical or surgical methods. Beneficence of clinical judgement for operative deliveries (specially in adherent placenta) is well supported by informed consent. Sometimes mother's health is given priority over fetal life as in cases of eclampsia, ante-partum hemorrhage etc. and preterm inductions/deliveries are done to save mother's life. In-vitro fertilization has complicated the present day obstetrics, with multiple gestation, anxiety, financial concerns and higher rate of operative deliveries. Informed consent has significance in planning and management of such cases. Regular antenatal visits, diet and drugs should

be well documented in OPD records. Antepartum fetal surveillance and well being are now regular features in present Obstetrical management of fetal growth restrictions or previous poor obstetric outcomes.

Assessment of patient understanding regarding procedure informed consenting, can be done if patient is able to answer the following reasonably¹⁸.

- What are the indications that have led your doctor to the opinion that an operation is necessary?
- What, if any, alternative treatments are available for your condition?
- What will be the likely result if you don't have the operation?
- What are the basic procedures involved in the operation?
- What are the risks?
- How is the operation expected to improve your health or quality of life?
- Is hospitalization necessary and, if so, how long can you expect to be hospitalized?
- What can you expect during your recovery period?
- When can you expect to resume normal activities?
- Are there likely to be residual effects from the operation?

Doctor who is counselling consent should have following qualities (of empathy)

- Good listening & communication
- Problem solving skills
- Ability to have non-judgemental approach
- Confidentiality and professional boundaries
- Approachable

No doctor can sit in comfort with the belief that the "consent" can certainly avoid legal liability. This is highlighted by the note of The California Supreme Court,

"One cannot know with certainty whether a consent is valid until a lawsuit has been filed and resolved."

One can only take adequate precaution and act with care and diligence.

References

1. Pace E, Gebhard PG. Developer of the Term 'Informed Consent' - New York Times. New York: NY; 1997. Aug 26. Accessed at <https://www.nytimes.com/1997/08/26/us/p-g-gebhard-69-developer-of-the-term-informed-consent.html>
2. Faden, Ruth R.; Beauchamp, Tom L.; King, Nancy M.P. A

history and theory of informed consent (Online ed.). New York: Oxford University Press, 1986

3. Riddick FA. The Code of Medical Ethics of the American Medical Association. *Ochsner J.* 2003; 5(2): 6-10
4. American Medical Association. Principles of Medical Ethics. 2000 In: Council on Ethical and Judicial Affairs. Code of Medical Ethics -Current Opinions, 2000-2001 Edition, xiv. Chicago: American Medical Association
5. Annas, George J., and Michael A. Grodin. The Nazi Doctors and the Nuremberg Code. New York, NY: Oxford University Press Inc., 1992
6. Weindling, Paul. "The origins of informed consent: The international scientific commission on medical war crimes, and the Nuremberg code." *Bulletin of the History of Medicine.* 2001; 75.1: 37-71.
7. Lederer SE. Research without borders: the origins of the Declaration of Helsinki. In: Schmidt U, Frewer A, eds. History and theory of human experimentation: the Declaration of Helsinki and modern medical ethics. Stuttgart: Franz Steiner Verlag, 2007; 155-6
8. Faden, R. R.; Beauchamp, T. L. A History and Theory of Informed Consent. New York: Oxford University Press, 1986.
9. Beauchamp, Tom L.; Childress, James F. Principles of Biomedical Ethics (Fourth ed.). New York: Oxford University Press, 1994
10. Miles SH. The Hippocratic Oath and the Ethics of Medicine. New York: Oxford University Press; 2004. Available from: <https://bioethics.georgetown.edu/2015/07/physicians-the-morality-of-euthanasia-and-the-hippocratic-oath/>
11. Bernard A. Fischer IV. A Summary of Important Documents in the Field of Research Ethics. *Schizophrenia Bulletin*, 2006; 32 (1): 69-80.
12. Braddock CH, Edwards KA, Hasenberg NM, Laidley TL, Levinson W. Informed decision making in outpatient practice: time to get back to basics. *JAMA*, 1999; 282(24): 2313-20.
13. MM. Bottrell, H Alpert, RL. Fischbach, LL. Emanuel. Hospital Informed Consent for Procedure Forms - Facilitating Quality Patient-Physician Interaction. *Arch Surg.* 2000; 135(1): 26-33
14. Informed consent. ACOG Committee Opinion No. 439. American College of Obstetricians and Gynecologists. *Obstet Gynecol* 2009; 114: 401 - 8
15. RCOG. Obtaining Valid Consent - Clinical Governance Advice No. 6. January 2006. Available at: <https://www.rcog.org.uk/globalassets/documents/guidelines/clinical-governance-advice/cga6.pdf>
16. Digiovanni LM. Ethical issues in obstetrics. *Obstet Gynecol Clin North Am.* 2010 Jun; 37(2): 345 - 57
17. Anita Bhaktwani. The PC-PNDT act in a nutshell. *Indian J Radiol Imaging.* 2012 Apr-Jun; 22(2): 133-134.
18. K H Satyanarayana Rao. Informed Consent: An Ethical Obligation or Legal Compulsion? *J Cutan Aesthet Surg.* 2008 Jan; 1(1): 33-35

Ethics of In-Utero Prenatal Diagnosis and Therapy

Dipika Deka

Professor, Obst & Gynae, Unit Head, Chief-Fetal Medicine Division, AIIMS, New-Delhi



Dr Dipika Deka

Introduction

Innovative medical technology in Prenatal Screening, Diagnosis and Therapy of Genetic and Congenital disorders have raised unprecedented ethical, legal and social dilemmas^{1,2}. Many decisions which were once outside our control are now becoming matters of choice. They pose critical moral, legal, and ethical dilemmas involving the family, the physician, society, and the fetus. Bioethics in Prenatal Diagnosis and Therapy is mostly related to informed decision making, at every step.

Questions also arise involving family history taking, carrier detection, and the rights of the patient, the fetus, the physician, and the society.

Ethical issues involved in prenatal diagnosis and treatment are very similar to all types of diagnostic procedures, but are complicated by controversy about the use of selective abortion as a form of treatment. It is seen as justified if the fetus is afflicted with a condition that is incompatible with postnatal survival or there is virtual absence of cognitive functioning; however, for a fetus afflicted with a non-life-threatening physical or mental disability (e.g., Down's syndrome) it is more controversial.

An additional concern is that women with positive screening test results may choose elective termination of pregnancy rather than undergo a definitive work-up.

In fetal therapy; the issue of maternal versus fetal rights is perhaps the single most controversial dilemma - conflict between respecting maternal autonomy versus benefit of the fetus. Generally, the more invasive the procedure (e.g., laparotomy) and the less certain the benefit to the fetus, the more difficult the ethical decision for interventions involving the mother's body and perhaps future child-bearing. It also raises complex ethical issues of the use of proxy decision making for the fetus - the future 'human being', which is ordinarily assigned to the parents.

A final ethical issue is in the development of clinical services and the formulation of public policy regarding access and funding. Public and professional education on human genetics, research on the best delivery mechanisms for current technologies, and the clarification and coordination of the roles of parents and family, the health care providers, voluntary organizations, and government agencies is needed.

GENETIC SCREENING is branded as a marvel about to save the human race from the scourge of genetic

disease. Of the three different types, controversial ethical issues surround the second mostly:

1. Newborn screening at birth - identifies disease and permits prompt treatment to prevent mental and physical retardation
2. Fetal screening and prenatal diagnosis by Ultrasound, Amniocentesis or Chorionic Villus sampling - identifies abnormalities in the fetus permitting continuation of the pregnancy, selective termination of pregnancy or fetal therapy
3. Carrier screening- identifies individuals and families at risk for affected offspring.

Prenatal / Fetal Screening - A menace ? Expectations of routine ultrasound

Many may consider 'Screening' as a menace about to invade privacy and determine reproduction¹. Rejection of prenatal diagnosis on ethical grounds is widespread- the moral reasoning and decision-making process that couples go through regarding not to have fetal testing and to continue the pregnancy mostly appears to be based on family and personal ties, bonding to the fetus after perception of fetal movement - combined with considerations such as duties and rights, and consideration of the anticipated consequences as well. Positive experiences achieved in countries like Denmark serves to show that highly beneficial results can be obtained by humanizing the school system. This holds true not only for the severely retarded and their families, but also for children with minor learning disabilities as well. Women vary in their expectations of routine ultrasound and experiences; as when 'soft markers' are discovered: what the disclosure meant, how it affected them, how they experienced the information given and why they did or did not choose amniocentesis. Women often are shocked by the unexpected and sometimes unwanted information on elevated risk for a chromosomal aberration for which they lacked any preparation.

Because this event often has long-lasting effects on the pregnancy, models of information that are efficient in promoting informed decisions are imperative. In UK, the policy change is to offer screening for fetal anomalies, particularly Down's syndrome, as a routine part of antenatal care, to all pregnant women. Pregnant women should be counselled, to take an informed stand on such ethical issues. They have to be encouraged to also think carefully about their own moral beliefs and values prior to screening, and act as 'moral pioneers' in increasingly complex settings.

Prenatal Diagnostic Techniques (PND)

Consent - to undergo amniocentesis or CVS, or to raise a mentally retarded child ? Procedure related risk:

Routine use of prenatal diagnostic technologies (PDTs) such as amniocentesis, chorion villus sampling, have very real legal and ethical implications now, as it is a matter of current practice. The principle of consent has been there since the Egyptian, Greek and Roman civilizations. The essential aim of PND procedures is to assure parents that their offspring will be normal.

Both women and their partners need relevant information before and in connection with prenatal diagnostic procedures, to be able to make informed choices. The procedure related risk versus risk of the condition - whether autosomal recessive or dominant, etc. should be discussed with both parents prior to the procedure. Studies have shown socioeconomic disparities in the use of prenatal diagnosis in several countries, in addition to the country's abortion politics, feminism, disability activism, and religion.

Termination of pregnancy: For those families faced with the diagnosis of fetal disability, a decision may be made to continue or terminate the pregnancy³. Governments have decided lawfully, that detection of genetic abnormality in the fetus is a beneficial development because it enables parents to have the option of terminating the pregnancy, valid in India (MTP Act, 1971), the United Kingdom, the United States and most countries. The liberalization of abortion provisions express the criteria for therapeutic abortion - the risk of physical or mental abnormalities that the child, if born, would be likely to suffer from such as to be seriously handicapped. Late-term abortions is a legislative problem

Families should discuss the possibilities of lightening the burden on the fetus / child itself and on the relatives of children with Down's syndrome and mental retardation, and severe physical disabilities.

Whether a handicapped life is a life not worth living? This is another ethical debate. At the societal level, pressures to conform and minimize human differences and to normalize disabilities are apparent in biomedical interventions, advertising and media images. Parental idea of 'handicap' due to the particular birth defect depends on their perceptions of the impairment and on their expectation of the emotional, social and financial burden involved for the family and the child.

Selective abortion rejecting the disability, and not the fetus - is slowly becoming the "new moral order". The selective termination of fetuses with serious disabilities is not seen to represent fetal discrimination. More significantly, the choice to abort a fetus with a serious illness or disability is an intensely private and personal exercise that does not and cannot be reflective of a wider public morality.

Ethical issues & Legal concerns for the Obstetrician / Geneticist,: Among the factors influencing parents' decision-making, the attitude of the health-care professional giving the post-diagnosis counseling seems to be the most important, next to the socio-economic and educational status of the parents. With PND, there prevails a sense of uncertainty - with five main stages identified: (1) ambivalence toward pregnancy; (2) decision to undergo amniocentesis; (3) concerns regarding maternal and foetal safety during procedure; (4) anxiety while awaiting results and (5) thoughts about a lifetime maternal commitment. These emerging themes should be appreciated to enable physicians and nurses to address women's concerns in a meaningful way as they undergo amniocentesis. Understanding these ethical issues will facilitate constructive interactions between women, physicians and other members of the obstetric team.

The physician needs legal clarification of the right to contact blood relations of a patient with a genetic condition. The question arises of who has the responsibility to make an infant aware of being a carrier of a serious disease. Failure of the Obstetrician/ Geneticist to inform a woman that she is at risk for having defective children could expose her/him to legal liability, and also be in legal jeopardy if we fail to recommend diagnostic tests to a patient.

Courts generally hold the physician responsible for informing a patient so that she may give informed consent.

Cost-effectiveness: In the USA, compared with no diagnostic testing, amniocentesis costs less than US\$15000 dollars per quality-adjusted life year gained for women of all ages and risk levels. The cost-utility ratio for any individual woman depends on her preferences for reassurance about the chromosomal status of her fetus, and, to a lesser extent, for miscarriage.

Prenatal diagnostic testing can be cost effective at any age or risk level, and favour offering testing to all pregnant women, not just those whose risk of carrying an affected fetus exceeds a specified threshold.

Ethics of Amniocentesis and risk of mother-to-child transmission of human immunodeficiency virus

Amniocentesis could increase mother-to-child transmission of human immunodeficiency virus (HIV)-1 (MTCT) among mothers who received no antiretroviral agents, mothers receiving zidovudine monotherapy or a double-nucleoside reverse transcriptase inhibitor combination. Among mothers receiving HAART, there was no case of MTCT⁶, hence advised.

Genetic Counseling, Counsellors, 'options': The decision-making process requires a more detailed investigation into psychosocial, political and historical factors in the local health-care setting^{4,5}.

Models of practice as well as the training of genetic

counsellors need to be sensitive to these influences. They need to be careful about the term “option”, as there exists societal pressures in favor of new trends - a pregnant woman who is over 35 and does not want prenatal diagnosis; or a woman carrying a Down's syndrome child identified by prenatal diagnosis but does not want an abortion.

Non-invasive prenatal diagnosis

PND from maternal blood is about to have a massive impact on the way fetal medicine is practiced, with great advantages and improvements; but also has the potential to be used for sex selection and paternity testing⁷. It is still a screening test, yet to be routinely applied.

Pre-Implantation Genetic Diagnosis: The ethical solution ?

PGD is a new diagnostic technology for identifying chromosomal or single gene defects, which offers the possibility for diagnosis before pregnancy. IVF is a barrier for PGD, but destruction of affected pre-embryos is marginally more acceptable than selective abortion⁸.

Ethics of Fetal Surgery

Fetal surgery is rare, the medical intervention is always invasive, often experimental, and the success rate is difficult to measure. Fetal surgery impacts the quality of life of both pregnant women and fetuses. What may benefit the fetus may harm the pregnant woman - preterm premature rupture of the membranes, preterm labor, wound infection, hemorrhage, injury to the uterus, and even mortality.

The operative technique is an ‘option’ - open hysterotomy is characterized by a surgical incision on the uterus, the maternal abdominal wall, and the amnion. The next type of fetal surgery involves ‘fetoscopy incision’ - which is much smaller and less traumatic to the pregnant woman's uterine and abdominal walls; and some treatments may be done by the safer percutaneous route.

Technological advances in neonatal intensive care units to treat premature births helped to advance the field of fetal surgery.

Ethical criteria for safety of fetal therapy, especially for fetal surgery:

The most obvious ethical concern is the balance between potential benefit and harm for the fetus as well as for its mother^{9,10}. The concept is that of the ‘fetus as a patient’, independent of the pregnant woman, even though the moral status of the fetus is in dispute.

There should be a very high probability of being life-saving or preventing serious or irreversible disease, injury, or handicap to the fetus or the child to be. Also, there should be low mortality and low or manageable

risk of serious disease, injury, or handicap to the fetus or born child. More importantly, the mortality risk to the mother should be negligible or very low, and the risk of disease or injury or handicap to the mother should also be low and definitely has to be manageable.

The pregnant woman must consent to an intervention that involves the fetus, and has the right to decide not to pursue the intervention. For therapies of unproven benefit, the absence of evidence must be disclosed, and therapy should only be undertaken within well designed and approved trials and only by experts in the treatment modality.

Prenatal Counseling for fetal surgery:

This should include the nature of the defect, the prognosis for fetal survival, any potential long-term disability and possible treatments, whether medical or surgical, and their risks along with a discussion of the consequences of no treatment. Counselling should be sensitive to the mother's religious and cultural beliefs, especially those related to dying and death. Fetuses that die due to fetal surgery may cause her more grief than would death resulting from the congenital anomaly in question.

Other ethical considerations are financial and emotional cost of the initial and follow-up procedures of fetus / neonate/ child.

Fetal Therapy Team:

Following diagnosis of a potentially treatable condition, the patient is to be referred to a center with sufficient expertise in diagnosis and all therapeutic options. Consultation with the neonatologist / pediatric surgeon, neurologist, and urologist, depending on the particular malformation, should be available. An important ethical aspect of fetal surgery is that these highly specialized procedures should be offered only by teams, and individuals that are familiar with and experienced in management of the pathology involved and the execution of these procedures. Specialized surgical and medical teams involved in such high risk procedures are in only a few centers world wide. Fetal surgeries often fall under the category of clinical trials, and as such are subject to approval of the Institutional Review Board (IRB) where the fetal surgery is taking place¹¹. For a number of fetal interventions learning curves have been described - proficiency in laser surgery for twin-to-twin transfusion syndrome, prenatal imaging skill in selection of cases for fetal surgery. Given the numbers required and the rarity of cases implicated a certain centralisation is necessary to obtain optimal results¹².

Fetal pain relief during procedures

There is evidence that the mid-gestational fetus can respond to potentially noxious stimuli by mounting a distinct stress response. Consequently, means to manage fetal pain / stress response in utero during invasive fetal interventions have been explored. Policy of efficient pain relief during fetal procedures and

around the time of fetocide from 18-20 weeks onwards have included Sufentanil 1-2 µg/kg or fentanyl 10 µg/kg given intramuscularly or intravenously to the fetus. In the less common scenario in which the mother undergoes general anesthesia, the fetus should be sufficiently anesthetized through transplacental passage¹³.

Palliative Care

If the decision against active fetal or neonatal therapy is made, then offering palliative care is the ethical thing to do¹³ - a “prenatal advance directive” akin to the one advocated for adults.

Specific issues need to be discussed in these cases; the place of delivery - community hospital or a tertiary care hospital; mode of delivery - a vaginal delivery may be the best option, many babies who have severe pulmonary hypoplasia or severe malformations will breathe for a couple of minutes and then die. We also know that many of these babies will die in the process of natural labor. Some mothers may opt for Cesarean section just to be able to hold their living baby, even for few minutes.

The timing of delivery: earlier delivery may decrease the risk of maternal complications. Some women want to be delivered sooner, while others may want to be delivered later.

Autopsy is very important because in 10-14% of these cases a new diagnosis that was missed prenatally will be discovered. It will help establish the precise cause of death and thus will alleviate any guilt feelings by reassuring the parents of the inevitability of the death.

Plans for future pregnancy and any preventive measures should be discussed. For example, if the baby had a neural tube defect, supplemental folic acid before a next planned pregnancy significantly reduces the risk of recurrence.

References

1. Rowley PT. Genetic screening: marvel or menace? *Patient Educ Couns.* 2010 ;81(1):87-93.
2. Ahman A. What's right? Medical progress muddles the ethics of life and death. *Lancet.* 2004. 24;363(9405): 276-82.
3. Ballantyne A, Newson A, Luna F, Ashcroft R. Prenatal diagnosis and abortion for congenital abnormalities: is it ethical to provide one without the other? *Am J Bioeth.* 2009; 9(8):48-56.
4. Itlis AS. Prenatal screening and prenatal diagnosis: contemporary practices in light of the past. *J Med Ethics.* 2016; 42(6):334-9.
5. Wessels TM. 'And then you can decide'--antenatal foetal diagnosis decision making in South Africa. *Health Expect.* 2015;18(6):3313-24.
6. de Decker HP Mother-to-fetus HIV transmission during amniocentesis--ethical concerns. *Hiv -S Afr Med J.* 2002; 92(2): 124-5.
7. Smith RP, Lombaard H, Soothill PW. The obstetrician's view: ethical and societal implications of non-invasive prenatal diagnosis. *Prenat Diagn.* 2006;26(7):631-4.
8. Vergeer MM, van Balen F, Ketting E. Preimplantation genetic diagnosis as an alternative to amniocentesis and chorionic villus sampling: psychosocial and ethical aspects. *Patient Educ Couns.* 1998;35(1):5-13.
9. Chervenak, Frank A., and Laurence B. McCullough. "Ethics of Fetal Surgery," *Clinics in Perinatology* 36 (2009): 237-46.
10. J. Deprest, J. Toelen, Z. Debyser. The fetal patient - ethical aspects of fetal therapy. *Facts Views Vis Obgyn.* 2011; 3(3): 221-227.
11. Ville Y. Recent developments in fetal surgery. Technical, organizational and ethical considerations. *Bull Acad Natl Med.* 2008;192(8):1611-21
12. Wilson RD, Lemerand K, Johnson MP, et al. Reproductive outcomes in subsequent pregnancies after a pregnancy complicated by open maternal-fetal surgery (1996-2007) *Am J Obstet Gynecol.* 2010;203:209.
13. Hossam E. Fadel, Ethical Aspects of Prenatal Diagnosis of Fetal Malformations. *J IMA.* 2011; 43(3): 182-188.

CONTROVERSY

Hysterectomy in A Mentally Challenged Girl

Sunita Malik, Mukta Rawat

Senior Resident, Vardhman Mahavir Medical College & Safdurjung Hospital, New Delhi



Dr Sunita Malik

Mental retardation is characterized by significantly sub-average intellectual functioning (an IQ of approximately 70 or below) with onset before age 18 years and concurrent deficit or impairment in adaptive functioning in at least two of the following skill areas: Communication, self-care, home living, social/interpersonal skills, use of community resources, self-direction, functional academic skills, work, leisure, health, and safety.⁽¹⁾

As per Census 2011, the disabled account for 2.21% of India's population, or 26.8 million people. Of these, 11.8 million are women.

India is a signatory to the United Nations Convention on the 'Rights of Persons with Disabilities 2007', which guarantees all intellectually disabled women "the right to full bodily integrity". But it is a common practice to conduct hysterectomies or sterilisations on mentally challenged girls, both by parents and by state agencies in government-run homes or shelters. Is it a humanitarian act to remove the uterus of a mentally deficient woman who is incapable of maintaining menstrual hygiene? Or is it a callous exercise in abdicating the social responsibility of caring for her?

The practice of forced hysterectomies became public in 1994, when they were found being conducted on mentally challenged women between the ages of 18 and 35 at Sassoon General Hospital, Pune. A 1994 article in the British Medical Journal said "...health authorities claim consent was given by the women's parents or other lawful guardians and that the operations were done to maintain the women's hygiene during menstruation..." The same reason was cited in 2008 by the Maharashtra government seeking to conduct hysterectomies on 300-odd women in five government homes.

Scenarios Worldwide: The laws have been passed for sterilisation in various countries but there is still ambiguity regarding hysterectomy.

Japan

A 'eugenic' law permitted involuntary sterilization of people with intellectual disability from 1948-1996.⁽²⁾

India

The Indian Journal of Medical Ethics⁽¹⁹⁹⁴⁾ guidelines address the issue of sterilization for this vulnerable group, emphasizing the need to adopt the least injurious option for the woman, regardless of interested parties⁽³⁾

United States of America

United States was the first country to undertake sterilization for eugenic purposes. In the early 1900s, American Eugenists argued that forced sterilization of people with intellectual disability was the best way to protect society.

The American College of Obstetrics and Gynaecologists recommended in 2007 that when a patient's mental capacity was limited and sterilization considered, the physician must consult with the patient's family, agents, and other caregivers in an effort to adopt a plan that protects what the consulted group believes to be the patient's best interests while preserving autonomy. The focus has now moved to more appropriate gynaecological care for women with intellectual disability.

Hysterectomy was seen as a reasonable means of fertility control because of the benefits in terms of personal hygiene, emotional outburst, behaviour problems, and seizure activity in people with intellectual disability and epilepsy.

American College of Obstetrics and Gynaecology guidelines state that indication for hysterectomy and endometrial ablation in women with intellectual disability are the same as those of the general population, and physicians are urged to be aware of pressure from family members whose interests may not be the same as the patient's.

Guidelines on Hysterectomy in Mentally Handicapped Women⁽³⁾

1. *Diagnosis of type and extent of mental handicap*

1. The woman concerned must be examined on more than one occasion by a panel of at least one qualified psychiatrist, one clinical psychologist and a social worker with experience in the problems faced by the mentally handicapped. If the woman is in an institution, members of the panel should include only those not on its payroll. Their findings, results of tests carried out and considered opinions on type, cause and extent of mental handicap must be recorded on the woman's case sheets.
2. A particular reference should be made to this panel when hysterectomy or any other medical or surgical procedure carrying inherent risks is being considered. The opinion of the panel on whether such a procedure is justified should be recorded on the case sheets.
3. Hysterectomy can only be considered in a woman with irreversible brain damage that has left her with no understanding of her bodily functions and incapable of looking after her own needs despite conscientious efforts at training her to do so. Such persons fall under the category of profound mental retardation (KS-10 classification F73).

II. Rationale for hysterectomy

1. Inability to maintain personal hygiene during menstruation
 - a. This must be documented on the case sheets. The effects of such documented lack of hygiene on the mentally handicapped woman must be clearly stated. Reference must be made in writing to the state of personal hygiene on other days when she is not menstruating, especially with regard to excretion of urine and faeces. It must be evident to an objective observer scrutinising the case sheets and inspecting the woman's surroundings that despite all available care and assistance, there is breach of hygiene from menstruation hazardous to the woman's health and well-being.
 - b. Where available care and assistance are less than what can be reasonably expected, the shortcomings must be corrected before a decision is made on hazard to the woman from breach of hygiene.
 - c. Hysterectomy in the absence of a conscientious effort at helping the woman to maintain personal hygiene cannot be justified.
2. To prevent unwanted pregnancy

Hysterectomy is not justified solely to prevent unwanted pregnancy. Laparoscopic tubal ligation is the procedure of choice for this purpose.
3. For medical indications such as menorrhagia (profuse bleeding resulting in severe anaemia), uterine tumours and endometriosis

The decision by a qualified gynaecologist to perform hysterectomy as therapy for such indications documented on the patient's case sheets cannot be challenged.
4. To avoid the consequences of rape

This is an untenable reason for hysterectomy. Prevention of rape is the responsibility of the legal guardian of the mentally handicapped woman. When such a woman is in a state institution, the onus for preventing such assault lies squarely on the administrators of the institution. The very nature of the handicap necessitates special protection

III. Competent authority to permit this operation

1. The principle of informed consent by the person to be subjected to surgery cannot be enforced here on account of the mental handicap faced by the woman.
2. Where the parents or other relatives who are the legal guardians are alive and able to decide on behalf of the woman, the informed consent of such guardians must be obtained in writing after explaining, in the language used by them, the need for the operation and the likely complications that could follow it. The consent must be witnessed by an unrelated individual who does not stand to benefit in any way from the operation. It must be ensured that there has been no coercion by the administrators of the institution. The relatives of

such women are especially vulnerable to threats and subtler forms of 'persuasion'.

Where the woman is an orphan, the officer in charge of the institution in which she is housed should permit the operation after getting the need for it endorsed by the panel recommended above.

Other Therapeutic Options

If reduction or abolition of menstruation is the goal, therapeutic options may be medical or surgical. Medical interventions include depot medroxy-progesterone acetate (DMPA, Depo-Provera) injections, continuous combined oral contraceptives, gonadotrophin releasing hormone (GnRH) analogues and oral progestins. Surgical options include implantation of a levonorgestrel-releasing intrauterine system (Mirena), endometrial ablation and, rarely, hysterectomy (Table 1)^(6,7,8,9,10)

Table 1.

| METHODS | PROS | CONS |
|--------------------------------|---|--|
| DMPA injections ⁽⁴⁾ | Simple, effective Contraceptive effect Once every 12 weeks | Injections BMD concern Weight gain Breakthrough bleeding |
| Oral progestogen | Oral route Contraceptive effect | BMD concern Break-through bleeding Weight gain |
| Trans-dermal patch | Reduced sign and symptoms of menstruation Contraceptive benefit (used when unable to swallow, mal-absorption syndrome, to bypass hepatic metabolism) | Skin irritation Allergic reaction Headache Remembering to remove and replace |
| COC pill | Oral route Contraceptive effect | Periods reduced, not eliminated thrombo-embolism Concerns about increased breast and cervical cancer risk Regular intake High compliance |
| GnRH analogues | Highly effective Contraceptive effect Option of add back estrogens or tibolone therapy. Once every 12 weeks | Injection BMD concerns Expensive Menopausal symptoms Sterile abscess |
| LNG- IUS | No systemic drugs Contraceptive effect Insertion every 5 years | Invasive Periods reduced, often eliminated, device expulsion, infection |
| Endometrial ablation | Less invasive than hysterectomy | Invasion Ethical and legal concern Poor efficacy, may need |
| Hysterectomy | Definitive treatment | requires general anaesthesia, ethical consideration, definitive sterility |

Choice of Therapy

The choice of therapy can only be made in partnership with the young woman's carers and the woman herself. If, after explanation and reassurance, therapy is deemed necessary, a full and frank discussion outlining the advantages and disadvantages of the treatment options is mandated. An assessment of BMD status

should be made to inform choice and other factors such as acceptability of injections or oral medications, anticonvulsant use, thrombo-embolic risk factors, family history of malignancy, patient weight, need for contraception and so on.

If the absolute eradication of menses is not necessary and one period every 3 months is acceptable, then the extended use of a COC may be the simplest first choice. If this is not acceptable and baseline BMD is satisfactory, then injectable DMPA or oral norethisterone would be an acceptable alternative, with reassessment of BMD status at 1-2 yearly intervals. When BMD is compromised, then the need for ongoing therapy should be reviewed, and, if still required, a COC or GnRH agonist with tibolone add-back therapy could be considered. The intermittent discontinuation of therapy for "treatment holidays" could also be considered.

Surgical options should be considered a last resort when symptoms are severe and other treatment modalities have been tried and failed.

Hysterectomy is major surgery with mortality rate of 1-2 per 1000. Three to five percent of all women undergoing hysterectomy may need a second operation or removal of their ovaries. Part of blood supply to ovaries is through uterine artery. As this supply is compromised by hysterectomy, ovarian function may be impaired. This results in the residual ovary syndrome.

Even if ovaries are left in, their function often recedes after hysterectomy, lowering the level of estrogen in the body. This may lead to cardiovascular disease and osteoporosis. Subjecting young girls to the operation therefore has severe and long term consequences.

The American College of Obstetricians and Gynaecologists states that "sterilization should not be denied to individuals simply because they also may be vulnerable to coercion" (Int J Gynaecol Obstet 1999; 65:317)

Ethical Consideration

The mental capacity act 2005 (MCA)⁽⁵⁾ states that incompetent adult should be treated in the way that serves their best interest. Under this act, doctors have a legal duty to consult a range of people when determining the best interest of a person who lacks capacity. This act does not cover children under 16 years old.

Children are not always capable of participating even minimally in respect of their own treatment and therefore the involvement of parents is crucial and consistent with the MCA.

When considering consent to treatment involving children, the Children Act, the Family Law Reform Act and the Gillick/Fraser guidelines, bring about two points which are relevant here. First, that the requirement for interventions should be the least restrictive of basic rights and freedom, and second, that those with parental responsibility have the legal right to give consent on behalf of minors for medical treatment.

The interests of the child must remain paramount, which can be difficult to achieve when the parent or carer have their own agenda. For example, parents can ask

for cessation of menstruation because of the effect on their own quality of life when it may have no impact on the quality of life of the child. In the UK, surgical options must only be considered as a last resort when symptoms and signs of menstruation are severe and medical management have failed and not for the benefit of the caregiver. Under UK law, approval from a high court judge is necessary before surgery can be carried out.⁶

Conclusion

Although sterilization is no longer used for eugenic purposes, hysterectomies continue to be performed for menstrual management in several countries. This practice is not confined to developing countries but also in countries such as Australia and USA.

Women with intellectual disability can use the contraceptive pill, medroxy-progesterone injections, and progesterone only intra uterine devices for contraception and menstrual management. Together with behavioural management, these methods could help with menstrual hygiene. They should also have access to less invasive procedures, such as endometrial ablation, before hysterectomy is considered and be supported in decision making with information presented in the most accessible format. If they lack capacity then any treatment should be carried out only in their best interests after having consulted everyone who works with them.

References

1. Management of Menstrual Problems and Contraception in Adolescents with Mental Retardation: A Medical, Legal, and Ethical Review with New Suggested Guidelines. Ora I, Robert K. Zurawin. J Pediatr Adolesc Gynecol (2003) 16: 223-235.
2. Tsuchiya T Eugenic Sterilizations in Japan and Recent Demands for Apology: A Report Newsletter of the Network on Ethics and Intellectual Disability 1997;3:1-4 [PubMed]
3. Suggested guidelines for hysterectomy in mentally handicapped women Indian Journal of Medical Ethics 1994; 2(4) [PubMed]
4. Sagsveen M, Farmer J E, Prentice A. *et al* Gonadotrophin-releasing hormone analogues for endometriosis: bone mineral density. Cochrane Database Syst Rev 2003(4)CD001297
5. Hope T, Savulescu J, Hendrick J. Medical Ethics and Law: The Core Curriculum. 2nd ed. Edinburg: churchill livingston: 2008
6. Management of menstrual problems in adolescents with learning and physical disabilities. E jeffery, S Kalyani, A Garden 2013;15 :106-12
7. Menstrual suppression in the adolescent. Kantartzis KL¹, Sucato GS. J Pediatr Adolesc Gynecol. 2013 Jun; 26(3): 132-7. doi: 10.1016/j.jpog.2012.08.007. Epub 2012 Nov 15.
8. The human rights of women with intellectual disability. Ashwin Roy, 1 Ameeta Roy, 2 and Meera Roy 3 J R Soc Med. 2012 Sep; 105(9): 384-38
9. Reproductive rights of mentally retarded persons Katalinić S¹, Sendula-Jengiđ V, Sendula-Paveliđ M, Psychiatr Danub. 2012 Mar; 24(1):38-43.
10. Menstrual issues for women with intellectual disability. J Tracy, S grover, S Macgibbon. Aust Prescr. 2016 Apr; 39(2): 54-57.
11. ACOG Committee Opinion. Number 371. July 2007. Sterilization of women, including those with mental disabilities. Obstet Gynecol. 2007 Jul; 110(1):217-20.

CASE APPROACH

Breaking Bad News In Sudden Intrauterine Death/Sudden Maternal Death



Dr Manisha Kumar

Manisha Kumar

Professor, Obstetrics & Gynecology, Lady Hardinge Medical College & SSK Hospital, New Delhi

Introduction

Bad news in the context of health care has been broadly defined as significant information that negatively alters people's perceptions of the present or future. Effectively delivering bad news in the setting of the emergency department requires excellent communication skills. Evidence shows that bad news is frequently given inadequately¹. Studies show that trainees need to devote more time in developing this skill through formalized training². Feelings of mistrust, anger, fear, and blame are common reactions if bad news is broken poorly. According to a study by Gold et al, nearly one in ten obstetricians reported they had considered giving up obstetric practice because of the emotional difficulty in caring for a woman with a stillbirth. Talking informally with colleagues (87%) or friends/family (56%) had been the most common strategies used by doctors to cope. Improved bereavement training can help staff care for grieving families but can also help staff cope with their own emotions.

Situations Commonly Encountered in which Breaking Bad News is Required are:

- Patient came to the hospital with poor general condition or with a high risk condition but deteriorated and in spite of all efforts could not be saved.
- Delivery of a macerated stillborn baby.
- Patient was perfectly fine recovering after delivery or operation but had sudden death.
- Intrapartum stillbirth leading to fresh stillborn baby

In the first two situations, the patient's relatives are aware of the serious nature of the illness, and naturally death is expected, but in last two situations, they can hardly believe the sudden loss and would be very sensitive and emotionally highly charged⁴. In this situation, any lack of compassion and kindness on the part of the health care team may trigger violent grief reaction, and anger may be directed towards the hospital staff.

Different models have been proposed for delivering bad news to the patients of terminal illness like cancer. These models are SPIKES protocol⁵, ABCDE model⁶, and BREAKS protocol⁷. In all these protocols the approach has been client-centered. Many previous studies have reported appropriate techniques in situations such as sudden maternal death or fetal death^{4,8,9}.

The Proposed Step Wise Action Plan

The onus of convincing the bereaved family members

about the circumstances which lead to sudden demise of the patient, lies on the health care team and should be carried out with utmost priority.

1. Give a forewarning of the ill-fated news

- When the patient becomes ill unexpectedly, all efforts of resuscitation are done behind closed doors. It is very important to brief the relatives about the efforts being taken to save the life of their relative. It prepares the relatives mentally for the inevitable news.
- If the family members are not present, they should be asked to come to the hospital immediately^{8,9}. If the patient is already dead, care should be taken not to break news on the telephone, but to call them and give news in person.
- One of the relative who is relatively confident and well-versed with the hospital set up should be given opportunity to witness the ongoing resuscitation in the ICU.
- The staff should keep the family informed with frequent updates on the progress of the resuscitation.

2. Approach- Who should convey? Where? To whom?

- The senior most treating person or the physician involved in the care should be delivering the news, the presence of co-workers is often helpful.
- The physical set up is very important in accomplishing this difficult task. The place should be calm and quiet. The mobile phone must be switched off. All physical barriers must be removed to maintain eye contact⁵.
- Announcement of the bad news must be in straightforward terms, avoiding the medical jargon completely. Information should be given in short, easily comprehensible sentences⁷.
- It is preferable to talk to only one or two members of the family. Friends and others should be asked to wait outside. Talking to the same person who has been briefed about the patient's critical illness earlier should be desirable¹⁰.
- It is always easier to converse and convince a familiar person than a stranger. Moreover, it will be lot easier to break the sad news to the person who is quite aware of the ongoing treatment and patient's problem rather than to a totally new person
- The appointment length should be sufficient to complete the task. A hostile attitude has disastrous outcome, so is a hurried manner.

3. What is to be said?

- Whenever attempting to break the bad news, it is easier for the physician to start from what the relative or parents know. Most of the relatives will be aware of the seriousness of the condition.
- The physician is then in a position of confirming bad news rather than breaking it. The history, the investigations, the difficulties met in the process need to be explored.
- Having announced the bad news, the doctor's next duty is to help the relatives to go through the process of grief. People listen to the news and may react differently. Emotional breakdown can be expected; hence, the physician may have to console the relatives as well.
- Adequate space for the free flow of emotions has to be given. Encourage them to talk about the patient's illness, and if they open up, try to explain the efforts taken to save him and the inevitable outcome
- Answers have to be tailored to the question, and physician should stay away from lecturing the attendants.
- Appreciating the efforts taken by the relatives to get the patient treated may help them to come out of a sense of guilt or self-blame. Convince them again that there has been no shortage of efforts either from the health care team or from the relatives
- In certain cases, especially when the diseased has been in deep coma, explain them how peaceful the death was. This would help to convince them that their beloved one did not suffer much. Such reassurances also reduce guilt feelings⁸
- Some amounts of religious philosophy like "ultimately everything depends on God's wish" or "Life-span being over as per God calculation" etc., may help to console the bereaved relatives, and again, this depends on ethnicity and religious background¹⁰

4. Reaction of the patient's relative may vary

- Grief reaction is unique, and it will differ from one individual to another. Expressions of sorrow may vary from silence to crying, loud shrieks, wailing, and bodily movements.
- The bereaved relatives perceive the sudden death as 'untimely' and 'unfair' and may show grief reactions ranging from initial shock reaction to denial- This is initial defense mechanism after unexpected, devastating news, and it should be recognised and tolerated.
- Acceptance may be possible by encouraging the relatives to view the body of the deceased, especially to those relatives who were not present at time of death.
- Anger- This is a common reaction after sudden death of a beloved relative. The expression of this anger can vary from mild irritation to violent

behaviour. This can be expressed on self, hospital staff or any other person. Anger will gradually diminish once expressed.

- Guilt- This is nothing but the inward expression of anger and self-blame. Consoling words of the health care team will help to do away with this emotion
- Do not respond or argue with the relatives if they blame or comment on the healthcare team or the hospital They will realize their mistake and surely apologize when the emotions settles down
- Regressive behaviours need to be tackled with a calmness and patience¹⁰.

5. Convey your genuineness in finding the cause

- Give room for further inquiries and possible means to find the cause such as offering autopsy or collection of investigations that has been sent specially for possibility of recurrence in cases of stillbirth¹¹.
- Give information about the chances of not knowing the cause after getting all available investigations done.

6. Showing them the body

- Before allowing the relatives to view the body, make it more presentable. Cover the body with proper bed clothes. Disconnect all the life supports like endotracheal tube, cardiac monitors, ventilators etc
- Wipe the face neatly to clean blood and other secretions. Clean the jelly on the chest used for the DC shock

7. Summarize the findings - provide written information for stillbirth

- Parents should be offered written information to supplement discussions, as they usually take in very little when they are anxious.
- Offering round the clock availability and encouraging the patient to call for any reason whatsoever is very helpful. ???
- In cases of stillbirth it is desirable to call the couple for counselling after a month, so that necessary investigations and information regarding management in next pregnancy can be provided.

8. Help the relatives to go through the official formalities

- One of the hospital staff should assist the relatives in completing the formalities like filling the details of deceased so as to get a legal death certificate etc.
- If an autopsy is needed, guide the relatives about various procedures
- And finally, ensure smooth and timely handing over the body of the deceased along with valuables and personal belongings.

Conclusion

Breaking bad news is part of the art of medicine. A bad news is always a bad news, however well it is said. But the manner in which it is conveyed can have a profound effect on both the recipient (the patient) and the giver (the physician). Unfortunately, there is little guidance on to the approach of this very sensitive matter. The doctors depend on their own experience rather than any training received in the medical college. A well-trained doctor in this field will be in a better position to handle the daunting task of breaking the bad news. It is high time to include this subject into the undergraduate medical curriculum. Irrespective of the final outcome, the health care team's commitment will be definitely appreciated by the family members. The act of kindness shown during the hour of need will surely help to strengthen the doctor-patient relationship further.

References

1. Cook P, White DK, Ross-Russell RI. Bereavement support following sudden and unexpected death: Guidelines for care. Arch Dis Child. 2002;87: 36-8. [PMC free article] [PubMed]
2. Barnett MM, Fisher JD, Cooke H, James PR, Dale J. Breaking bad news: Consultants' experience, previous education and views on educational format and timing. Med Educ. 2007; 41:947-56. [PubMed]
3. Gold KJ, Kuznia AL, Hayward RA. How physicians cope with stillbirth or neonatal death: a national survey of obstetricians. Obstet Gynecol. 2008 Jul;112(1):29-34.
4. Williams AG, O'Brien DL, Laughton KJ, Jelinek GA. Improving services to bereaved relatives in the emergency department: Making healthcare more human. Med J Aust. 2000;173:480-3. [PubMed]
5. Seifart C, Hofmann M, Bär T, Riera Knorrenschild J, Seifart U, Rief W. Breaking bad news-what patients want and what they get: evaluating the SPIKES protocol in Germany. Ann Oncol. 2014 Mar;25(3):707-11.
6. VandeKieft GK. Breaking bad news. Am Fam Physician. 2001; 64:1975-8. [PubMed]
7. Vijayakumar Narayanan, Bibek Bista,1 and Cheriyan Koshy2 'BREAKS' Protocol for Breaking Bad News. Indian J Palliat Care. 2010 May-Aug; 16(2): 61-65
8. VandeKieft GK. Breaking bad news. Am Fam Physician. 2001; 64:1975-8. [PubMed]
9. Kent H, McDowell J. Sudden bereavement in acute care settings. Nurs Stand. 2004;19:38-42. [PubMed]
10. Naik SB. Death in the hospital: Breaking the bad news to the bereaved family. Indian J Crit Care Med. 2013 May; 17(3): 178-81.
11. RCOG green top guideline no 55 Oct 2010. Late intrauterine fetal death and stillbirth

Calendar of Monthly Clinical Meetings 2018-19

| Months | Name of the Institute |
|-----------------|------------------------------|
| September, 2018 | Deen Dayal Upadhyay Hospital |
| October, 2018 | ESI Hospital |
| November, 2018 | MAMC & LN Hospital |
| December, 2018 | Sir Ganga Ram Hospital |
| January, 2019 | Dr RML Hospital |
| February, 2019 | UCMS & GTB Hospital |
| March, 2019 | LHMC |
| April, 2019 | Apollo Hospital |

DISTRESS TO DE-STRESS

A Beautiful Mind

Mohit D Gupta

Professor of Cardiology, GB Pant Institute of Postgraduate Medical Education and Research, New Delhi
Author is associated with Brahma Kumaris World Spiritual University



Dr Mohit D Gupta

*If at any point of your life: you feel lost, unable to achieve goals and success and have a feeling of giving up:
Go ahead and read it.*

*Mental toughness is a state of mind: One can call it
"Character in Action"*

In 1914, when Thomas Edison's factory burned to the ground, destroying one-of-a-kind prototypes and causing millions of damage, his response was simple:

"Thank goodness all our mistakes were burned up. Now we can start fresh again."

Challenges today are a part of life. They often disturb our inner peace and destroy calmness. The outcome depends on the quality of lens through which we view it. What is that lens: it is one of confidence, dedication, fearlessness and a hidden opportunity. These are the key if we want to move through it successfully. It sounds easy; but more often it is not. When we are stuck, responses and life are often different. The ability to break the mold and take a bold new direction requires that extra grit, daring and spunk that only the mentally tough people have. Such people set themselves apart from the crowd. When others see an impenetrable barrier, they see challenges to overcome.

The hallmark of mentally tough people are the strategies they apply, which can be used to develop stability and mental toughness to deal with people and situations.

1. Emotionally and spiritually intelligent: Moments of toughness are a test of mental stability. Emotionally stable people are able to understand negative emotions and tolerate them. They are able to transform these into positive and even do something productive with them.

Emotional stability naturally helps us to practice SOS strategy.

Stand back, Observe and Steer.

Only a quiet and stable mind is able to do this.

Practice: In a tough situation, I will allow my mind to observe the situation staying detached, inculcate a rationale thought and then take a conscious healthy decision.

2. Inculcate confidence: It is said that mind is like a parachute; it best functions when it is open. We are often faced with situations that can shake our confidence. Doubt and insecurity in such situations, creates uncertainty and hence failure. Stable minds

have the ability to overcome fear and create success. Negative direction of thoughts that I won't be able to do will lead us to failure and positive thoughts will lead us to success.

Practice: In every situation, I will fill my mind with positive, powerful thoughts: I can and I Will: Success is a natural consequence of positive and powerful thinking.

3. Neutralize toxic thoughts and people: Most of us find dealing with difficult people as exhausting and frustrating. A rationale approach is the key.
 - a. We must identify our emotions and don't allow anger or frustration to fuel the chaos.
 - b. We must consider the difficult person's standpoint and find common ground and solutions to problems.
 - c. We must always avoid confrontation and wait for suitable time to put our view point

Practice: I realise that my mind is the most powerful tool to clear and cleanse negative environment. I have the power to transform the atmosphere by power of my thoughts.

4. Embrace change: The definition of insanity is doing the same thing over and over again and expecting a different result. The only thing constant in this world is change. The fear of change is paralysing and a major threat to happiness and success. Flexibility in thoughts is the key to embracing change. Once we do it, we are able to recognize the good in it and capitalize on it.

Practice: People and situations may not be my way. But, I choose to be flexible in every situation of life, understanding that only a flexible mind can adapt and accept changes.

5. Ability to say no: Research conducted at the University of California in San Francisco showed that the more difficulty you have saying no, the more likely you are to experience stress, burnout and even depression. Mentally tough people know that saying no is healthy, and they have the self-esteem and foresight to make their no's clear. However, one must understand that saying no does not mean turning our mind to negative; but saying no to a new commitment honors their existing commitments and

gives them the opportunity to successfully fulfill them.

Practice: I train my mind to stay relaxed and do one task at a time. Overthinking and multitasking depletes my energy and creates fatigue.

6. Don't dwell on mistakes: Focus on a person, situation or past creates similar emotional state that affects our present. When we focus on problems, we create and prolong negative emotions and stress, which hinders performance. When we focus on positive, we create sense of wellbeing and produce positive emotions and improve performance. Mentally tough people distance themselves from their mistakes, but they do so without forgetting them. By keeping their mistakes at a safe distance, yet still handy enough to refer to, they are able to adapt and adjust for future success.

Practice: I will let go off all the mistakes and burden of the past and wash my mind and my soul and fill it with pure and positive energy.

Let us practise these small exercises and see what difference is created.

Wishing you a Happy and Peaceful Life!



Forthcoming Events

- Next Monthly Clinical Meeting of AOGD on 28th September, 2018, 4:00pm-5:00pm at Deen Dayal Upadhyay Hospital, New Delhi. Contact: Dr Shashi Lata Kabra 9718990168
- CME on “Endometriosis update” on 5th October, 2018, 2:00pm-4:00pm, at Moolchand Hospital, New Delhi. Registration free preceded by Lunch. Contact: Dr Ruchi Tondon 9971570792
- 40th Annual Conference of AOGD, on 24th - 25th November 2018 India Habitat Centre.
- Preconference Workshops
22nd November 2018: Fetal Surveillance, Colposcopy (live workshop), Hysteroscopy.
23rd November 2018: Operative Obstetrics, Ovulation induction and Follicular Tracking, Pelvic Reconstructive Surgery
- Regional GCH Asia Pacific International Hysteroscopy Congress IHC 2018 on 1st - 2nd December at Crown Plaza Gurgaon. Contact: Dr Rahul Manchanda 9810017651 & Dr Richa Sharma 7011484180
- Evidence Based Management of GDM & Menopause organized by the Multidisciplinary Committee AOGD with ICOG on 9th December, 2018, 10:00am - 5:00pm Contact: Dr A G Radhika 9818065527

CROSSWORD


The Maze of Knowledge

Swati Agrawal

Associate Professor, Department of Obs & Gynae, LHMC & SSK Hospital, New Delhi



Dr Swati Agrawal



Down

1. A centre dedicated to help victims of sexual assault and domestic violence
2. Most severe form of mullerian agenesis
4. Component of valid informed consent
6. Gold standard for definite diagnosis and classification of genito - urinary anomalies
7. First uterine transplant in India performed in this city
9. Acceptable therapeutic option for reduction/abolition of mens truation in mentally challenged girls

Across

3. Uterine trans plant is a therapeutic option for patients suffering from this condition
5. Surgical procedure for treatment of mullerian agenesis
8. Model proposed for delivering bad news to patients of terminal illness
10. Landmark code for the ethical treatment of human subjects

PICTORIAL QUIZ

A Picture is Worth a Thousand Words

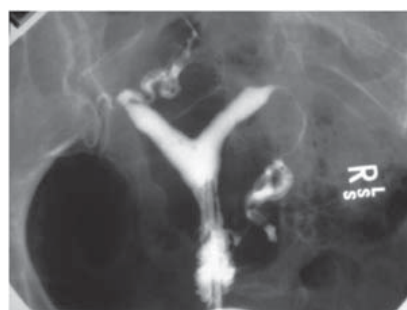

Figure 1:

Q1. What is the provisional diagnosis in this patient?

.....

Q2. What is the differential diagnosis?

.....

Q3. How will you confirm the diagnosis?

.....

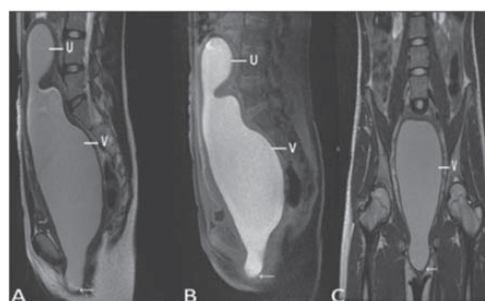


Figure 2:

Q1. What does the MRI show?

.....

Q2. How will the patient present?

.....

Q3. What is the treatment?

.....

Refer page 40 for Previous answer key.



40th Annual Conference of Association of Obstetricians and Gynecologists of Delhi

24th - 25th November 2018, India Habitat Center

Pre-conference Workshops: 22nd-23rd November, 2018

ABSTRACT SUBMISSION FORM

Presenting Author's Name:

Post Graduate Resident: Yes ☐ NO ☐

Qualifications: MD ☐ MS ☐ DGO ☐ DNB ☐ Fellowship ☐

AOGD Member: Yes ☐ No ☐ Registration no

Designation:

Institute Name:

Type of Presentation ☐ Oral ☐ Poster

Address:

Phone:

E-Mail:

Theme Topics for Abstract Submission (tick one)

- 1) Critically ill mother ☐ 2) Adolescent Gynecology ☐ 3) Gynecological cancers ☐
4) Endoscopy ☐ 5) Contraception ☐ 6) Miscellaneous ☐

ABSTRACT : (Copy & Paste abstract here as / per instructions below)

Note:

- 1) Only members of AOGD are entitled for paper & poster presentation (Proof of membership should be enclosed) 3) Abstract to be sent by email at aogdconference2018@gmail.com with the Pre-registration details for the conference.
2) Registration is Mandatory for Abstract Submission 4) Last Date for Abstract Submission 30th September 2018

Free Papers & Poster Submission

Theme Topics for Abstract Submission

- 1) Critically ill mother 2) Adolescent Gynecology 3) Gynecological cancers 4) Endoscopy 5) Contraception 6) Miscellaneous
Please send Abstract Submission Form to AOGD Secretariat at Department of Obstetrics and Gynecology

Lady Hardinge Medical College and Smt Sucheta Kriplani Hospital, New Delhi-110001

Last date for accepting free paper and poster abstract is 30th September, 2018.

Competition Papers

Candidates should be less than 30 years of age. Place of study should not be mentioned anywhere in the paper.

Three hard copies of the competition paper & a soft copy of the competition paper along with structured abstract should be sent to AOGD Secretariat at Department of Obstetrics and Gynecology

Lady Hardinge Medical College and Smt Sucheta Kriplani Hospital, New Delhi-110001

Last date for submission of competition paper is 30th September, 2018.

Notes: Papers/ Posters will not be considered without registration payment.

Instructions for Abstract Submission

Please follow these instructions carefully:

1. The abstract must be in English with not more than 250 words (excluding title, author and Institutional affiliations). It must be typed within the frame in the Abstract Form (using Times New Roman with font size 12). Please use MS Word 2007/2010 formats only. Text should be in black only.
2. Title must be in capital letters. It should be short and concise.
3. The name of authors should follow immediately under the title in one line. Type initials and family name of authors in BLOCK letters and underline the presenter's name. DO NOT include degrees or professional designations. The name of institution, city and country should be in lower case, following immediately after the authors, on a different line.
4. Leave one line between the title/ authors/ institution block and the body of the abstract.
5. Abstracts should be structured under following headings.
 - Objectives
 - Methods
 - Results
 - Conclusions
6. It is not desirable to simply state: like "The results will be discussed"
7. Use of standard abbreviations is desirable. Please write special or unusual abbreviation in brackets after the full word, the first time it appears. Use numerals to indicate numbers, except to begin sentences.
8. Do not include graphs and references in the abstract.
9. Use single-line vertical spacing and leave one line between paragraphs.
10. Hard Copy in triplicate of abstract along with copy of registration receipt should be send by the post at AOGD Secretariat at Department of Obstetrics and Gynecology Lady Hardinge Medical College and Smt Sucheta Kriplani Hospital, New Delhi-110001
11. Also e-mail your abstract to aogdcoference2018@gmail.com.
12. Oral Session: Please bring your presentations on e-mail and pendrive.
13. Poster presentations: Facility of E Poster display would be there.
14. Students must attach a student certificate forwarded by their Head of the Department.
15. One must be life/annual member to present oral/poster in the conference.

Note: Only registered delegates are entitled to present the selected posters/papers.

In e-mail correspondence, please mentions 'Abstract' in the subject line. Abstracts will be reviewed and rated by scientific committee prior to final decision on acceptance.

Decision for acceptance as oral presentation or poster presentation rests with the Scientific Committee.
16. For case report submission, the words "case report" should be included in the title.
17. DATES TO REMEMBER

Last Date of Submission 30th September 2018

Events Held

- CME held by “Breast and Cervical Cancer Awareness, Screening and Prevention” Subcommittee AOGD and Delhi Gynae Forum on 31st July, 2018 at Auditorium, Fortis Hospital, Shalimar Bagh



- DGES-ESGE 2018, Delhi Gynaecological Endoscopists Society Annual Conference under the aegis of AOGD on 16th - 17th August, 2018



- CME on “Vaginal Birth After Cesarean Section (VBAC)- Thrashing out the controversies” organized by Dept of Obs & Gynae, Sitaram Bharatiya Institute of Science and Research on 24th August, 2018



- “Cancer Awareness and Prevention” Program organized by the Dept of OB/Gyn, DDU Hospital under the aegis of Breast and Cervical Cancer Awareness and Prevention Committee of AOGD on 27th August, 2018



- Health Camp on “Geriatric Health” on occasion of World Senior Citizen Day organized by Dept of Obs & Gynae Lady Hardinge Medical College & Smt. Sucheta Kriplani Hospital under the aegis of AOGD on 28th August, 2018





40th Annual Conference

Date: 24th - 25th November, 2018

Program a

| Medical Disorders in Pregnancy |
|---|
| Management of Hepatitis B Positive Pregnant Woman |
| Immunisation in Pregnancy: An update |
| Panel: Preconceptional Counselling: Optimising fetomaternal outcome |

| Contraception |
|--|
| Postpartum Contraception |
| Postabortal Contraception |
| Panel: Contraception in Situations “At Medical Risk” |

| Managing Difficult Situations: Structured approach |
|--|
| Intrapartum Maternal Death |
| Sudden Fetal Demise |
| Reversed end Diastolic Flows in Very Early Preterm Pregnancy |
| Lower Ureteric Injuries in Gynaecological Surgeries |

| Fetal Medicine |
|--|
| Dilemmas in Management of FGR |
| Vaginal Microbiome to Enhance Fetal Protection |
| Panel: Multiple Births: Optimising care |

| Labor: Evidence based update |
|--|
| Cervical Ripening; Tips, Tricks, and Pitfalls |
| Partogram: Ongoing changes |
| Interventions for Facilitating Normal Vaginal Delivery |
| Panel: Induction of Labor in Difficult Situations |

| Let's Improve the Care |
|--|
| Maternal Mortality: Lessons learnt from models of low resource countries |
| Respectful Maternity Care |
| Laqshaya: Quality Assurance GOI Initiative |

| Debate |
|---|
| Endometriomas should be Treated Surgically in all Infertile Women |
| All Women with Unexplained Infertility should be Offered IVF. |
| Laparoscopy is the Standard of Care for Ovarian Tumors |
| Panel: High Risk Obstetrics: Newer Challenges (Organ Transplant and Pregnancy, Bariatric Surgery and Pregnancy, IVF Pregnancies) |
| Panel: Pregnancy as a Window to Future: Fetal origin of adult disease and maternal outcome |

| Evolution of Management of Gynaecological Cancers |
|---|
| Genetics and Cancer: What a gynaecologist should know |
| Changes in Radicality of Surgery in Cervical and Endometrial Cancer |
| Panel: HRT in Cancer Survivors |

| Menopause: Age gracefully |
|--|
| Strengthening Life Beyond Menopause |
| Perimenopausal Turbulence: Management strategies |
| Panel: Premature Ovarian Insufficiency |

Conference AOGD

Venue: India Habitat Center, New Delhi

at a Glance



| Urogynecology: Enhancing competency |
|---|
| Overactive Bladder: Unaddressed issue |
| Obstetric Anal Sphincteric Injuries Fresh and Old |
| Panel: Tailoring the Surgical Approach to Uterovaginal Prolapse |

| Persistent Problems: Is there a solution |
|--|
| Recurrent Pruritis Vulvae |
| Chronic Pelvic Pain |
| Panel: Recurrent Endometriosis |

| Video Session (Obstetrics) |
|--|
| Evidence based Technique of Caesarean section |
| Adherent Bladder in Caesareans |
| Deeply Engaged Head / Free Floating Head |
| Morbidly Adherent Placenta: Decisions and skills |

| Video Session (Gynecology) |
|--|
| Tips and Tricks in Laparoscopic Hysterectomy |
| Facilitating Dissection in Vaginal Surgery |
| Complete Perineal Tear |
| Sacrohysteropexy |

| Competition Papers | Free Papers and Posters | Quiz |
|--------------------|-------------------------|------|
|--------------------|-------------------------|------|

| | |
|---|--|
| AOGD President's Oration : Dr Shalini Rajaram | Brigadier Khanna Oration : Dr J B Sharma |
| FOGSI President's Oration : Dr Jaideep Malhotra | Key Note Lecture |

Preconference Workshops

Date: 22nd -23rd November, 2018

| | Convenor | Co Convenors | Venue |
|---|---------------------------------------|--------------------------------------|-----------------------|
| Fetal Surveillance | Dr Manju Khemani | Dr Poonam Tara Dr Rinku Sen Gupta | Max Hospital Saket |
| Colposcopy | Dr Amita Suneja Dr Shalini Rajaram | Dr Rashmi Mallk Dr Bindiya Gupta | UCMS & GTB Hospital |
| Hysteroscopy | Dr K K Roy | Dr Garima Kachhwaha | AIIMS |
| Operative Obstetrics | Dr Mala Srivastava | Dr Kanika Jain Dr Mamta Dagar | Sir Gangaram Hospital |
| Ovulation Induction and Follicular Tracking | Dr Manju Puri | Dr Pikee Saxena | LHMC |
| Pelvic Reconstructive Surgery | Dr Amita Jain | Dr Rajesh Ahlawat | Medanta Medicity |

Events Held

- Quarterly Meet of the Society of Fetal Medicine With aegis of AOGD organized by Dept of Obs & Gyne UCMS, GTB Hospital Delhi on 29th August, 2018



- Monthly Clinical Meeting of AOGD on 31st August, 2018 at Safdarjung Hospital, New Delhi



- PG Training Program on Infertility organized by Infertility Subcommittee AOGD, Dept of Obs & Gyne Lady Hardinge Medical College on 1st September, 2018 at SJ Auditorium



- CME on Advances in Gynecologic Oncology under the aegis of Delhi Gyne Oncology Group and AOGD organized by Dept of Obs & Gynae Indraprastha Apollo Hospitals on 1st September, 2018



- CME on Adolescent Health by Adolescent committee AOGD organized by Dept of Obs & Gynae Fortis Hospital Shalimar Bagh on 4th September, 2018





40th Annual Conference of Association of Obstetricians and Gynecologists of Delhi

24th - 25th November, 2018

Venue: India Habitat Centre, Lodhi Road, New Delhi

REGISTRATION FORM

Full Name Qualification Institution

Speciality

Category: (Tick any) Delegate () PG Student () Faculty ()

Department Designation

Address City Pin Code.....

Mobile No. Landline No. E-Mail

AOGD Membership No.....

ACCOMPANYING PERSON'S Details

Name Age

THEME TOPICS FOR ABSTRACT SUBMISSION

1. Critically ill mother ()
2. Adolescent gynaecology ()
3. Gynaecological cancers ()
4. Endoscopy ()
5. Contraception ()
6. Miscellaneous ()

Guidelines for abstract submission on aogd.org

Last date for Abstract Submission for Free Communication and Poster: 15th September 2018

Preconference workshops (Tick any)

22nd November 2018

1. Fetal Surveillance ()
2. Colposcopy (live workshop) ()
3. Hysteroscopy ()

23rd November 2018

4. Operative obstetrics ()
5. Ovulation induction and follicular tracking ()
6. Pelvic Reconstructive surgery ()

Registration Fees: (Fees plus 18% GST)

| Conference | | | | Workshop | | |
|-----------------------|---------------------------------|-------------------------------|-------------------|------------------------------------|-------------------------------|-------------------|
| Registration Category | Upto 30 th Sept. '18 | Upto 30 th Oct '18 | Spot Registration | Upto to 30 th Sept. '18 | Upto 30 th Oct '18 | Spot Registration |
| AOGD Member | Rs. 5300 | Rs. 5700 | Rs. 5900 | Rs. 2400 | Rs. 2600 | Rs. 3000 |
| PG Student | Rs. 4700 | Rs. 5000 | Rs. 5300 | Rs. 1800 | Rs. 2100 | Rs. 2400 |
| Non- AOGD Member | Rs. 5900 | Rs. 6500 | Rs. 7100 | Rs. 2400 | Rs. 3000 | Rs. 3200 |
| Accompanying Person | Rs. 5100 | Rs. 5300 | Rs. 5700 | | | |

All DD/Cheque payable at New Delhi & should be made in favour of **"Association of Obstetricians and Gynecologists of Delhi"**

- ❖ Write your Name and Contact No. at the back of DD/Cheque
- ❖ Registration for the conference is mandatory in order to register for the pre conference workshops.

AOGDIANS above the age of 70 years are exempted from registration fees. Kindly submit copy of your Aadhar Card.

PAYMENT DETAILS

Please find enclosed herewith DD/Cheque No. Dated

Drawn on (Name of the Bank)..... Branch

For Rs. (In words)

FOR ONLINE TRANSFER THROUGH NEFT/RTGS

NAME OF BANK: CENTRAL BANK OF INDIA BRANCH: LADY HARDINGE MEDICAL COLLEGE BRANCH

NAME OF ACCOUNT: ASSOCIATION OF OBSTETRICIANS AND GYNECOLOGISTS OF DELHI

ACCOUNT NUMBER: 3674596638 IFSSC CODE: CBIN0283462 MICR CODE 110016067

REGISTRATION GUIDELINES

1. Conference registration is mandatory for registration for the pre conference workshops.
2. AOGDIANS above the age of 70 years are exempted from registration fees, please submit copy of your Aadhar card as age proof along with the duly filled registration form.
3. Post Graduates to attach a certificate from HOD and also should be an annual member of the AOGD in order to attend and present a paper.
4. Conference registration includes delegate kit, lunch & tea on 24th - 25th November 2018, participation in scientific session & exhibitions. No guarantee of delegate kit for spot registration.

CANCELLATION & REFUND POLICY

1. All cancellation should be made in writing and sent to AOGD secretariat.
2. All cancellation received before 15th Oct 2018 will be entitled for 75% refund of the amount paid.
3. All cancellation received between 15th Oct 2018 to 1st Nov 2018 will be entitled for only 25% refund of the amount paid.
4. No refund for cancellation made after 1st Nov 2018.
5. The refund process will begin only 30 days after the completion of the conference.

Secretariat

Department of Obstetrics and Gynaecology
Lady Hardinge Medical College and Smt Sucheta Kriplani Hospital, New Delhi-110001
Contact Tele 011-23408297, Shefali 9205292980, Email: secretarylhaogd2018@gmail.com

Management of Mullerian Agenesis

Karoon Agrawal¹, Deepti Gupta²

¹Director Professor, Dept of Burns, Plastic & Maxillofacial Surgery, VMMC & Safdarjung Hospital, New Delhi

²Senior Resident, Dept of Plastic Surgery, AIIMS, New Delhi



Dr Karoon Agrawal

Introduction

Mullerian agenesis is also known as Mayer-Rokitansky-Kuster-Hauser syndrome (MRKH) or vaginal agenesis. It is a congenital disorder that affects the reproductive system in karyotypic females (46,XX). It occurs in 1 out of every 4000-5000 females and is characterized by failure of growth of the Mullerian duct in the embryo resulting in atresia or agenesis of the fallopian tubes, uterus and upper two-thirds of vagina. As the lower part of the vagina does not evolve from Mullerian duct and instead develops from the urogenital sinus, it is present as a short blind canal or a dimple just posterior to the urethra. The ovaries are normal in structure and function owing to their separate embryologic source of development. Associated congenital malformations involving other systems are present in up to 53% of the patients.¹

MRKH is a multifactorial genetic syndrome with mostly a sporadic occurrence, however, familial clustering is seen in some cases suggestive of it being an autosomal dominant trait with incomplete penetrance. The etiology of MRKH syndrome is not yet clear, however certain chromosomal rearrangements and genetic mutations are thought to be responsible for its development. MRKH syndrome has two subtypes:²

1. Type 1/ Typical: Only the structures developing from Mullerian duct are affected
2. Type 2/ Atypical: Additional malformations in the form of renal and skeletal anomalies are present apart from agenesis of Mullerian duct derived structures. Kidneys may be abnormally formed or positioned or absent. Skeletal system is affected mostly in the vertebral region with presence of cervical vertebral fusion, hemivertebrae or scoliosis. Hearing loss and cardiac defects may also be present in females with Type 2 MRKH. The most severe form is known as MURCS (Mullerian duct aplasia-Renal agenesis- Cervicothoracic Somite Dysplasia).

Clinical Presentation

Thorough clinical evaluation is essential in diagnosing MRKH syndrome. This is the second most common cause of primary amenorrhoea after gonadal dysgenesis, accounting for 15% of the cases. Patients with MRKH syndrome usually present at puberty with complaint of absence of menstruation. Patients in whom uterine remnants are present may experience cyclical abdominal pain due to retrograde menstruation. Affected

adult females may also complain of inability to have intercourse or dyspareunia. On physical examination patients with Mullerian agenesis demonstrate normal growth and pubertal development. Presence of functional ovaries account for regular development of secondary sexual characteristics including thelarche and pubarche. Their height, body hair, breast development and external genitalia are normal. The vagina is present as a short canal without a cervix at the apex or as a shallow indentation, dimple, posterior to the urethra.^{1,3}

Differential Diagnosis

Differential diagnosis for a patient with normal secondary sexual characteristics presenting with primary amenorrhoea and a short vagina include:^{4,5}

1. Imperforate hymen
2. Transverse vaginal septum
3. Congenital absence of vagina
4. Cervical atresia
5. 46,XY disorders of sex development including androgen insensitivity syndrome (AIS) and 17 α -hydroxylase deficiency.

Investigations

Clinical examination is supplemented by investigations to establish the diagnosis of Mullerian agenesis and rule out the above mentioned differentials.

1. Karyotyping
2. Hormone profile
3. Imaging
 - a. Trans abdominal/ Translabial/ Transrectal ultrasonography
 - b. Magnetic resonance imaging (MRI)
 - c. Laparoscopy
4. Investigations for assessment of associated anomalies

Karyotyping and Hormone profile: Help in differentiating patients with Mullerian agenesis from those with androgen insensitivity syndrome. Patients with MRKH are typically 46,XX with presence of normal levels of serum luteinizing hormone (LH), follicle stimulating hormone (FSH), and 17 β -oestradiol and absence of hyperandrogenism. Normal hormone levels are attributed to presence of normal functioning ovaries in these patients. On the other hand, a patient with AIS

would be 46,XY with serum testosterone in the typical male range. Diagnosis of 17 α -hydroxylase deficiency in patients with 46,XY karyotype is confirmed by elevated levels of serum deoxycorticosterone and corticosterone, low levels of serum cortisol, androgens, and estrogen and, by testing of the CYP17A1 gene.^{1,5}

Trans-abdominal/ trans-labial/ trans-rectal ultrasonography: Ultrasonography is a simple technique to use and is non-invasive in nature. It is used as the initial diagnostic modality for internal anatomical evaluation and identification of mullerian structures. Absence of uterus is noted between the bladder and the rectum in patients with mullerian agenesis. If a typical midline uterus is present, it suggests the presence of obstructing uterine or vaginal anomalies. Rudimentary mullerian structures are found in 90% of the patients with mullerian agenesis. However, it is often difficult to delineate uterine remnants or any other rudimentary structures due to the presence of bowel loop peristalsis and acoustic shadows.^{1,5}

Magnetic Resonance Imaging: It is performed when ultrasonographic findings are inconclusive or incomplete. MRI is a non-invasive technique and has a higher sensitivity and specificity than that of ultrasonography in picking up the presence of mullerian remnants. It can also identify activity of the endometrium within these structures. Subperitoneal structures are also better assessed with this imaging modality. With the aid of MRI, we can clearly visualize the anatomical structures in multiple planes. Uterine anomalies are best characterized on a sagittal plane, whereas, vaginal anomalies are best analysed on transverse cuts. It is also used to evaluate any associated anomalies of the renal and the skeletal system in the same sitting.⁶

Laparoscopy: It is usually reserved for surgical interventions such as Vecchietti procedure or excision of uterine remnants. Sometimes, it may be carried out in patients presenting with pelvic pain to make a diagnosis and provide a solution for the same. For example, it may play a role in precise anatomical delineation of an uterine remnant with active endometrium which is resulting in endometriosis because of retrograde menstruation. This remnant can then be surgically excised in the same sitting thus, causing an improvement in pelvic pain.¹

Investigations for assessment of associated anomalies: Renal ultrasound, echocardiograph, audiometry, intravenous pyelography, spinal X-rays and other skeletal studies should also be performed to detect associated congenital anomalies.

Counselling and Future Options for Having Children

Being diagnosed with Mullerian agenesis is psychologically devastating for young women. They experience anxiety and are distressed with their infertility. Counselling should be offered to the patients along with their

families to address their queries and allay their anxiety. Patients are also motivated to get in touch with peer support groups which help them in understanding their situation better and allow them to come to terms with the diagnosis.

Treatment options including the timing and techniques for neo-vagina creation are explained in detail to the patient, so that she can take an informed decision and participate actively in her treatment. Surgery can help in achieving normal sexual function, but the patients remain infertile. Options for having children in the future are discussed. It is explained to the patients that they can become mothers with their own eggs through artificial reproductive techniques along with gestational surrogacy.⁷ Adoption is also elucidated as an option to these patients. Uterine transplantation as a treatment is still in experimental stages and yet to become commonly available.

Management

The goal of treatment is to create an unscarred, properly placed vagina of adequate length, to enable the woman to have sexual intercourse. Treatment is commenced when the patient is physically and emotionally mature enough to understand and carry out self-dilatation. The various treatment options are:

1. Non-surgical: Progressive dilatation
 - a. Intermittent pressure: Frank
 - b. Bicycle seat: Ingram
2. Surgical
 - a. Dissection of retrovesical space and resurfacing with tissue over a mould
 - i. Skin graft (McIndoe)
 - ii. Peritoneum (Davydov)
 - iii. Buccal mucosal graft
 - iv. Amnion
 - v. Autologous in-vitro cultured vaginal tissue
 - vi. Xenogenic submucosal graft
 - b. Progressive traction on retrohymenal space (Vecchietti procedure)
 - c. Vulvovaginoplasty
 - i. William's vulvovaginoplasty
 - ii. Creatsas modification of William's vulvovaginoplasty
 - d. Intestinal neovagina
 - e. Implantation of Tissue engineered vagina

Non-surgical creation of neovagina

It is recommended as the first line of treatment for patients with a short vagina or a vaginal dimple. Success rates of 90-95% have been reported in motivated and well counselled patients.¹ The technique is safe, non-invasive and has a low complication rate. Two methods are used for vaginal dilatation⁸:

- a. Frank's method: In this a vaginal dilator is applied with pressure in a posterior direction to the vaginal dimple, twice a day for 20-30 minutes. The dilators are then gradually increased in length and diameter over time.
- b. Ingram's method: It is a passive technique in which patients are made to sit on a dilator in a titled forward position on specially designed bicycle seat, leaving their hands free for other work. It is useful for those patients who find it difficult to maintain the awkward position required for Frank's method.

Before commencement of dilatation, the clinician should make sure that the patient is able to correctly identify the location and angle for placement of the dilator. Patient should be taught to self-examine and identify her urethra and distal vagina with a mirror. A close weekly or bi-weekly follow up is needed for monitoring the progress and to keep the patient driven. It is also necessary to identify any complications early, if present. Compliance plays a significant role in outcome of the therapy as the method is self-administered. Lack of privacy, poor motivation and discomfort during dilatation are common reasons for abandoning the procedure. Therefore, it is of utmost importance for the health care provider to be a source of constant motivation and ensure adherence to the regimen, for a successful treatment.

A functional length of vagina can generally be achieved over a few months. Most studies consider a length of 6 cm as a measure of success for the process of dilatation.^{1,8} However, any length achieved that is comfortable enough for sexual activity, as conveyed by the patient, is the definition of success. After successful completion of dilatation, patients should be informed that they would require further intermittent dilatations. if they are not engaging in regular sexual intercourse.

Although a safe technique, a few complications have been reported with it. Inadvertent dilatation of the urethra is best prevented by frequent monitoring on an outpatient basis. Patients can also experience pain and bleeding, necessitating a clinical evaluation for presence of vaginal abrasions. This can be prevented by use of adequate lubrication and softer dilators. Rarely, urethritis, cystitis or vaginal prolapse may develop requiring further assessment and treatment.

Surgical Creation of Neovagina

Surgery is indicated in those patients in whom dilatation techniques have been unsuccessful or those who opt for it consciously after being provided with the various options. Several techniques are available for surgical creation of neo-vagina. The surgeon's experience with the operation being performed is important for a successful outcome. The surgical plan should be elucidated for the patient in detail along with its possible complications. Patients should also be informed about the need for regular dilatation or sexual intercourse in the post-operative period, to maintain the length and

patency of the newly created vagina. Patients should be followed up closely after the surgery, for early detection of any complication or untoward sequelae.

One of the most popular surgical procedure for constructing the vagina is Abbe Wharton McIndoe vaginoplasty. It consists of first creating of space between the bladder and the rectum with the help of blunt dissection. A split thickness skin graft harvested from the thigh or buttocks is sutured over a mold with dermis facing outwards. The mold is then placed in the newly formed cavity to line its wall with the skin graft. The mold is used continuously in the initial period followed by regular intermittent to maintain patency. In modifications of this technique, other lining materials such as buccal mucosa, artificial dermis, peritoneum, autologous in-vitro cultured vaginal tissue have been used with variable results. Successful results have been stated in 80-100% of the cases but this procedure needs long-term dilatation for prevention of neovaginal stenosis, which can result in dyspareunia and post-coital bleeding.^{8,9}

Other procedures for vaginal creation include the Vecchiotti operation, which uses a traction device attached to the abdomen connected olive placed in the vaginal dimple, for creation or lengthening of the vaginal vault. This can be carried out laparoscopically or as an open procedure. Another procedure, Williams vaginoplasty, uses a vulval flap to create a vaginal tube. The abnormal angle of the neovagina, which was a problem with the original procedure has been corrected with Creatsas modification.⁸ The surgery is safe, simple to perform and does not require regular dilatation with vaginal molds for maintenance. Bleeding, wound dehiscence and infection are a few problems faced with this technique. An alternative to above mentioned procedures is to create a neovagina from a bowel segment. An isolated segment is generally preferred for the same. A long vaginal length can be achieved, which grows along with the growth of the patient and has a low risk of stenosis. The neovagina is self-lubricating and excellent results have been reported. However, the surgery is more invasive and complex than other procedures and, associated with complications such as infection, bad odor and vaginal discharge. There is also a potential for development of mucinous adenocarcinoma with the use of bowel segment.^{8,10}

Currently there is no unanimous agreement as to which technique has the best functional outcome. All the surgical techniques described, require thorough care in the post-operative period and a close follow up for a long-term success. Implantation of tissue engineered vagina is another latest development that merits a mention. Vaginal organs made from cultured vulval tissue from seeded onto a biodegradable scaffold have been successfully implanted in women requiring vaginal reconstruction. However, this procedure is complex to carry out and very expensive.¹¹ Another breakthrough in the field of reproductive medicine is uterine transplants. It is still in the experimental stages and extensive

research is needed before it becomes available as a viable treatment option.¹²

Summary and Conclusion

Patients of Mullerian agenesis are usually identified when they are evaluated for primary amenorrhea. Ultrasonography and MRI together clinch the diagnosis. Clinical evaluation, accurate diagnosis and ruling out associated congenital malformations are of utmost importance. Management involves detailed counseling of the patient and the family members to address the functional and psychosocial aspects. Non-surgical vaginal elongation is the first line of treatment as it is safer, well controlled and cost effective. Surgical intervention if required should be carried out by an experienced surgeon as first time is the best opportunity. Although infertility in these patients cannot be treated, options for becoming a parent are available through advanced reproductive techniques.

References

1. Committee on Adolescent Health Care. ACOG Committee Opinion No. 728: Müllerian Agenesis: Diagnosis, Management, And Treatment. *Obstet Gynecol.* 2018;131(1):e35-e42.
2. Guerrier D, Mouchel T, Pasquier L, Pellerin I. The Mayer-Rokitansky-Küster-Hauser syndrome (congenital absence of uterus and vagina) - phenotypic manifestations and genetic approaches. *J Negat Results Biomed.* 2006;5:1.
3. Herlin M, Bjorn AM, Rasmussen M, Trolle B, Petersen MB. Prevalence and patient characteristics of Mayer-Rokitansky-Küster-Hauser syndrome: a nationwide registry-based study. *Hum Reprod.* 2016;31(10):2384-90.
4. Morcel K, Camborieu L, Programme de Recherches sur les Aplasies Müllériennes (PRAM), Daniel Guerrier. Mayer-Rokitansky-Kuster-Hauser Syndrome. *Orphanet J Rare Dis.* 2007;2:13.
5. Choussein S, Nasioudis D, Schizas D, Economopoulos KP. Mullerian dysgenesis: a critical review of the literature. *Arch Gynecol Obstet.* 2017;295(6):1369-81.
6. Boruah DK, Sanyal S, Gogoi BB, Mahanta K, Prakash A, Augustine A, et al. Spectrum of MRI Appearance of Mayer-Rokitansky-Kuster-Hauser (MRKH) Syndrome in Primary Amenorrhea Patients. *J Clin Diagn Res.* 2017;11(7):TC30-TC35.
7. Smotrich DB, Ross RJ, Batzofin D. Congenital absence of the uterus known as Mayer-Rokitansky-Kuster-Hauser (MRKH) syndrome and gestational surrogacy (GS) over a 10 year period - a means to an end. *Fertility and Sterility.* 2009;92(3):S255.
8. Stanheiser J, Attaran M. Congenital Mullerian Anomalies: Disgnosis and Management. Switzerland: Springer Nature;2016. Chapter 6, Mullerian Agenesis: Diagnosis, Treatment and Future Fertility;p 65-78.
9. Chaudhary R, Dhama V, Singh S, Azad R. Vaginoplasty in mayer Rokitansky-Kuster-Hauser syndrome using amnion: a case series. *International Journal of Reproduction, Contraception, Obstetrics and Gynecology* [online]. 2016 Dec [cited 28 Aug 18];5(11):3832-9. Available at: <http://www.ijrcog.org/index.php/ijrcog/article/view/348>.
10. Torres-de la Roche LA, Devassy R, Gopalakrishnan S, de Wilde S, Herrmann A, Larbig A, et al. Plastic neo-vaginal construction in Mayer-Rokitansky-Küster-Hauser syndrome: an expert opinion paper on the decision-making treatment process. *GMS Interdiscip Plast Reconstr Surg DGPW.* 2016; 5: Doc08.
11. Raya-Rivera AM, Esquiliano D, Fierro-Pastrana R, López-Bayghen E, Valencia P, Ordorica-Flores R, et al. Tissue-engineered autologous vaginal organs in patients: a pilot cohort study. *Lancet.* 2014;384(9940):329-36.
12. Johannesson L, Järholm S. Uterus transplantation: current progress and future prospects. *Int J Womens Health.* 2016; 8:43-51.

Uterine Transplantation

Varsha Priyadarshini¹, Amita Suneja²

¹Senior Resident, ²Director Professor & Head, Department of Obstetrics & Gynaecology, UCMS & GTB Hospital, Delhi



Dr Amita Suneja

Introduction

Uterine transplant is a novel and miraculous invention in the field of obstetrics and gynaecology after in vitro fertilization [IVF]. Given the promising results of uterine transplant in the limited studies available till date, there is no doubt that it will prove to be a boon for patients suffering from absolute uterine factor infertility [AUFI] in near future. So far uterine transplant has been used in cases of Mullerian agenesis, Ashermann's syndrome, post-Wertheim & peripartum hysterectomy survivors.

History

The first uterine transplant studies were carried in the 70's with the primary aim to circumvent the problem of tubal factor infertility by transplanting the fallopian tube. These were experimental animal studies and uterus was transplanted along with the fallopian tubes for ease of surgical procedure. With the advent of IVF, considerable interest was lost in the field of uterine transplant which got rediscovered only in the late 90's when AUFI became the largest untreatable fraction of all causes of infertility. Several animal experiments were taken up and the first live birth was reported in an allogenic mouse model in 2003.

Human Transplant Cases

The first human attempt at uterine transplant was made in Saudi Arabia in 2002. The donor was a 46 year old premenopausal lady undergoing hysterectomy for bilateral benign ovarian cysts and the recipient, a 26 year old woman who underwent peripartum hysterectomy. On day 99 the patient presented with pelvic heaviness and discharge and the infarcted uterus was subsequently removed. Despite the failure of the graft, this study proved that uterine transplant was possible in a live donor scenario. However in the light of early graft failure, it was clear that more animal experiments were necessary before any new clinical attempts should be undertaken.

The second case was reported from Turkey in 2011. The uterus was retrieved from a young deceased female and transplanted in a 21 year old woman with MRKH [Mayer-Rokitansky-Kuster-Hauser] syndrome. Multiple embryo transfers were done postoperatively, two pregnancies were reported, none was viable.

The above two experiments were criticized for not conforming to proper research protocols.

25 published human transplant procedures have been performed till date. However the most important trial of all was the clinical series carried out at University Hospital at Gothenburg University, Sweden.

Successful uterine transplant

Swedish Trial - In 2013, Brännström et al carried out a series of 9 human uterine transplant cases using live donors. This trial has proven to be a landmark study as it was the first successful clinical trial of its kind with a highly satisfactory outcome (6 healthy live births out of 9 transplant procedures). The details of these patients are given in Table 1.

Table 1: Summary of Swedish transplantation cases

| Recipient Diagnosis | Graft success | Pregnancy |
|---------------------|---------------|-----------|
| Cervical cancer | ✓ | ✓ |
| MRKH | × | × |
| MRKH | ✓ | ✓ |
| MRKH | ✓ | ✓ |
| MRKH | ✓ | ✓ |
| MRKH | ✓ | × |
| MRKH | ✓ | ✓ |
| MRKH | ✓ | ✓ |
| MRKH | × | × |

Single embryo transfers were done 12-14 month post transplant. 2 patients conceived in their first attempt. *The first live baby was born in September 4, 2014.* This patient, a case of MRKH with unilateral renal agenesis, developed preeclampsia at 31+5 weeks for which cesarean section was done the following day. The second baby was delivered by cesarean section at 34+4 weeks. 4 more healthy babies were born from the trial.

Another successful attempt was carried in the United States in 2017 at Baylor Medical centre, Dallas, USA. The recipient was a lady suffering from MRKH while the organ was taken from an altruistic donor. The study was different from the Swedish studies as the transplanted uterus survived and sustained pregnancy on the utero-ovarian vein serving as the only venous outflow.

Uterine Transplant in India - Not far from the Swedish trial, India too boasts now of having entered the era of uterine transplant. The first uterine transplant in India was performed on May 18, 2017, by Dr Shailesh Puntambekar and his team in Galaxy Care hospital Pune. The recipient, 22 year old Shivamma Chalgeri from Solapur, suffering from MRKH, received the organ from her mother. However she underwent a miscarriage at 6 weeks after the first embryo transfer. Another woman,

27yr old Meenakshi Valand from Bharuch, Gujarat, suffering from Ashermann's Syndrome also underwent transplant on May 19, 2017 in the same hospital. She has recently completed 5 months of pregnancy and is all set to become the mother to the first uterine transplant baby in India. Meanwhile Dr Puntambekar and team have performed 6 transplants till date and undoubtedly will be known as the pioneers of uterine transplant in India. They have performed the first-ever laparoscopic assisted live organ donor retrieval in the world and simplified the procedure of transplant using donor ovarian vein for the venous outflow in recipient. [presented by Dr Puntambekar during DGES-ESGE conference 2018]

Uterine Transplant- Procedure

I. Preoperative preparation- The donors and recipients are extensively screened in preoperative period for any medical and psychological factors. The recipients additionally undergo IVF treatments and their embryos are cryopreserved.

II. Surgical Aspect

A) Donor surgery- Donors can be living or deceased. Using a midline incision, uterus without fallopian tubes along with supporting ligaments is carefully dissected out. Bilateral vascular pedicles that include both uterine arteries along with portion of internal iliac distal to the origin of superior gluteal artery and both uterine veins along with part of internal iliac veins are carefully dissected from the ureters. A portion of donor vagina enough for anastomosis is sectioned out. Rectovaginal space is thence dissected and the uterus along with bilateral pedicles is taken out and brought for back table processing where it is flushed with preservative solution.

B) Recipient surgery- the recipient surgery includes 3 things [Figure 1]

- Anastomosis of uterus to vagina
- Anastomosis of vascular pedicles to external iliacs of the recipient in end to side fashion
- Anastomosis of uterus to pelvic ligaments for support

III Postoperative immunosuppression, rejection-monitoring and conception

Immunosuppression is an unavoidable part of any transplant surgery, owing to the phenomenon of rejection. Following the surgery, immunosuppression is given in the postoperative period. During and immediately post-transplantation, high levels of immunosuppressants are required which is achieved via induction therapy to prevent acute rejection in the first postoperative month. Patient is thence shifted to maintenance therapy that maintains low levels of immunosuppressants in the blood. Finding the most favourable immunosuppression regimen is a careful balancing act between adequate prevention of rejection and minimizing the adverse effects of the drugs. The immunosuppression protocols used in Swedish studies is given in table 2.

Table-2: Immunosuppressant protocols used in Swedish trial

| | Immunosuppression Protocol | |
|----|--|---|
| | Induction | Maintenance |
| 1. | MMF, methylprednisolone and anti-thymocyte globulin. | TAC, MMF and oral glucocorticosteroids |
| 2. | Anti-thymocyte globulin and methylprednisolone. | TAC and MMF (First 6 months). MMF replaced by Azathioprine and Methylprednisolone after that. |

TAC = tacrolimus

MMF = mycophenolatemofetil

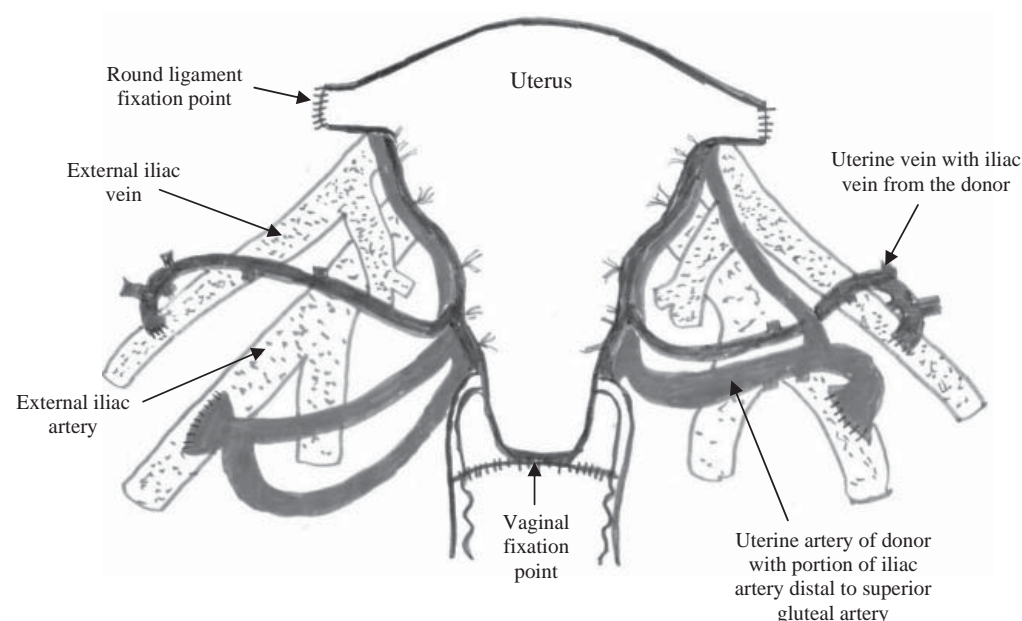


Fig. 1: Schematic diagram of transplanted uterus [Adapted from Brännström et al]

Rejection of the graft is a common concern in the postoperative period. Clinical detection of rejection in uterine transplant can be made only when there is significant graft damage. In order to ensure long term viability of the graft, early detection of rejection is necessary. Unlike other organ transplants like liver and kidney, uterus lacks any specific laboratory markers for early detection of rejection. To circumvent this problem, a minimally invasive method of monitoring rejection in uterine transplant in form of cervical biopsies was developed. A rejection grading system was also developed subsequently classifying rejection into no, mild, moderate and severe rejection. Subclinical rejection episodes can be tackled using additional immunosuppressants.

The cryopreserved embryos are transferred in the grafted uterus after it has been adequately monitored. This may take many months [12-14 months in Swedish trial]. The woman is carefully monitored in antenatal period. The baby is delivered by planned cesarean section. The immunosuppression regimen is continued throughout pregnancy and after that till the grafted uterus is in situ, i.e. till the family is complete, after which the allograft uterus is removed. The effects of these drugs on pregnancy are a major concern. Food and Drug Authority [FDA] has issued a list of immunosuppressants and their safety profile in pregnancy [Table 3].

Table 3: FDA Classification of Immunosuppressants in pregnancy

| | FDA Safety Classification | Toxicity |
|--------------|---------------------------|--|
| Steroids | B | No evidence of teratogenicity. |
| Cyclosporine | C | Low birth weight, No evidence of increased rate of malformations |
| Tacrolimus | C | Transient hyperkalemia, preterm birth and nephrotoxicity. |
| Azathioprine | D | Prematurity, low birth. |
| MMF | D | Miscarriage, fetal malformations. |

Live Versus Deceased Donation

Procuring a specimen of uterus from deceased donors is more convenient as the surgical dissection is easier, takes shorter time, longer vascular pedicles can be procured and there are practically no surgical risks as far as donor surgery is concerned. However shortage of suitable organs from deceased donors is a major obstacle to deceased donations. Another drawback of deceased donors is the effect of prolonged ischemia and systemic inflammation that might theoretically lead to poor graft quality although studies have reported

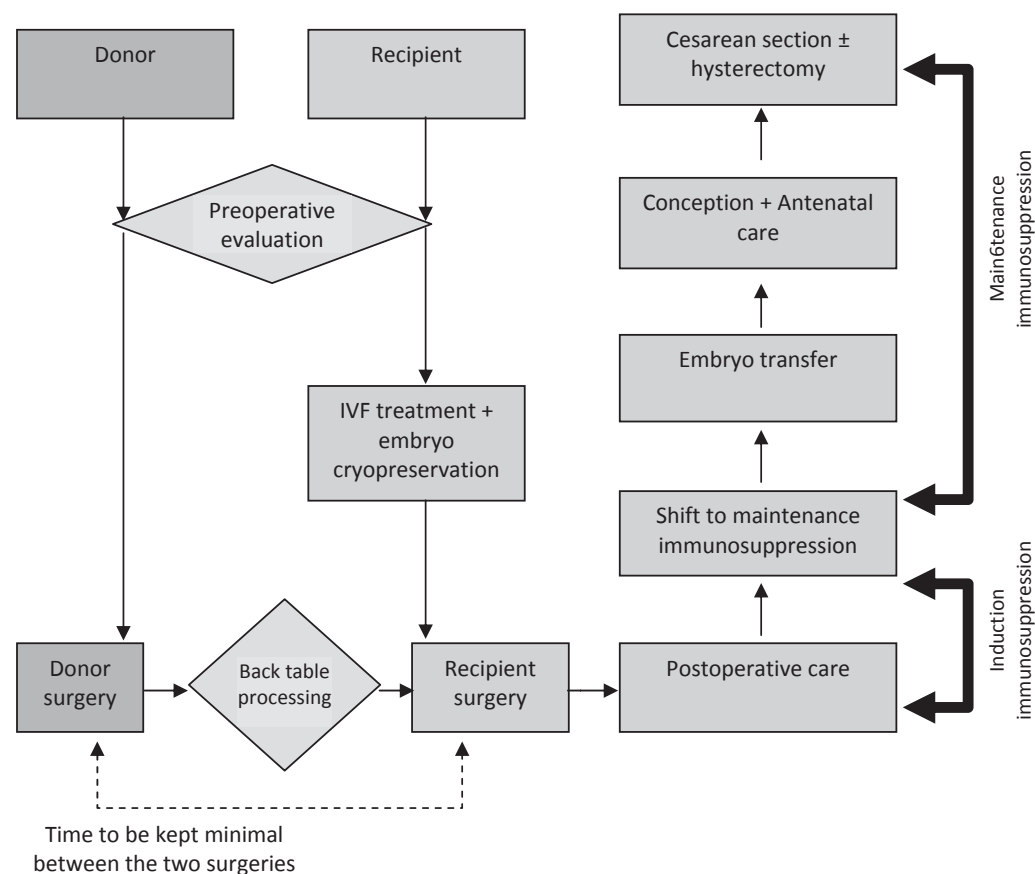


Fig 2: Flowchart of uterine transplant procedure

maintained histological integrity and prostaglandin induced contractions as long as 24 hours after uterine retrieval in appropriate solutions.

Live donation has its own set of disadvantages, the prime being procurement of shorter vascular pedicles owing to difficult surgical dissection in a live donor. This also leads to longer operative time and risk of injuries to adjacent structures causing significant postop morbidity. The first live donor [Saudi Arabia] suffered from a ureteral wall injury that was repaired intraoperatively. The third live donor [Sweden] had a ureterovaginal fistula by day 16 that was managed by a pyelostomy tube in situ and ureteric reimplantation on day 134.

However the quality of graft from a live donor is better due to shorter ischemia time. The donor and recipient surgeries are generally coordinated so that ischemia time is kept to a minimum. Also being a non-vital organ, live uterus donations are easier to achieve compared to other organs of the body.

Future of Uterine Transplant

The future calls for further improvement in surgical technique that may pave way for minimally-invasive and robotic-assisted live donor retrieval. This is already being demonstrated in the recent transplant surgeries and shall minimize surgical time and risk to the donor. The latest study from USA used significant shorter transplant to embryo-transfer window period that shall minimize the toxic effects of immunosuppressants like hypertension, diabetes and nephrotoxicity on the recipient.

Bioengineered uterus is another way to overcome the problem of immunosuppressant-toxicity. The basic principle behind a bioengineered uterus is cellularisation of a synthetic or a biologically derived uterine scaffold by the patient's own stem cells. The biologically derived uterine scaffold resembles the native organ except that it has been decellularised of immune activating cells and what remains is the three dimensional extracellular matrix with preserved vascular conduits, collagen, glycosaminoglycans, fibronectin, laminin which in turn provide signals for cell signalling (adhesion, migration, proliferation and differentiation). Use of bioengineered uterus may preclude the need for immunosuppressants altogether as there will be minimal concerns of rejection using this model.

The concept of bioengineered uterus is still in its infancy and experimental stage. Till now very few animal

studies of successful repopulation of uterine scaffolds is available. However, the efforts are relentless and hopes are high and who knows in near future one may get to witness a new era of organ engineering technology like never before.

Ethical Concerns

Uterine transplant, notwithstanding the success, remains a complex procedure with potential risks to both donor and recipient and has raised ethical concerns. To address this issue, the revised Montreal criteria were developed that lay guidelines for the recipient, donor and the medical staff in order to consider a transplant ethically acceptable.

Conclusion

Uterine transplant may not be a life saving surgery, but the way it transforms the life of a woman desirous of pregnancy is unimaginable. In the words of Dr. Testa, the pioneer of uterine transplant in U.S. 'We do transplants all day long. This is not the same thing. I totally underestimated what this type of transplant does for these women. What I've learned emotionally, I do not have the words to describe.'

In conclusion, uterine transplant has promised to give hope to hundreds of thousands of women who had unwillingly accepted their fate of never being able to conceive. The procedure is novel, its challenging, it's exciting and with the current efforts of surgeons, there is no doubt that it will be the most discussed topic ever in the field of obstetrics and gynaecology.

Recommended Reading

- Brännström M. Uterus transplantation and beyond. *J Mater Sci Mater Med*. 2017; 28(5):70.
- Johannesson L, Järvholm S. Uterus transplantation: current progress and future prospects. *Int J Womens Health*. 2016;8: 43-51.
- Ejzenberg D, Mendes LR, Haddad LB, Baracat EC, D'Albuquerque LA, Andraus W. Uterine transplantation: a systematic review. *Clinics (Sao Paulo)*. 2016; 71(11): 679-683.
- Testa G, McKenna GJ, Gunby RT Jr, Anthony T, Koon EC, Warren AM, et al. First live birth after uterus transplantation in the United States. *Am J Transplant*. 2018;18(5): 1270-1274.

CONTROVERSY

Surgical Treatment in Nulliparous Women with Intrauterine Septum



Dr Pramathes Das Mahapatra

Pramathes Das Mahapatra¹, Mayoukh Kumar Chakraborty²

¹Director, ²Registrar, Spectrum Clinic & Endoscopy Research Institute, Kolkata

The most common type of congenital uterine anomaly is Septate uterus resulting from incomplete fusion of Mullerian ducts. The European Society for Human Reproduction and Embryology (ESHRE) and European society of Gynaecological Endoscopy (ESGE), updated a useful classification system. The uterine septum (category U2) is defined as an indentation at the fundal midline exceeding 50% of the uterine wall thickness¹ with normal uterine outline. The true incidence of Mullerian anomaly in general population is not known. However, a meta-analysis of 94 observational studies with 90,000 women showed prevalence of 5.5% in the general population, 8.0% in infertile women, 13.3% in those with history of miscarriage and 24.5% in those with miscarriage and infertility². There is insufficient evidence that uterine septum is associated with infertility.

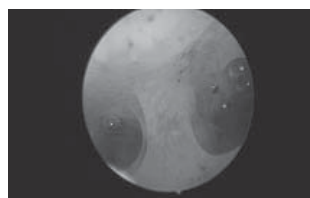
It is our clinical experience that septate uterus of any form is associated with higher first and second trimester abortion rates, preterm labour, abnormal presentation and labour, IUGR, morbid adherent placenta and infertility. Causes of these complications are:

1. Mechanical factors
 - Uterine cavity distortion
 - Increased intrauterine pressure
 - Associated cervical incompetence
2. Other factors
 - Compromised uterine blood supply at the septum
 - Possible changes in the oestrogen and progesterone receptor expression

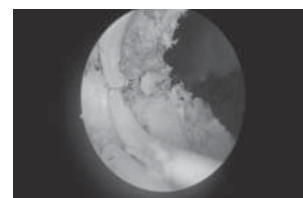
About 20-25% of women with septate uterus experience complications of which recurrent miscarriage and pre term labour are most common. Therefore, it is expected that majority of women with uterine septum are likely to conceive naturally and deliver normally. In the past, septate uterus was diagnosed mainly by HSG for recurrent miscarriage or during caesarean section for malpresentation. or suspected after failed ECV. With the advent of modern diagnostic tools especially 3D USG and MRI the diagnosis has become simpler.

It is a matter of debate whether to perform metroplasty in an asymptomatic nulliparous woman. It is a preventive procedure and modern medicine emphasises the importance of prevention of complication. The uterus in a nulliparous woman, is an untried horse which may or may not win the race. We should not forget that the concept of modern management of pregnancy has completely changed over the years.

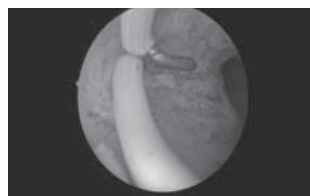In the existing society none is prepared to accept any adverse outcome in a woman known to have uterine anomaly. How do we predict the uncomplicated pregnancy outcome in nulliparous woman with uterine septum? In addition, understandably there is no room for guessing and praying for good luck. A woman should be allowed to go for pregnancy preferably with normal uterine cavity.



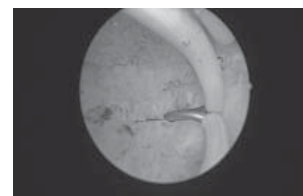
Incomplete Septate Uterus



Septum Resection in Progress



Bipolar resection of septum



Septum resection at the fundus

Prevention of possible complications as mentioned above is the primary aim of the surgical treatment. Therefore, prophylactic correction of abnormality is essential. The surgical procedure has changed dramatically. Alas! gone are the days of hysterotomy for excision of septum resulting intrauterine synechiae. In recent years, hysteroscopic septum resection by energy sources like LASER, bipolar or monopolar is regarded as a simple and safe technique.

The complications of metroplasty like incomplete resection, cervical tear, uterine perforation and fluid overload are rare. However, recent literature complication of uterine rupture in 2nd and early 3rd trimester with high maternal mortality and unsatisfactory foetal outcomes has raised the issue of its safety. Uterine rupture is a very rare but unpredictable occurrence. Interestingly regarding uterine congenital anomalies, in the overall literature 5 cases of uterine rupture (UR) are reported. However only one case of uterine rupture in a septate uterus without any history of surgical correction was reported by Domiani et al³.

Scientific evidence indicates a clear association between septate uterus and poor pregnancy outcome and subsequent improvement after resection. In the hands of an experienced surgeon the safety

of hysteroscopic metroplasty is commendable and acceptable. Therefore, there should be no hesitation in correcting the uterine anomaly even in nulliparous women. Nevertheless, hysteroscopy surgeon should respect the muscle thickness at the fundus during the procedure and the patient should be warned about the very rare but life threatening complication. In my own series of 132 septum resection, there was no uterine rupture.

Various studies, mainly retrospective, have assessed the efficacy of the septum resection to restore normal uterine anatomy. The COCHRANE database study (up to May 2016) showed significantly higher pregnancy rate in women with a septate uterus who were treated with surgery^{3,4}.

References

1. Grimbizis GF, Gordts S, Di Spiezio Sardo A, Brucker S, De Angelis C, Gergolet M et al (2013) The ESHRE - ESGE classification of female genital tract congenital anomalies. *Gynecol Surg* 10(3):199-212
2. Chan YY, Jayaprakasan K, Zamora J, Rainne-Fenning N, Coomaraswamy A (2011) The prevalence of congenital uterine anomalies in unselected and high-risk populations: a systematic review. *Hum Reprod* 17(6):761-771
3. COCHRANE database Gaucherand 1994; Pary 2011; Tonguc 2011.
4. COCHRANE database Heinonen 1997; Kirk 1993; Lin 2009; Maneschi 1991; Sigiura-Ogasawara 2013; Vali 2004
5. Domiani et al. Uterine rupture in a nulliparous woman with septate uterus of the second trimester pregnancy and review of literature. *Int. J Surg. Case Rep* 2013; 4(3): 259-261

Answer to Quiz: August Issue

Congratulations to Dr Anu Handa and Dr Anita Rajohria
for answering the quiz and crossword correctly

Answer Key for Crossword August issue

Down: 2. Electromyography 4. PTNS 7. Qmax 8. Audit 9. STAN

Across: 1. Duloxetine 3. ERCS 5. Mirabegron 6. LaQshya 10. Dakshata

Answer Key for pictorial quiz August issue

Figure 1: Ans 1. CTG graph showing sinusoidal pattern

Ans 2. Severe fetal anemia or fetal hypoxia

Ans 3. An increased variability exceeding 25 bpm lasting more than 30 minutes

Figure 2: Ans 1. Multi channel cystometry

Ans 2. Detrusor overactivity

Cervical Agenesis/ Dysgenesis

Rashmi Ahuja¹, Usha Gupta²

¹Assistant Professor, ²Professor & HOD Obst & Gynae, ESIC Medical College and Hospitals, Faridabad



Dr Usha Gupta

Introduction

Maldevelopment of the Mullerian ducts may occur in a variety of forms, and each anomaly is distinctive. Congenital conditions can affect the vulva, vagina, cervix, uterus, fallopian tubes and ovaries of female fetuses. Some can be detected at birth but many are not diagnosed till they become symptomatic later on. Birth defects of the cervix or uterus are very rare, accounting for 4 percent of female babies¹. Cervical agenesis or dysgenesis is an extremely rare congenital anomaly with an occurrence of about 1 in 80,000 to 100,000 births². Congenital malformations of the cervix are rarely seen alone and are frequently associated with other uterine and vaginal anomalies.

The cause of the Mullerian anomalies is not very clear and cannot be attributed to one cause. It can be hereditary, any random gene mutation, exposure to certain teratogens or a development defect¹.

Classification

A number of classifications of the uterovaginal anomalies have been proposed like by American Fertility Society Classification and ESHRE classification.

According to AFS, Cervical agenesis or dysgenesis comes under class II B³:

Disorders of the vertical fusion of Mullerian ducts, which includes

A. Transverse vaginal septum

1. Obstructed
2. Unobstructed

B. Cervical dysgenesis or agenesis

Cervical aplasia or agenesis (Fig 1.) in which there is absence of the uterine cervix in the woman: The uterus is susceptible to torsion on its horizontal axis, particularly with the mass effect of hematometra.

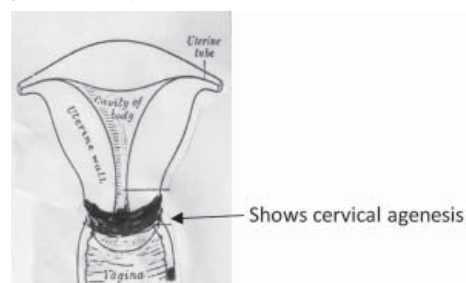


Fig 1.

Cervical dysgenesis cases can be stratified into one of the three groups.

In the first group, there exists a well formed cervix, with normal length and width along with normal stromal tissue and muscle fibres but there may be obstruction in it at the level of (Fig 2)

- a) internal cervical os only
- b) external cervical os only

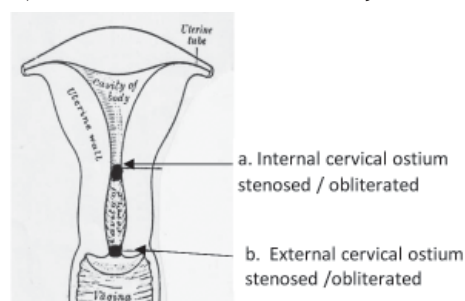


Fig 2. Cervical dysgenesis - a & b.

- c) may partially involve the endocervical canal (Fig 3).

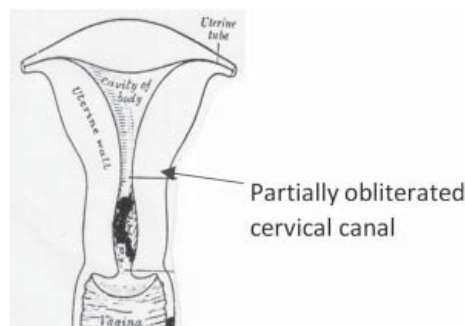


Fig 3. Cervical dysgenesis - c.

- d) the entire length of endo- cervical canal may be obliterated or may be completely fused with no cervical glands. (Fig 4).

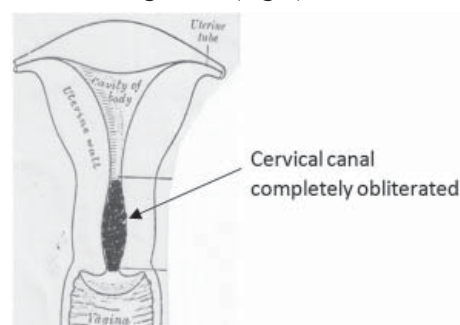


Fig 4. Cervical dysgenesis- d.

The body of cervix is replaced by cervical cord of variable

length and diameter with a completely obliterated endocervical canal (Fig -5).

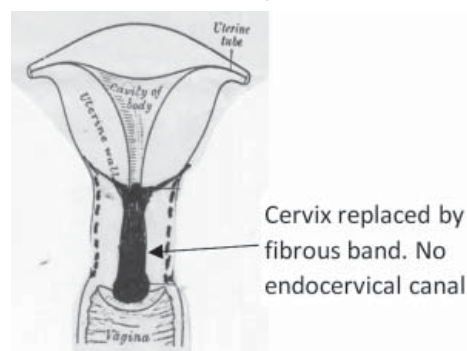


Fig -5. Cervix replaced with fibrous band

Fragmentation of the cervix is present which can be palpated below the body of the uterus (Fig 6).

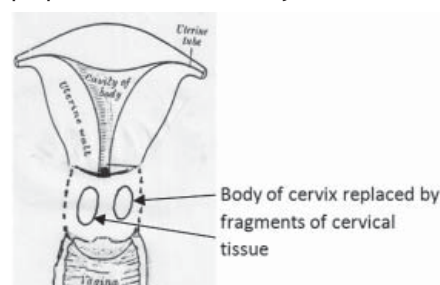


Fig 6. Fragmentation of cervix.

The commonest of these is cervical dysgenesis a,b,c and d (vide supra) and rarest is fragmented cervix.

Case Approach

Clinical Exam and Diagnosis

Due to its rarity, very few reported cases exist and hence their management is uncertain, several authors have described different techniques with varying success rates. We shall describe how to evaluate and investigate such patients and the different management options available.

Early diagnosis offers significant advantages in patient care, the most important of which is effective presurgical planning and preparation.

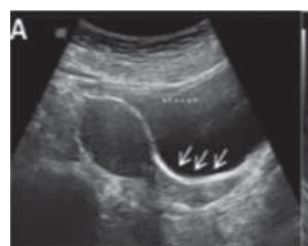The clinical presentation of patients with cervical dysgenesis/ agenesis in the majority of cases is primary amenorrhoea with cyclical abdominal pain. Cyclical pelvic pain in a pubescent girl must evoke the suspicion of an obstructive Mullerian anomaly. Pelvic endometriosis may result due to retrograde menstruation. Obstructive symptoms may be absent in cases of non-functioning endometrium.⁴ Clinical examination is helpful in ruling out other obstructive Mullerian anomalies like an imperforate hymen which appears as a bluish distension of the hymen or a blind vaginal pouch (seen in complete Mullerian agenesis). Sometimes an examination under anesthesia may be preferred in such girls as it may be difficult to examine them in a routine gynecological OPD. However clinically it is difficult to differentiate

between a high transverse vaginal septum and cervical agenesis. Obstructive uterovaginal anomalies with a functional endometrium require immediate attention because of the retrograde flow of trapped mucous and menstrual blood and increasing pressure on surrounding organs.²

Imaging

Several imaging tools have been used in the assessment of Mullerian duct anomalies. Ultrasound is the initial investigation of choice and this helps in defining the primary anomaly and in delineating the level at which the obstruction is present.⁵ (Plate I). Hematometra if present will also be seen on the ultrasound. Ovarian endometriomas and hematosalpinx can also be diagnosed on ultrasound. Three-dimensional ultrasound further improves our ability to accurately describe cervical anatomy though it requires operator expertise and adequate knowledge about the anatomical types. In addition to the Mullerian anomaly, ultrasound can also help in diagnosing renal anomalies which are seen frequently (up to 27 - 29%) in such patients.⁶ An IVP can help confirm a renal anomaly. Skeletal anomalies (e.g. scoliosis, vertebral arch disturbances, hypoplasia of the wrist) have been reported in 8-32% of patients therefore a spine radiography may reveal a skeletal anomaly even in asymptomatic women.⁷

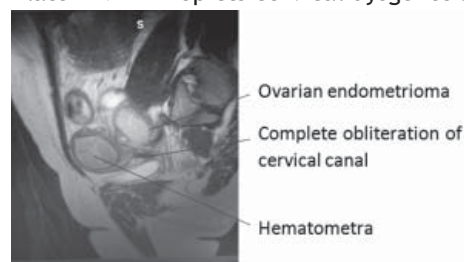
Plate I -USG (TAS) Cervical Obstruction



Magnetic resonance imaging (MRI) is considered the gold standard for definitive diagnosis and classification of genito-urinary anomalies, especially for complex cases (Plate II). MRI is a useful non-invasive tool for demonstrating pelvic anatomy and pelvic abnormalities. In suspected Mullerian anomalies, the uterus, vagina, gonads and associated pelvic lesions and renal abnormalities should be assessed.⁷

In women with cervical agenesis/ dysgenesis MRI is extremely helpful in deciding and preparing the patient for management.

Plate II MRI- Depicts cervical dysgenesis



Management

Management of cervical agenesis varies widely. Some surgical procedures will render the woman infertile as in the case of a hysterectomy but a uterovaginal anastomoses/ canalization may preserve fertility though success rates of such surgeries vary. As these anomalies are rare, emphasis must be on individualizing treatment to ensure the best possible outcome for the affected young woman.⁷

The goals of reconstructive surgery are

- To provide a passage for menstruation
- To relieve pain and obstructive symptoms
- To preserve reproductive potential

In the first group of cervical dysgenesis, cervical obstruction is the commonest finding. In all these cases where obstruction is partial or complete, reconstruction is associated with a better prognosis.

Pre-operative evaluation of precise defect will help in selecting the exact corrective measure to be taken.

If only the internal cervical ostium or the external cervical ostium is stenosed but the rest of the cervical canal is patent and there is no other anomaly either in the vagina or uterus, patient is examined under anaesthesia in lithotomy position. A Sim's speculum is introduced and the internal cervical os or external cervical os whichever is involved is probed with fine probe or fine dilator. After locating the ostium, the os is progressively dilated till at least 8-10 number dilators. In case of stenosis laminaria tent can be left in situ for at least one month. The upper end of laminaria tent should be at least 1cm above the internal os. The patient should be informed about the chances of expulsion of the laminaria tent and should be told to report to the hospital immediately. If no expulsion occurs she should report at the end of one month. In both situations the patient is re-examined to see whether the stenosis is corrected or not. In our experience the stenosis is relieved but there is a risk of recurrence hence patient needs to be kept under constant surveillance. In case patient has decreased menstrual flow and or dysmenorrhoea, cervical status should be re-examined and in case of re-stenosis, cervical dilatation should be repeated. In case laminaria tent is not available, cervix may be dilated with Karman's cannula, Foley's, silicone stent, or any hollow plastic stent of appropriate diameter to fit into os.

In case internal cervical ostium is fibrosed, surgical treatment is the same as for complete fusion of cervical canal.

Complete fusion of cervical canal

The reconstructive surgery is done as follows

Patient is placed in semi-lithotomy position with one assistant at the vaginal end. Under all aseptic precautions laparotomy is performed by either midline or transverse abdominal incision and uterus is opened

through its lower uterine segment and site of cervical canal is identified and probe is passed slowly and advanced through whole of the cervical canal. The assistant at vaginal end should be able to identify the probe once it has traversed the entire length of cervix. Now the cervical canal is slowly dilated. In case of normal cervix this is possible although it requires firm continuous pressure. It is dilated to atleast 8-10 number dilator.

Now any one of the options may be used to maintain patency of the cervical canal. One can insert a Karman's cannula, the distal end of this is cut and a Foley's catheter threaded through it (Fig 7). (Karman's cannula is shown in red in the figures to ease visibility). The two are then inserted into the cervical canal. The Karman's cannula is threaded till the incision made in the uterus and its upper end sutured to the inside of uterine cavity with delayed absorbable suture (Fig 8). Now the Foleys bulb is inflated to the desired level so that it is not expelled from the uterine cavity. The Foley's catheter is connected to urobag so that any discharge or menstrual blood is drained from the uterine cavity. The patient is examined at the end of every month to check the position of Karman's cannula or earlier in case of any complication like infection. This Foleys along with Karman's are left in situ for 3-6 months. Usually the Karman's Cannula which is fixed with delayed absorbable suture stays in situ for at least 3 months. Some surgeon's suppress the menstruation but the authors are of the opinion that healing and results are better if periods are not suppressed.

Slight modification of technique is desirable, in case there was immense difficulty in dilating the cervix or where coring was used to make the cervical canal, in both these circumstances, amnion graft or skin graft is used on the outside of Karman's cannula. It is seen that the graft takes well and prevents repeated reconstruction of the cervical canal. If amnion graft is used it is important to screen the donor for HIV and hepatitis B as per protocol. The authors are of the opinion that wherever there is doubt about the integrity of the cervical endothelium, amnion graft should be used. It is easy to be used by anyone and yields very good results. Nevertheless follow up of patient is important. The patient should be followed up every three months for first year and then seen every 6 months. Then annually till patient has had at least one normal reproductive outcome.

It is often found that complete fusion of cervical canal is associated vaginal agenesis in its upper one third. In this case space will have to be created in the upper part of vagina. A Foley's catheter with inflated bulb in the urethra and bladder and a finger in the rectum will prevent injury to these two important structures which are at potential risk of injury during the creation of potential vaginal space. Re-construction of the vagina may be done by skin graft or with amnion on mould as per the surgeon's preference. Sponge mould is used for successful take of the graft. Sponge mould is used

and covered with a condom, the upper end of which is cut to enable Foleys to pass through the cervical canal beyond the internal cervical ostium, to ensure drainage of the uterine cavity (Fig 9). The graft is normally taken up in 14- 21 days. The sponge mould is removed after 7 days and irrigation of the vagina is done by betadine. Fresh hard mould is inserted which needs to be changed frequently because of potential risk of infection. The Karman's cannula in the cervix is left in situ for 3-6mths so that the chances of re-fusion of cervix are minimised. Subsequent follow up of patient is same as described above for cervical dysgenesis a, b or c.

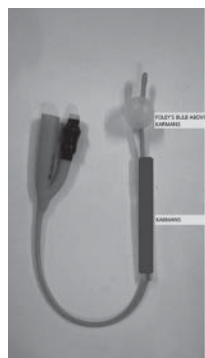

Fig 7. Foley's catheter with Karman's cannula outside

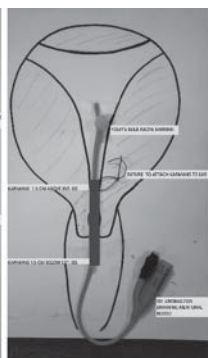


Fig 8. Karman's cannula fixed to lower part of inside of uterine wall

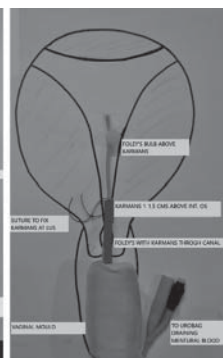


Fig 9. Reconstruction of cervix with vaginoplasty - vaginal sponge mould in situ

2. Cervical agenesis. Patients with complete cervical agenesis or cervical fragmentation are usually poor candidates for canalization and total hysterectomy may be a better option than a reconstructive surgery. Controversies do exist in the treatment options and some authors describe uterovaginal anastomosis as the first line of management.⁸ In case there is fibrous cord it should be removed or in case of agenesis, the atretic portion of the cervix is opened by coring or cutting and this part is stitched to the vagina. (Fig 10). However, a complete preoperative evaluation is essential to provide useful information about the remnant cervix which serves as the basis for assessing the risks and benefits of the possible procedures to be performed. Patient consent and in cases of minor girls, her parent's/ guardian's consent is vital to understand and explain the condition and chances of success and failure and future option of fertility.

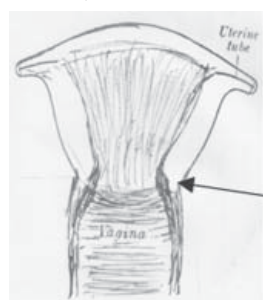


Fig 10. Utero-vaginal anastomosis

3. Fragmented cervix :If the fragments are extremely small, they are to be removed and patient treated as for cervical agenesis

If however, the cervical fragments are large then reconstruction of cervix can be attempted and treated as per cervical dysgenesis of first part described above (vide supra).

Experience of other authors: In 50% cases cervical agenesis is associated with vaginal atresia and it is difficult to make a satisfactory fistulous tract in these types of cases. Complications like endometritis, Pelvic inflammatory disease, persistent pelvic pain, bowel and bladder injury, re-obstruction, recurrent and severe pelvic infection, repeated surgeries and even death has been reported in the literature following reconstructive surgeries.⁸

In one of the largest series on reconstructive surgeries by Rock et al¹ wherein 30 cases were evaluated, success of reconstructive surgeries was documented in patients with cervical dysgenesis and all fourteen patients of cervical agenesis underwent hysterectomy. Literature does report a few cases of documented success of reconstructive surgeries. Several factors may influence the surgical outcome: the amount of cervical tissue present, the presence of an existing cervical canal, the size of created channel, the duration of stenting of the channel, the presence of rudimentary endocervical glands in the created channel and the duration between creating the anastomoses to planning pregnancy.⁹

Many methods of creating an anastomoses have been tried, most of them involving creation of a passage through the dense fibrous tissue between the uterine cavity and the vagina and placement of a stent to keep the tract open. Occasional successes in maintaining an open passageway and normal cyclic menstruation have been reported, but endocervical glands do not develop, and there is no way to compensate for the absence of the cervical mucus, which plays an important role in sperm transport.⁷ Even though cyclic ovulatory periods can be achieved in a few patients, pregnancy is unlikely. Eventually the uterovaginal tract may close from constriction by fibrous tissue. A few cases of construction of a splint that extended into the neocervical canal such that a split-thickness skin graft could actually be placed within the endocervical canal have also been reported.¹⁰

Kriplani et al¹¹ described 14 patients with congenital absence of uterine cervix. Laparoscopic assisted uterovaginal anastomoses with placement of a silicone stent was performed. McIndoe vaginoplasty was performed concomitantly in patients with vaginal agenesis. Cervical dysgenesis was present in 5 (35.7%) and cervical agenesis in 9 (64.2%). Mean follow up after surgery was 3.8 + 1.2 years. Post operatively, all but 1 patient experienced regular menses with relief of pain. One patient underwent hysterectomy because of genital infection and restenosis. The authors reported that 5 patients were sexually active and pregnancy was

reported in 3 of them. Kriplani attributes the use of the silicone stent in the neocervix until the resolution of inflammation as one of the reasons the incidence of restenosis was decreased in their population.¹¹

The surgical approach for the rare opportunity for cervical cannulation remains a challenge. Because of lack of data and the rarity of this entity, safety and efficacy of different surgical approaches is unclear and hence there is limited information to share with patients and families. Hence proper planning, counselling and pre operative preparation is important prior to embarking on such surgeries.

References

1. Congenital anomalies of the uterine cervix: lessons from 30 cases managed clinically by a common protocol. Rock JA, Roberts CP, Jones HWJ. Fertil Steril 2010; 34: 1858-1863
2. Congenital absence of the uterine cervix. Lakshmy SR et al. Int J Reprod Contracept Obstet Gynecol. 2016 Oct;5(10):3634-3636
3. Te Linde's Operative Gynaecology, Eleventh Edition, H. W. Jones III, John A. Rock, 505-506.
4. Update in Müllerian anomalies: diagnosis, management, and outcomes. Vallerie AM, Breech LL. Current Opinion in Obstetrics and Gynecology. 2010;22(5):381-7
5. Hysterosalpingography in the assessment of congenital cervical anomalies, Zafarani et al. Int J Fertil Steril 2017; 11: 71-78
6. Mullerian Agenesis: Diagnosis. Management and Treatment. ACOG Committee Opinion. Number 728. January 2018.
7. MR Imaging Diagnosis of Uterovaginal Anomalies: Current State of the Art. Sahar N, Saleem. Radiological Society of North America. Sept 2003
8. Cervical Agenesis: Two Case Reports with Review of Literature. Nayana P, Praveen M. Sri Lanka J of Obs Gyn. March 2014.
9. Surgical methods in the treatment of congenital anomalies of the uterine cervix. Roberts CP, Rock JA. Current Opinion in Obstetrics and Gynaecology 2011; 23:251-257
10. Laparoscopic management of cervical agenesis. Creighton S et al. Fertility and Sterility 2006; 85: 5
11. Laparoscopic-assisted uterovaginal anastomosis in congenital atresia of uterine cervix: follow up study. Kriplani A et al. J Minim Invasive Gynecol 2012 Jul-Aug

LIST OF PRIZES – AOGD CONFERENCE 2018

| | |
|--|------------------------------------|
| 1. Dr S N Mukherjee-Rotating Trophy | Best AOGD Monthly Clinical Meeting |
| 2. Research Paper-Best Competition Paper | Gold, Silver, Bronze |
| 3. Dr Batra's Medal-Winning Team of AOGD Quiz | Gold Medal |
| 4. Dr Neera Agarwal's Medal-Best Paper on theme topic of Obstetrics (Maternal Health) | Gold Medal |
| 5. Dr Neelam Bala Vaid's Medal-Best Paper on theme topic of Gynecology (Adolescent Health) | Gold, Silver |
| 6. Dr Suneeta Mittal's Medal-Population Stabilization | Gold Medal |
| 7. Dr U P Jha & Dewan Balakram's Medal (Best Presentation in Gynae Oncology) | Gold Medal |
| 8. Dr U P Jha & Raj Soni's Medal (Best Oral/Video/Paper Presentation in Endoscopy) | Gold Medal |
| 9. Mr. S Bhattacharya & Dr Ganguly's Medal-Free Paper competition Miscellaneous Category | Gold, Silver |
| 10. Poster Presentation | Gold, Silver |
| 11. Slogan Competition | First Prize, Second Prize |



Dr Ratna Biswas

Transplantation. 2018 Apr;102(4):569-577. doi: 10.1097/TP.0000000000002035.

Uterus Transplantation: A Rapidly Expanding Field

Brännström M, Dahm Kähler P, Greite R, Mölne J, Díaz-García C, Tullius SG

Uterus transplantation (UTx) has been successfully introduced as a treatment option for women with absolute uterine factor infertility (AUFI). AUFI representing approximately 3% to 5% of the female general population is linked to either congenital uterine agenesis (Mayer-Rokitansky-Küster-Hauser syndrome), major congenital uterine malformation (hypoplastic uterus, fraction of bicornuate/unicornuate uterus), a surgically absent uterus, or an acquired condition (intrauterine adhesions, leiomyoma) linked to uterine malfunction that causes implantation failure or defect placentation.

The world's first clinical uterus transplant was performed in 2000. However, a hysterectomy became necessary shortly after the surgery due to uterine necrosis.

In 2011, a group in Turkey reported on a surgically successful deceased donor transplant; however, this procedure has, to date, not resulted in a healthy live birth, the ultimate goal of UTx.

Building on an extensive experimental background in various animal models, including primates, the Gothenburg group led by Brännström reported on the first delivery of a healthy baby in a recipient of a live donor UTx in 2014. This event did not only show the feasibility of UTx, it also helped defining relevant areas of clinical and basic research. Use of a gestational surrogate carrier, is, at least in theory, an alternative for a woman with AUFI seeking genetic motherhood.

However, in the clear majority of countries worldwide, gestational surrogacy is not practiced based on legal, ethical, or religious concerns. Of note, the overwhelming majority of surveyed women in the United Kingdom, a country which permits surrogacy, preferred UTx over gestational surrogacy and adoption. Moreover, randomly selected women of fertile age in Sweden preferred UTx over gestational surrogacy. A recent large survey in Japan with more than 3000 participants revealed that UTx had a twofold higher acceptance rate compared with gestational surrogacy.

In a recent US survey exploring the potential of donating vascularized composite allografts, uterus donation achieved the highest priority. Thus, the acceptance of UTx as infertility treatment for women with AUFI is high, although the procedure remains in its infancy.

Editor's Comments

Uterine transplantation has created a new era in reproduction in women with absent uterus where the requirement of surrogate is bypassed. The procedure has come of age with technical advancement in obtaining a well vascularized graft with sufficient length of uterine vessels which are anastomosed to the external iliac vein of the recipient thus reducing the incidence of graft necrosis. Successful pregnancies have been reported thus introducing a ray of hope for child bearing in the recipient.

Int J Med Robot. 2017 Sep; 13(3): e182.

Outcomes in Patients Undergoing Robotic Reconstructive Uterovaginal Anastomosis of Congenital Cervical and Vaginal Atresia

Ying Zhang, Yisong Chen, Keqin Hua

Introduction

Congenital cervical atresia including cervical agenesis and cervical dysgenesis is a rare Mullerian abnormality of the female reproductive tract, first reported by Ludwig in 1900. The incidence is about one in every 80 000 to 100 000 births. It is known to be associated with both partial and complete vaginal aplasia and renal anomalies. It is defined as absent or aplasia of the cervix and characterized either by the absolute absence of any cervical tissue or by the presence of severely defected cervical tissue such as cervical cord or cervical fragmentation.

The diagnosis is made according to clinical symptom and sign, such as amenorrhea, cyclical abdominal pain and pelvic hematometra. Ultrasound and MRI (magnetic resonance imaging) are the two most important investigations for diagnosis. Differential diagnosis include high transverse vaginal septum and imperforate hymen.

There are several classifications of cervical atresia, including the Buttram classification, the American Fertility Society Classification of Mullerian Anomalies, Rock. Congenital uterine cervical anomalies, and ESHRE/ESGE classification.

The management of cervical atresia remains controversial because there are no guideline nor carefully designed cohort or randomized trials to support a best surgical practice. Till date total hysterectomy still offers numerous benefits and is supported as a treatment option by several authors. Uterovaginal anastomosis is the restoration of the genital tract by direct suturing of the isthmus uteri to the vagina. It offers an alternative for patients to maintain menstruation. However, the experience from reconstructive uterovaginal anastomosis is limited. Here, we report four cases of cervical atresia of ESHRE/ESGE classification C4V4 who underwent reconstructive uterovaginal anastomosis with SIS (small intestinal submucosa, SIS) graft by robotic surgery. The purpose of this particular paper is to review the surgical approach in four patients with cervical-vaginal agenesis, and to analyze their operative outcomes after 12 months.

Methods

Four patients diagnosed with cervical and vaginal atresia (C4V4;ESHRE/ESGE) were enrolled who underwent robotic assisted reconstruction of cervix and vagina by SIS graft in 2015. Written informed consent for the treatment was obtained from the patient and their parents. Before surgery, all patients were informed about potential risks and benefits of the intervention.

1. Clinical manifestation

MRI confirmed diagnosis of cervical and vaginal atresia. Two patients were classified as U3C4V4 according to ESHRE/ESGE classification, the other two patients were U0C4V4 (Figure 1).

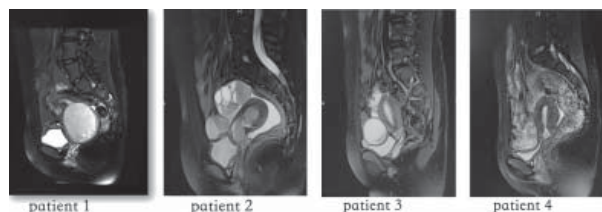


Figure 1: Magnetic resonance images of the four patients

2. Surgical procedures

On the day before surgery, all patients received a clear fluid diet and bowel preparation and prophylactic antibiotic therapy (cefotiam and ornidazole) was intravenously administered 30 min before the surgery. The same surgeon and surgical team performed all four procedures.

The Da Vinci robot was docked in a standard fashion at the foot of the bed, between the legs of the patient. Monopolar scissor and bipolar forceps were used to separate the adhesion and expos the uterus, ovaries and fallopian tubes.

The second stage was to open the peritoneum between the bladder and the lower segment of the uterus to separate the bladder and explore the lowest part of the uterus corpus and to verify the diagnosis of cervical atresia and the classification.

In the third step, we used monopolar scissors to open the lowest part of the haematometra and let the residual blood flow out. Meanwhile, the other surgeon created a neovagina by vaginal surgery. Three hundred millilitres of normal saline containing 2.0 mg of phenylephrine and methylthionium chloride (blue dye) was injected along the anatomical vaginal route between the bladder/the urethra and the rectum. During the injection, one finger of the operator was inserted in the anus, to ensure there was no injury to the rectum. And at the same time, a metal urinary drainage tube was inserted into the urethra and bladder to check for any outflow of the blue dye through the tube, to ensure no injury of the urethra or bladder. Then a midline incision at the vaginal introitus was made, and a 10 cm long, 3 cm wide canal was created using blunt dissection along the anatomical vaginal route. And the top of the canal was opened by monopolar scissors.

A 14-French Foley catheter was cut and connected with a Y-shaped intrauterine device (IUD) (Figure 2). The IUD was made of plastic and copper. The stem of the IUD was connected to the short catheter and inserted into the uterine cavity through the neovagina to keep the newly created cervix patent.

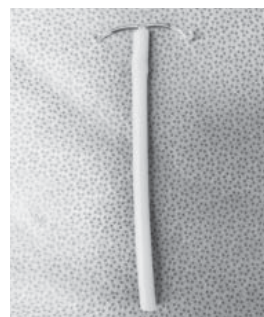

Figure 2: Part of 14-French Foley catheter connected with a Y-shaped intrauterine device

A 20*7 cm SIS graft (Surgisis, Cook Medical, Bloomington, IN, USA) was trimmed and sutured with 2/0 PDS II delayed absorbable material (Ethicon, Somerville, NJ, USA) to wrap around a 2.7 cm diameter and 10 cm long vaginal mould (Figure 3).



Figure 3: Silicone vaginal mould

Step 4 is anastomosis. A permanent lower uterine cerclage was performed with a Mersilene tape TM (Ethicon, Somerville, NJ, USA) by continuous suture. We put the graft into the neovagina and anastomosis with the incision of the lowest part of the uterus by continuous sutures using absorbable stitches. After anastomosis, a vaginal mould was then placed in the neovagina. The lower end of the graft was sutured to the vestibular mucosa.

7 days after operation the vaginal mould was exchanged and the neovagina was irrigated with 10% povidone-iodine.

Patients were instructed to wear the vaginal mould for about 12 months in succession. The IUD connected with the catheter was also recommended to be maintained for 12 months. Patients were assessed post-operatively every 3 months, the menstrual pattern and the morphological results of the neovagina were also recorded.

Results

All four patients recovered well and reserved their uterus after robotic surgery without any complication. Average operation time was 232.5 ± 89.2 min, average blood loss was 225.0 ± 95.7 mL (Table 1). Hospital days after surgery were 10 ± 1.4 . After surgery, all patients have regular menstruation without periodic pain. Average follow-up was 12 months, average vagina length was 8.9 ± 0.3 cm, vagina width was 2.9 ± 0.1 cm (Table 2). There was no re-admission.

Discussion

As a rare abnormality of the lower genital tract, cervical atresia with or without vaginal atresia is difficult both in diagnosis and treatment. MRI is the diagnostic gold standard.

Various methods of cervical reconstruction have been described in an attempt to create an epithelialized uterovaginal fistula to allow cyclic menstruation. However, many post-operative complications are observed. Traditionally, hysterectomy has been the preferred mode of treatment owing to the high rate of recurrent cervical obstruction and risk of infection. From our experience, we recommend the uterovaginal anastomosis as the first recommendation for all patients and epithelialization with a suitable graft of the neocervical canal.

In our study, all four patients underwent epithelialization with SIS graft. SIS graft is derived from the submucosal layer of pig small intestine that has been mechanically separated from the adjoining intestinal layers. It is one kind of extracellular matrix (ECM)-based collagen material. The graft is acellular and composed of noncross-linked collagen (types I, III and V), glycosaminoglycans, proteoglycans, glycoproteins and multiple growth factors. Studies have demonstrated tissue incorporation and epithelialization in Mayer-Rokitansky-Ku"ster-Hauser syndrome (MRKHS). The SIS is de-cellularized, biocompatible and does not produce an immunologic rejection response. It was reported to promote rapid growth and epithelialization of surrounding tissue. From the follow-up of the four patients, the neovagina and anastomosis part all epithelialized to different levels. No stenosis occurred.

Uterovaginal anastomosis can be performed by laparotomy, laparoscopy and robotics. After surgery, all the patients should wear the vaginal mould for about 12 months.

Clinical review every 3 months is recommended after surgery. Patients should take care of their volume of menstrual flow and if dysmenorrhea or periodic pain recur it is highly indicative of stenosis.

For patients with cervical atresia, uterovaginal anastomosis can maintain their menstruation and fertility potential. But successful pregnancy and delivery in a patient with congenital cervical atresia is a great challenge. Several factors may contribute to infertility in women with corrected cervical atresia, including deficient cervical mucus production, absence of functioning endometrium, hematometra formation, severe progressive endometriosis, and postoperative adhesive formation following surgical correction of the disorders. Anttila *et al.* reported successful pregnancy after IVF and transmyometrial ET in a patient who had failed cervical reconstructive surgery. After that, favorable pregnancy outcomes were described for different types of cervical agenesis and dysgenesis for women who underwent IVF, transmyometrial ET, transtubal ET, and spontaneously. The surgery of cervicovaginal anastomosis can provide patients with chances of spontaneous pregnancies. And before pregnancy and delivery, there are some potential obstetric complications patients must be counseled on, such as abortion, preterm delivery, cesarean section, uterine rupture, etc. In our study, all four patients were teenagers and we still need to follow-up their pregnancy outcomes.

Conclusions

Our study found that cervical atresia might be successfully treated by uterovaginal anastomosis under robotics. We recommend the ESHRE/ESGE classification of cervical-vaginal abnormalities. With appropriate evaluation and individualized management, we believe that a successful treatment and pregnancy outcome might be achieved.

Editor's Comment

Cervical atresia is more difficult to treat than dysgenesis. In cervical dysgenesis dilators are passed through the uterus which comes out through the lower end of the non canalized cervix creating a communication between the uterus and vagina. The passage is kept patent by inserting a catheter. Cervical atresia is more difficult to treat because of absence of cervix leading to a blind non communicating uterus. Uterovaginal anastomosis appears as a promising method to establish patency of the uterus and maintaining menstrual functions. Spontaneous conception may however be difficult and IVF procedures may be required. Pregnancy complications like recurrent abortions, preterm births, rupture uterus may occur.

Clinical Proceedings of AOGD Clinical Meeting held at VMMC and Safdarjung Hospital, New Delhi on 31st August, 2018

Postpartum Bladder Rupture: A rare case

Sana Tiwari, Vijay Zutshi, Renu Arora, Upma Saxena, Archana Mishra

A case of 23yr old P1L1 presented on PND12 of normal vaginal delivery with complains of retention of urine, acute abdominal pain, hypotension, tachycardia, tachypnoea. She had leucocytosis (18400/ cu mm), deranged KFT (128/ 3.6), ABG- metabolic acidosis and USG showing moderate ascites with internal septations. Patient was intubated and exploratory laparotomy was done after 24 hrs in view of post partum sepsis. Per operatively 1.5 ltrs of clear fluid was drained, uterus was intact, upper part of bladder was necrosed, and a rent was present in the anterior wall of bladder. Repair of bladder was done. In post operative period, urinary leak was present from the main wound. On POD 50 bilateral PCN was done with the plan of repair of bladder if leak continues after removal of PCN.

Conclusion

A patient who presents with retention of urine, ascites & deranged KFT after uneventful normal vaginal delivery, spontaneous bladder rupture should be suspected. Early diagnosis can decrease morbidity.

An Unusual Adnexal Mass in A Young Woman

Srividya, Monika Gupta, Sunita Malik, Saritha Shamsunder

A 27 year old unmarried women presented with signs and symptoms of torsion ovarian cyst. Her Ultrasound and MRI revealed right ovarian tumour measuring 10x9x8cm suggestive of ovarian torsion ? Dysgerminoma with lymphnode enlargement. She was subjected to staging laparotomy which revealed an irregular bosselated solid ovarian mass with paraaortic and unilateral lymph node enlargement. Per-operative scrape cytology of

ovarian tumour specimen showed features suggestive of dysgerminoma. But, the unexpected final diagnosis of Diffuse large B cell (non hodgkin's) lymphoma of ovary was made on histopathology and immunohistochemistry staining.

Conclusion

Primary ovarian lymphoma as initial manifestation is very rare accounting for 0.5% of all non hodgkin lymphoma and 1.5% of all ovarian neoplasms.

Ovarian involvement of lymphomatous process is very rare may mimic as more frequently occurring ovarian tumour like epithelial tumours. Most patients with primary ovarian non hodgkin's lymphoma may present with symptoms attributable to an ovarian mass which necessitates extensive surgical staging that is not mandatory for lymphomas. As a differential it must be considered as localised manifestation of systemic disease.

Hook Effect - Negative Point of Care: UPT IN GTD

Mily Pandey, Achla Batra, Sarita Singh

High levels of hCG can lead to false negative urine pregnancy test due to prozone phenomenon, which can lead to delay in diagnosis and can adversely affect the management of certain life threatening conditions like molar pregnancy, choriocarcinoma and other variants of GTN. This false negative pregnancy test in the presence of high levels of hCG is known as high dose hook effect. False negative urine pregnancy test can also be seen when isoforms of hCG are higher than intact hCG in urine, wherein, it is known as variant hook effect. Both the high dose and variant hook effect can be confirmed if testing shows a positive result after sample dilution. Various studies in literature have identified false negative urine pregnancy test in the presence of very high hCG levels and also with isoforms of hCG. High index of suspicion is needed for their timely diagnosis and treatment.



Royal College of Obstetrics & Gynaecology

AICC North Zone India

UPCOMING COURSES / CONFERENCE

Chairperson: Dr Nirmala Agarwal (n.menoky@gmail.com / 9811888732)

Vice Chairperson: Dr Anita Kaul

Hon. Secretary: Dr Arbinder Dang (arbidang@gmail.com / 9871356917)



RCOG UK FRANCHISED MRCOG: PART II REVISION COURSE

13th - 15th Dec 2018

COURSE FEE: Rs 35000/-

*Certificate of attendance for this course will be provided by the RCOG UK

Venue: Sant Parmanand Hospital,
18 Shamnath Marg, Civil Lines Delhi-110054,
INDIA

Course Convenor

- Dr Sanjeev Sharma (UK)
- Dr Nirmala Agarwal (India) – (n.menoky@gmail.com)
- Dr Sweta Gupta (India) – (swetagupta06@yahoo.com, 8130140007)
- Dr Jharna Behura – (jharnabehura@yahoo.co.in/ 9810247593)
- Dr Jasmine Chawla & Dr Shelly Arora

32ND ANNUAL CONFERENCE

Hotel Sheraton, Saket, New Delhi

Theme: Obstetrics & Gynaecology Evidence, Good Practice and Controversies

1ST & 2ND NOVEMBER, 2018 PRE CONFERENCE WORKSHOPS

- BJOG Author Workshop • Urogynaecology Video Workshop
- Obstetric Emergencies Skill Based
- Reproductive Medicine - Clinical Update
- Feto-Maternal Medicine Workshop • Menopausal Wellness
- Perineal Repair Workshop • Preventing Still Births
- Training the USG Trainers FOGSI Workshop

3RD & 4TH NOVEMBER, 2018 CONFERENCE

(SCIENTI C PROGRAMME)

5TH & 6TH NOVEMBER, 2018 POST CONFERENCE WORKSHOPS (COMPREHENSIVE COLPOSCOPY COURSE)

MEET THE EXPERTS/ BREAKFAST SESSIONS

Vaccination in Pregnancy, Contraceptive methods and issues around the Menopause, IVF trends in UK, Laparoscopic ergonomics in Gynaecology

KEY NOTE ADDRESSES

High Risk Obstetrics, Operative Gynaecology, Paediatric/ adolescent's gynecological issues, Laparoscopy & hysteroscopy

GUEST LECTURES

Contraception, Cosmetic Gynaecology, MRCOG curriculum, Exams & latest developments/ RCOG audit & safety

ABSTRACT SUBMISSION FOR FREE-PAPERS / EPOSTERS OPEN ONLINE.

Submission deadline 15th September, 2018 12 category wise prizes to be won Golden opportunity to get best abstracts published in BJOG Supplement India 2019.

REGISTER AT www.aicccognzindia.com

SECRETARIAT

Rcog North Zone Office, OT Complex 3rd Floor, Sant Parmanand Hospital, 18 Shamnath Marg,
Civil Lines. Dehi-110054

Tel No – 91-11-23981260, 23994401-10 Ext 314 Email- rcogconference2018@gmail.com

Administrative Assistant Mr Asif Muniri +919560069925 / 9716801190

CENTRE OF EXCELLENCE IN GYNAEC LAPAROSCOPY

LEADING CONSULTANTS AT SUNRISE HOSPITALS



Dr Hafeez Rahman

Sr Gynaecologist & Laparoscopic Surgeon
Chairman - Sunrise Group of Hospitals



Dr Nikita Trehan

Sr Gynaecologist & Laparoscopic Surgeon
Managing Director - Sunrise Group of Hospitals



Dr Shuchita Singh

Consultant & Training Faculty
Sunrise Hospital-Delhi

Special Expertise

- ❖ Total Laparoscopic Hysterectomy, Any Size Of uterus
(We have record for 9.6 Kgs TLH done laparoscopically).
- ❖ Laparoscopic Myomectomy
- ❖ Any Size of Fibroids (We have the World Record for 6.5 Kg Fibroid removed laparoscopically).
- ❖ Laparoscopic & Hysteroscopic Fertility Enhancing Surgeries: - Isthmoecele repair.
- ❖ All Hysteroscopic Procedures like Hysteroscopic Myomectomy, Polypectomy, Septal Resection etc,
- ❖ Laparoscopic Oncosurgeries laparoscopic wertheims hysterectomy for CA cervix and CA endometrium,laparoscopic surgeries for CA ovary.
- ❖ Laparoscopic Sling Surgery for Nulliparous Prolapse.
- ❖ All Gynae Urological Surgeries : TVT, TOT
- ❖ Laproscopic Treatment of Fistulas/ Laparoscopic Vaginoplasty by Sunrise Method.
- ❖ Specialized Vaginal Surgeries: Sacrospinous Fixation, Vaginal Rejuvenation Surgeries
- ❖ Laparoscopic Sacrocolpopexy for Uterine Prolapse.

Also we now offer Emergency LAP Encerclage where in patient can be brought to Sunrise Hospital from the referring hospital & can be sent back after procedure for further care.

Training Courses Available :-

Basic Laparoscopic Orientation Training :- 3 Days

Basic Laparoscopic Hands On Training :- 15 Days

TLH Hands On Training :- 4 Days

Fellowship In Advanced Gynaec Laparoscopy :- 6 Months

For Training Enquiries please contact Ms.Sofia at +91-9810157410



SUNRISE HOSPITAL
experience • expertise • care


F-1 Kalindi Colony, New Delhi-110065, Tel: +91-11 48820000/ +91-98101 57410. E-mail:helpdesk@sunrisehospitals.in

Medtronic

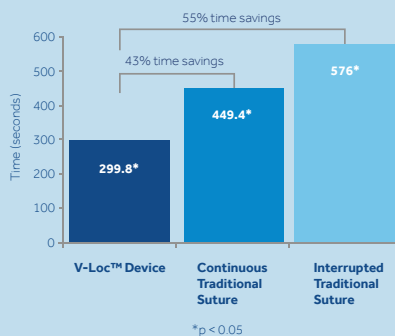
THE VLOC™ DEVICE ADVANTAGE

**NOW WITH
STRONGER,
SHARPER
NEEDLES***

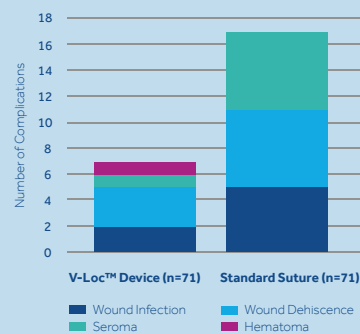
- Secure
- Fast
- Effective†



Closure Time for 9-Inch (23 cm) Incision¹



DIEP Flap Reduction in Overall Complications²



† When compared with traditional suture

1. Ramakrishnan, V. & Withey, S. Comparison of Wound Closure Time Using Conventional Techniques & Knotless, Self-Anchoring Surgical Sutures. St. Andrew's Centre for Plastic Surgery & Burns. Broomfield Hospital, Chelmsford, UK, 10.2011.
2. De Blacam et al. "Early Experience With Barbed Sutures for Abdominal Closure in Deep Inferior Epigastric Perforator Flap Breast Reconstruction" Presented at the New England Society of Plastic and Reconstructive Surgeons Meeting, Brewster, MA June 2011. Published: Eplasty.com, 5.2012.

*compared with previous generation

© 2016 Medtronic. All rights reserved.
16-emea-bbm16-booth-backwall-791377