



# AOGD BULLETIN

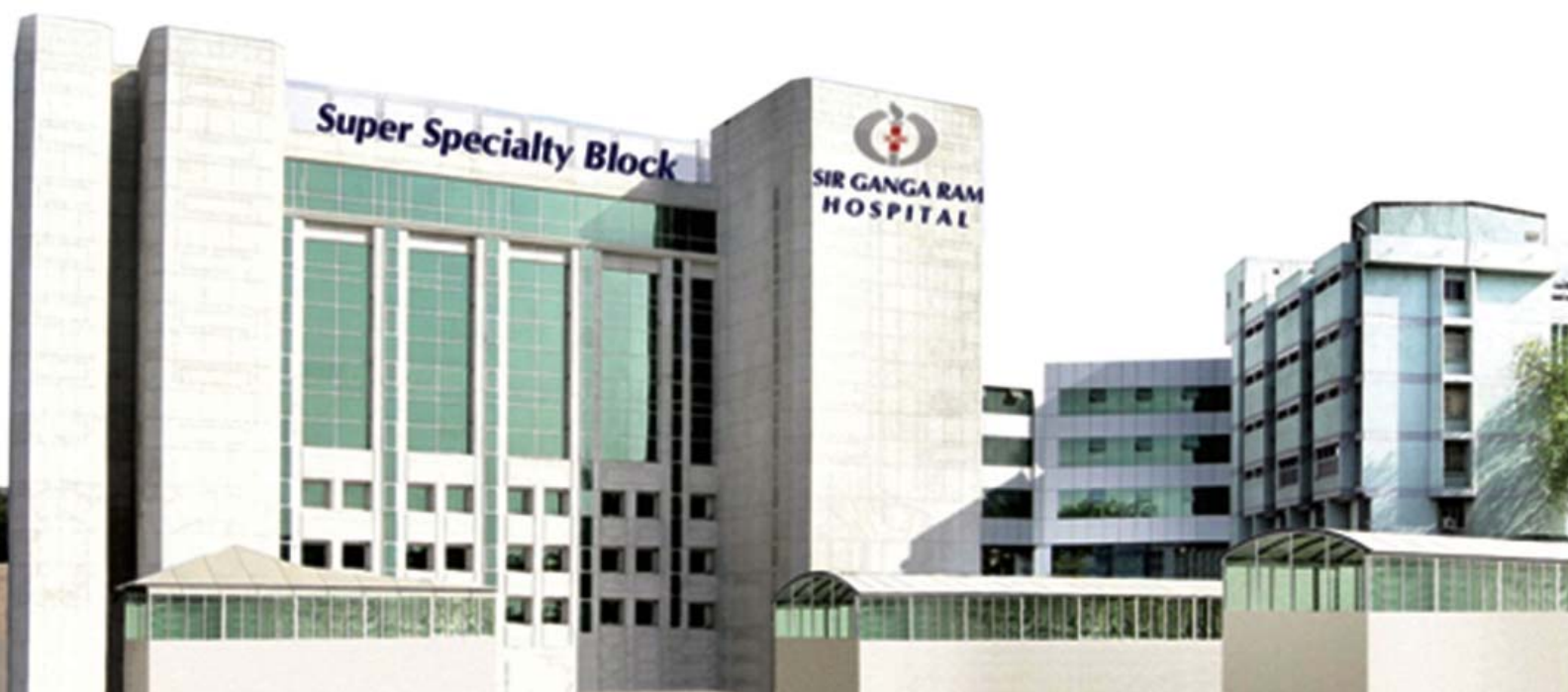Volume 20 | November 2020 | Monthly Issue 7

Price ₹30 Only



**CARING FOR WOMEN'S HEALTH :  
EVIDENCE, ATTITUDE & PRACTICE**

*Dedicated Issue:*  
**Minimally Invasive Gynecology**



## **AOGD SECRETARIAT**

Institute of Obstetrics & Gynaecology,

Sir Ganga Ram Hospital

Sarhadi Gandhi Marg, Old Rajinder Nagar, New Delhi-110060

Tel.: 011-42251768, 1789

E-mail: [secretaryaogdsgrh2020@gmail.com](mailto:secretaryaogdsgrh2020@gmail.com)

Website: [www.aogd.org](http://www.aogd.org)

## AOGD Office-Bearers 2020-21



**Dr Mala Srivastava**  
President



**Dr Kanika Jain**  
Vice President



**Dr Mamta Dagar**  
Hon. Secretary



**Dr Neeti Tiwari**



**Dr Sunita Kumar**



**Dr Shweta Mittal Gupta**  
Treasurer



**Dr Tarun Das**  
Co-Treasurer



**Dr Debasis Dutta**



**Dr Geeta Mediratta**



**Dr Chandra Mansukhani**



**Dr Punita Bhardwaj**

Scientific Advisors

## Editorial Board



**Dr Geeta Mediratta**



**Dr Chandra Mansukhani**

Editors



**Dr Ruma Satwik**



**Dr Sharmistha Garg**



**Dr Sakshi Nayar**



**Dr Ila Sharma**

Co-Editors



**Dr Debasis Dutta**



**Dr Gaurav Majumdar**



**Dr Ankta Srivastava**

Web Editors

# AOGD Bulletin

Volume 20 • Monthly Issue 7 • November 2020

## AOGD Executive Committee 2020-21

### President

Dr Mala Srivastava

### Vice President

Dr Kanika Jain

### Hony. Secretary

Dr Mamta Dagar

### Scientific Advisors

Dr Debasis Dutta  
Dr Geeta Mediratta  
Dr Chandra Mansukhani  
Dr Punita Bhardwaj

### Joint Secretaries

Dr Neeti Tiwari  
Dr Sunita Kumar

### Treasurer

Dr Shweta Mittal Gupta

### Co-Treasurer

Dr Tarun Das

### Editors

Dr Geeta Mediratta  
Dr Chandra Mansukhani

### Web Editor

Dr Debasis Dutta  
Dr Gaurav Majumdar  
Dr Ankita Srivastava

### Co-Editors

Dr Ruma Satwik  
Dr Sharmistha Garg  
Dr Sakshi Nayyar  
Dr Ila Sharma

### Finance Committee

Dr Abha Singh  
Dr Manju Puri  
Dr N B Vaid  
Mr Pankaj Jain (CA)  
Dr Pratima Mittal  
Dr Reva Tripathi  
Dr Shalini Rajaram  
Dr Sudha Prasad  
Dr Sunesh Kumar  
Dr U P Jha

### Executive Members

Dr Abha Sharma  
Dr Achla Batra  
Dr A G Radhika  
Dr Anita Sabharwal  
Dr Ashok Kumar  
Dr Asmita Rathore  
Surg. Cdr. Anupam Kapoor  
Dr Bela Makhija  
Dr Dinesh Kansal  
Dr Gauri Gandhi  
Dr Indu Chawla  
Dr Kiran Guleria  
Dr Malvika Sabharwal  
Dr Manash Biswas  
Dr Manju Khemani  
Dr Manju Puri  
Dr Neeraj Bhatla  
Dr Ranjana Sharma  
Dr Renu Mishra  
Dr Reva Tripathi  
Dr Rupali Dewan  
Dr Sangeeta Gupta  
Dr Sanjeevni Khanna  
Dr Shalini Rajaram  
Dr S N Basu  
Dr Suman Lata  
Dr Surveen Ghumman  
Dr Susheela Gupta  
Dr Usha Gupta

### Patrons

Dr B G Kotwani  
Dr I Ganguli  
Dr Kamal Buckshee  
Dr M Kochhar  
Dr Neera Agarwal  
Dr P Chadha  
Dr S K Bhandari  
Dr S N Mukherjee  
Dr Sheila Mehra  
Dr Suneeta Mittal  
Dr Swaraj Batra  
Dr Urmil Sharma  
Dr V L Bhargava

### Advisors

Dr A Majumdar  
Dr Alka Kriplani  
Dr Amita Suneja  
Dr Chitra Raghunandan  
Dr H Khullar  
Dr K Gujral  
Dr Pratima Mittal  
Dr S B Khanna  
Dr Sharda Jain  
Dr Shubha Sagar Trivedi  
Dr Sudha Prasad  
Dr Sudha Salhan

### Ex Officio

#### Executive Past Presidents

Dr P Chadha (1990-94)  
Dr Neera Agarwal (1994-97)  
Dr Maya Sood (1997-99)  
Dr D Takkar (1999-2001)  
Dr Sudha Salhan (2001-03)  
Dr Swaraj Batra (2003-05)  
Dr N B Vaid (2005-06)  
Dr S S Trivedi (2006-07)  
Dr Suneeta Mittal (2007-08)  
Dr I Ganguli (2008-09)  
Dr Shashi Prateek (2009-10)  
Dr U Manaktala (2010-11)  
Dr Neeraj Goel (2011-12)  
Dr C Raghunandan (2012-13)  
Dr Alka Kriplani (2013-14)  
Dr U P Jha (2014-15)  
Dr Pratima Mittal (2015-16)  
Dr Sudha Prasad (2016-17)  
Dr Shalini Rajaram (2017-18)  
Dr Abha Singh (2018-19)

#### Immediate Past President

(2019-2020)  
Dr Sunesh Kumar

#### Immediate Past Vice-President

(2019-2020)  
Dr Ashok Kumar

#### Immediate Past Secretary

(2019-2020)  
Dr Vatsla Dadhwal

### Chairpersons

#### AOGD Sub-Committees

Dr Manju Khemani  
Dr Manju Puri  
Dr Amita Suneja  
Dr Achla Batra  
Dr Kiran Aggarwal  
Dr Anita Rajorhia  
Dr Jyotsna Suri  
Dr Manisha Kumar  
Dr Reema Bhatt  
Dr Richa Sharma  
Dr Sushma Sinha  
Dr Kavita Aggarwal  
Dr Seema Prakash  
Dr Shashi Lata Kabra Maheshwari

## AOGD Secretariat

Institute of Obstetrics and Gynecology

Sir Ganga Ram Hospital

Sarhadi Gandhi Marg, Old Rajinder Nagar, New Delhi-110060

Tel.: 011-42251768, 1789

E-mail: [secretaryaogdsgrh2020@gmail.com](mailto:secretaryaogdsgrh2020@gmail.com) | [www.aogd.org](http://www.aogd.org)

## Contents

• From the President's Pen	4
• From the Vice President's Pen	5
• From the Secretary's Desk	6
• From the Editor's Desk	7
• Hysteroscopy - Newer concepts <i>Rahul Manchanda, Aayushi Rathore</i>	8
• Surgical Anatomy of Female Pelvis <i>Vedant Kabra, Jaiprakash Gurawalia, Pushpinder Gulia, Amit Sahni</i>	15
• Ergonomics of Laparoscopy <i>Praveen Bhatia, Aayushi Jain</i>	23
• Endometriosis - Diagnosis and overview of management <i>Kanika Jain, Debasis Dutta, Madhu Goel, Ashu Sharma</i>	27
• Laparoscopic Management of Endometriosis (Part 1) <i>Urvashi Prasad Jha, Neema Sharma, Mamta Mishra</i>	34
• Laparoscopic management of Deep Infiltrating Endometriosis (Part 2) <i>Urvashi Prasad Jha, Neema Sharma, Mamta Mishra</i>	40
• Surgical Approach to Adenomyosis <i>Punita Bharadwaj, Harshad Virani &amp; Puja Singh</i>	48
• Detail of 42 <sup>nd</sup> Annual e-Conference	57
• Cross Word Puzzle & Pictorial Quiz <i>Ruma Satwik</i>	61
• Journal Scan <i>Geeta Mediratta</i>	63

### Disclaimer

The advertisements in this bulletin are not a warranty, endorsement or approval of the products or services. The statements and opinions contained in the articles of the AOGD Bulletin are solely those of the individual authors and contributors, and do not necessarily reflect the opinions or recommendations of the publisher. The publisher disclaims responsibility of any injury to persons or property resulting from any ideas or products referred to in the articles or advertisements.

### Plagiarism Disclaimer

Any plagiarism in the articles will be the sole responsibility of the authors, the editorial board or publisher will not be responsible for this.

### Publisher/Printer/Editor

Dr Geeta Mediratta and Dr Chandra Mansukhani on behalf of Association of Obstetricians & Gynecologists of Delhi.

### Printed at

Process & Spot C-112/3, Naraina Industrial Area, Phase-1, New Delhi 110 028

### Published from

Institute of Obstetrics & Gynaecology

Sir Ganga Ram Hospital, Sarhadi Gandhi Marg, Old Rajinder Nagar, New Delhi-110 060

### Editors

Dr Geeta Mediratta

Dr Chandra Mansukhani

Ph. No. 011-42251768, 1789; Email: [secretaryaogdsgrh2020@gmail.com](mailto:secretaryaogdsgrh2020@gmail.com)

## From the President's Pen



Greetings to all the members of AOGD!

We had the privilege of organizing a very successful 42<sup>nd</sup> Annual Conference of AOGD and 1<sup>st</sup> e- Conference of AOGD. Our team AOGD from Sir Ganga Ram Hospital, had really worked hard. We were really happy that most of the members of AOGD were satisfied with the scientific content, versatility of speakers and command of the subject of the moderators and panelists in this e-conclave. If our hard work hard is appreciated we work with more enthusiasm and greater vigour.

The orations by our past president Dr. Sunesh Kumar, Dr. Alpesh Gandhi, our FOGSI President and Dr. S. Arulkumaran were highly appreciated by one and all. These orations were an eye opener and treat to our ears. The keynote addresses by eminent national and international speakers added glamour and glitter to the conference. The panel discussions on the burning topics of the day were highly sought for.

The post graduate activities were our main area of focus. It included Quiz, Slogan competition, free paper and poster competition. The e-learning was planned in such a way that we first concluded with our post graduate activities and then we began with eleven pre-conference and post conference workshops with the main annual conference in between. The competition papers are the most important segment of the annual conference and was nicely conducted by our senior judges of repute and experience. We are happy that all the planning and strategic distribution of this vast e-conclave was recognized, appreciated and became popular.

Hope this pandemic goes away soon. But it has taught us many new ways of conducting scientific activities and keeping ourselves upgraded by interactive yet distant learning.

Looking forward for brighter future for AOGD.

Long live AOGD!

**Dr Mala Srivastava**

President, AOGD

## From the Vice President's Pen



Greetings to all members of the association !

With a sense of great humility, privilege and responsibility, I would like to thank you all for the immense faith and trust bestowed upon me as this year's 'organizing co-chairperson' of the 42<sup>nd</sup> Annual and 1<sup>st</sup> E-Conference of AOGD.

Under the able leadership of Dr Mala Srivastava, along with the always helpful and complimenting organising secretary Dr Mamta Dagar, I shouldered this responsibility to the best of my capabilities.

The strength of our Association is Unity. With the Holistic efforts and guidance of our Seniors and the enthusiasm of our younger members, we were able to successfully hold and accomplish all the conference events spread out from 23<sup>rd</sup> October to 6<sup>th</sup> November 2020 on a flawless virtual platform. I'm grateful for the overwhelming participation and response shown by all our AOGDians and non-AOGD members Pan-India and across the globe in making this seemingly impossible task, a great success.

The fate of a Bulletin lies in submission of good quality Scientific material and prompt Editorship. Our expert Editorial team has brought out this November's E- Bulletin dedicated to 'Minimal Invasive Gynaecology'. I'm sure this exclusive Bulletin would be of great interest to the readers.

Here I would like to quote: "The strength of the team is each individual member. The strength of each member is the team." --Phil Jackson

Regards,

**Dr Kanika Jain**

Vice President, AOGD

## From the Secretary's Desk



Greetings to all! Hope you all are keeping safe and healthy.

On behalf of organizing committee of AOGD, I express by heartfelt and sincere thanks to all fellow AOGDIANS for making **42<sup>nd</sup> Annual Virtual AOGD Conference, 1st E-Conference, 2020** a majestic success. The overwhelming response shown by all our AOGD members, has really boosted our morale and given us the confidence and support that WE ALL TOGETHER CAN DO IT.

I am eternally grateful to all AOGD office bearers, my senior and junior colleagues for their unconditional and extended support in making and execution of this rich scientific programme. There were 800+ registrations, 163 free communication papers and 81 E-posters presentations.

The mammoth task of handling 11 pre and post conference workshops managed tirelessly was very well accomplished by Dr. Kanika Jain, Vice President AOGD and Workshops Convener of this Conference. All the workshops were a big hit and applauded by our senior AOGD members.

Our editorial team has brought the AOGD E-bulletin November version dedicated to **Minimally Invasive Gynecology**, which should be of great interest and immense use to our readers.

Looking forward to your continued support.

**Coming together is a beginning, staying together is progress and working together is success-Henry Ford**

Warm Regards

**Dr Mamta Dagar**

Hon. Secretary

### Monthly Clinical Meeting

AOGD Monthly Virtual Clinical Meet will be organised by MAMC & LNJP Hospital, New Delhi on 27<sup>th</sup> September, 2020 from 04:00pm to 05:00pm.



## From the Editor's Desk



**Dr Geeta Mediratta**  
Chief Editor

Now that we have hung up our boots after a thumpingly successful 42<sup>nd</sup> Annual Conference (1<sup>st</sup> E- Conference) held from 30<sup>th</sup> Oct. to 1<sup>st</sup> Nov. 2020 and other Conference activities ie E-Quiz & Slogan Competition, E-Competition papers, Free Communication papers, E-Posters & eleven Pre & Post Conference Workshops, we get ready for the 2<sup>nd</sup> half of our tenure as secretariat of the AOGD.

The current November 2020 bulletin is dedicated to **Minimally Invasive Gynecology** and features an updated & well researched article on '**Hysteroscopy-Newer concepts**' by Dr. Rahul Manchanda.

Dr. Vedant Kabra has very lucidly elaborated the anatomy of pelvis in his article entitled '**Surgical anatomy of female pelvis**'.

Ergonomics in Laparoscopic surgery is very important component but grossly neglected by all of us. Dr. Praveen Bhatia (Sr. MIS Surgeon) addresses this in his article entitled '**Ergonomics of laparoscopy**'.

Dr. Kanika Jain has lucidly elaborated the 'Endometriosis- '**Diagnosis and overview of management**'.

Dr. Urvashi Prasad Jha/ Dr. Neema Sharma have discussed the conundrums of '**Laparoscopic management of Endometriosis & Laparoscopic management of deep infiltrating endometriosis**' in exquisite detail in their articles, which has been divided into 2 parts.

Dr. Punita Bhardwaj has eloquently described all the '**Surgical techniques of dealing with adenomyosis**'.

The journal scan Source: JMIG of this issue deals with 2 interesting articles which were presented at the AAGL Annual conference in Nov. .

### 1. Social Media in Minimally Invasive Gynaecologic Surgery: What is #Trending?

This article demonstrates that most of the post on social media were shared by patients and misinformation was rampant. There was too much information or rather misinformation. Therefore physician involvement in social media may lead to improvement in patient education, physician-patient relationship, and knowledge in MIGS.

### 2. Laparoscopy in Pregnancy: A Primer

This article deals with the principle and techniques for safe and efficient laparoscopic surgery during pregnancy.

We welcome any suggestions from esteemed members.

Happy reading!

**Editorial Team**



**Dr Chandra Mansukhani**  
Co-Editor

# Hysteroscopy - Newer concepts

**Rahul Manchanda<sup>1</sup>, Aayushi Rathore<sup>2</sup>**

<sup>1</sup>HOD, Gynaecology Endoscopy Unit, PSRI Hospital, New Delhi, <sup>2</sup>Senior Resident, VMMC & Safdarjang Hospital, New Delhi

## Introduction

Hysteroscopy is the technique to visualize the uterine cavity with the aim to diagnose and treat intrauterine pathologies. The concept of endoscopy and looking into the body organs was first introduced by Bozzini in 1805.<sup>1</sup> This concept was further extended by Pantaleoni in 1869 who invented a hysteroscope to look inside the uterine cavity.<sup>2</sup> Ever since, hysteroscopy has improved substantially and increasing efforts have been targeted towards making it more patient friendly while maintaining its safety and effectiveness. Technological advancements in the field of hysteroscopy have paved the way to make it easily available to women and have to a great extent reduced the complications associated with it.

Today ambulatory resectoscopes are in vogue which has the main aim to reduce the trauma, pain, complications, stigma and cost associated with the procedure and to minimize the duration of procedure thereby offering better hysteroscopy experience to patients in an outpatient setting.

With newer developments in technique and technology, hysteroscopy is now being considered an extension to the clinical examination and an aid to make rapid and accurate diagnosis with minimal patient discomfort, by direct visualization of the pathology. It has also widened the horizons of operative hysteroscopy by enabling 'see and treat' approach for concomitant treatment of intrauterine pathologies at the same time, thus increasing patient compliance.

Truly we have taken giant steps towards Professor Bradeley's slogan of "My hysteroscope is my stethoscope"

## A. Advances in hysteroscopes

Earlier, hysteroscopy was performed using speculum, cervical tenaculum and large diameter hysteroscopes. The traditional hysteroscopes have an outer diameter of 26-27Fr gauge (8.7 to 9 mm). Cervical dilatation is needed for its introduction which makes the procedure painful

and uncomfortable and warrants the need of anesthesia. To reduce these difficulties, narrow diameter resectoscopes are designed to facilitate easy entry inside the uterine cavity using vaginoscopic approach.

The most common indications of performing hysteroscopy have been abnormal uterine bleeding, infertility, uterine anomalies, Asherman syndrome and recurrent pregnancy loss. With the advances made in the context of office hysteroscopy and the use of mini resectoscopes, this list has increased to encompass endometrial polypectomy, endometrial ablation, intracervical polypectomies, grasp or punch biopsy and isthmocoele correction.

## 1. Mini resectoscopes

A few innovations in the field of mini-resectoscopes are as follows:

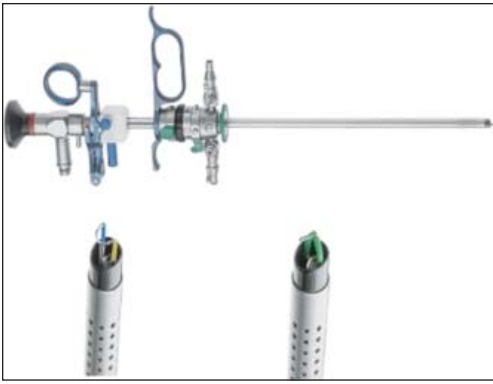
**a. Princess resectoscope (Richard Wolf GmbH, Knittlingen, Germany):** It is a narrow diameter resectoscope (7mm) with the advantage of having a double rotating sheath system. The inner sheath can be rotated 360° while the outer sheath remains stationary allowing increased freedom of movement inside the uterine cavity and works with both monopolar as well as bipolar energy sources.<sup>3</sup> (Figure 1 )



**Figure 1:** Princess resectoscope (Richard Wolf GmbH, Knittlingen, Germany)

**b. Accardi's 18.5Fr hybrid mono/bipolar mini resectoscope:** This mini-resectoscope is made of titanium which is similar to the princess resectoscope and works on rotating mechanism. It can be used either with a cutting loop or with a cold knife and has a hybrid technology so it can be used with both monopolar and bipolar energy sources.<sup>3</sup> (Figure 2)



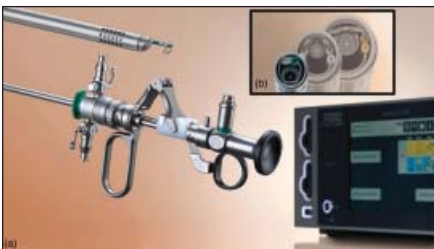

**Figure 2:** Accardi's 18.5Fr hybrid mono/bipolar mini resectoscope

**c. Versapoint 16Fr mini resectoscope: (Karl Storz SE & Co.KG, Tuttlingen, Germany):**

It is a new bipolar vaporization system with an even reduced outer diameter of 16Fr (5.3 mm) and can be used for both diagnostic and operative hysteroscopy in cases of endometrial polyps, submucous fibroids and uterine septa. Its narrow diameter makes it even more beneficial in office settings since it obviates the need for anaesthesia and can be inserted using no touch vaginoscopic approach without cervical dilatation. It comes with a non-disposable sheath which can be reused and hence it is cost efficient. It has a 90° loop which is better for cases requiring tissue retrieval and plasma formation allows self-cleaning of loops to enhance the vision of surgeon.

Since it uses bipolar energy, it can be used with normal saline (distension media) which reduces the risk of fluid overload. But it requires a dedicated electrosurgical generator for bipolar energy (Autocon III 400 HF generator (Karl Storz SE nad Co.KG, tuttilinen, Germany)) which adds on to the equipment cost.<sup>3,4</sup> (Figure 3)



**Figure 3:** (a) 16 Fr mini resectoscope (Karl Storz SE & Co. KG, Tuttlingen, Germany). (b) focus on size difference of 16, 26 and 27Fr tips.

**d. The GubbiniV R Mini Hystero-Resectoscope (GUBBINI system; Tontarra Medizintechnik, Tuttlingen, Germany):**

This is a continuous flow, operative office resectoscope made of titanium which has a double sheath (inner diameter 14Fr and outer diameter 16Fr). It is an atraumatic, easy to insert resectoscope. It can be used with both monopolar and bipolar energy. The advantage over versapoint bipolar system is that it comes with an oblique tip and hence the electrode is optimal for cutting and moreover no dedicated electrosurgical unit required for its use so it is more cost efficient.<sup>5</sup> (Figure 4)

The latest version has further decreased the total assembly size to 14.5F making it even lesser traumatic.



**Figure 4:** (a) The GubbiniV R Mini Hystero-Resectoscope (GUBBINI system; Tontarra Medizintechnik, Tuttlingen, Germany) (b) elliptic formed tip for easy introduction in cervical channel

## 2. Portable hysteroscopes

Classically, hysteroscopy unit comprises of stack systems with space for monitors, camera and light source which makes it a bulky and space occupying apparatus. Therefore hysteroscopy has to be performed in dedicated rooms like operation theatres in majority cases. To make this procedure more ambulatory, attempts are increasingly being made to make it more compact and portable with image storing capacity thereby facilitating its ready availability in smaller clinics and outpatient settings.

**a. Endosee office hysteroscope:** It is a handheld, battery operated portable hysteroscopy system with a touch screen display screen of 3.5 inches at one end and the camera and light source at the tip. Fluid is delivered through a separate intravenous standard bore extension

tubing connected with cannula. It comes with a disposable cannula and flexible cannula of 5mm.<sup>3</sup> (Figure 5)

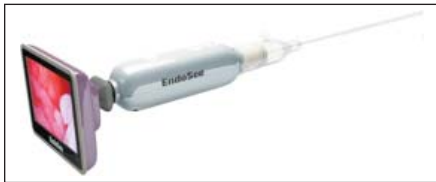

Figure 5: Endosee office hysteroscope

- b. Tele Pack X LED (Karl Storz SE & Co.KG, Tuttlingen, Germany):** It is an all in one diagnostic and operative system with an integrated LED light source, 15 inch LED display and camera control unit which are required for optimal endoscopic imaging. It also has the ability to store videos on USB port or SD card.<sup>6</sup> (Figure 6)

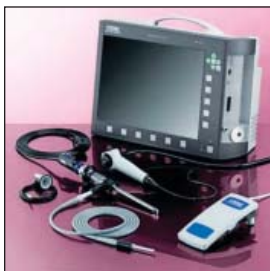

Figure 6: Tele Pack X LED (Karl Storz SE & Co.KG, Tuttlingen, Germany)

- c. UBIPack GYN (SoproComeg, La Ciotat cedex, France):** It is a portable device which has a low power charge coupled device camera that can be directly connected to a laptop or computer. It can be used with both rigid and flexible hysteroscopes and thus is used for both diagnostic and operative hysteroscopy.<sup>6</sup> (Figure 7)

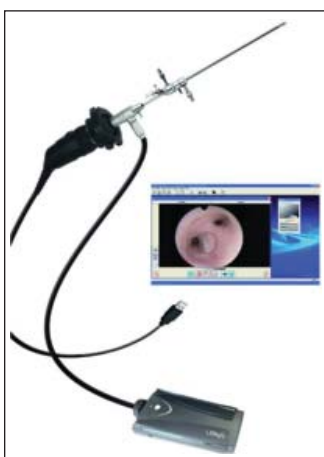


Figure 7: UBIPack GYN (SoproComeg, La Ciotat cedex, France)

## B. Advances in the instrumentation

Besides hysteroscopes, steps have been taken to develop miniature mechanical instruments which are simple and easy to use with a short learning curve and to make them more precise and safe resulting in reduced risk of uterine perforation and trauma to the surrounding endometrium.

- 1. Vitale biopsy snake forceps:** It is an innovative hysteroscopy grasper which is characterized by a sleeve with an opening along the whole width and a flat pointed tip with serrated edges fixed by a U-shaped joint. It has two sharp edged jaws used for cutting and it completely encompasses this pointed tip when clenched. The sleeve has a handle which opens and closes these jaws. The grasper is made of stainless steel and can be sterilized and reused. It is introduced through the working channel of the hysteroscope. When the jaws open, the pointed tip gets exposed and penetrates the tissue using a pulling and anchoring action of the serrated edges of the pointed tip. The tissue is grasped and resected using the sharp edges of the two jaws.<sup>7</sup> (Figure 8)

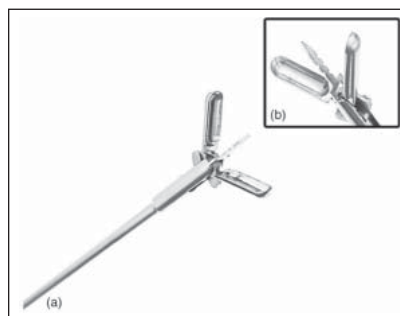
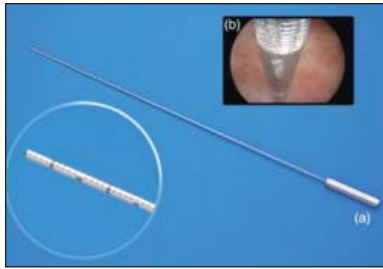


Figure 8: (a) Biopsy snake grasper (b) detailed view of the terminal end of the grasper.

- 2. The Karl Storz graduate intrauterine palpator (Karl Storz SE & Co.KG, Tuttlingen, Germany):** It has been developed with the aim to minimize the risk of perforation and excessive myometrial thinning during resection leading to improvement in the precision of hysteroscopic metroplasty. It measures the length of the uterine cavity, cervix, and the resected septum due to calibration. It is available in 5Fr diameter and is compatible with the operating channels of all modern day hysteroscopes.<sup>3,6</sup> (Figure 9)



**Figure 9:** (a) The Karl Storz graduate intrauterine palpator (Karl Storz SE & Co.KG, Tuttlingen, Germany). (b) endoscopic view of palpator inside the uterine cavity showing 1cm of resected uterine septum.

### C. Advances in tissue retrieval systems:

Tissue retrieval poses a major challenge to the operating surgeon as the resected tissue obscures the view of operating surgeons. Graspers and forceps which have been traditionally used for this purpose have to be repeatedly removed and reinserted into the cavity to remove this tissue, which can cause cervical trauma or even uterine perforation.

Tissue retrieval systems which causes morcellation of the intrauterine pathology have been devised which are equipped with the technology to simultaneously irrigate the uterine cavity and suction of tissues to maintain clear view of the uterine cavity and reduce the risk of trauma.

1. **TruClear™ Elite Hysteroscope (Medtronic INC, Minneapolis, USA):** This is the first generation hysteroscopic mechanical morcellator with continuous irrigation and suction mechanism. It causes minimal thermal damage to the surrounding endometrium and is FDA approved in 2005. It is optimal for office hysteroscopy because of narrow diameter and is used for morcellation of polyp, fibroid and removal of other intrauterine pathologies.<sup>3,6</sup> (Figure 10)




**Figure 10:** (a) TruClear™ Elite Hysteroscope (Medtronic INC, Minneapolis, USA). (b) focus on the available blade shapes.

2. **Myosure tissue retrieval system (Hologic, Marlborough, USA):** This is a second generation office tissue retrieval system used for removal of endometrial polyps, fibroids and other intrauterine pathologies. It morcellates the tissue by electronically driven rotating morcellator blade along with simultaneous removal of resected tissue by aspiration.<sup>8</sup> (Figure 11)



**Figure 11:** Myosure tissue retrieval system (Hologic, Marlborough, USA)

3. **Integrated Bigatti Shaver (IBSV R) (Karl Storz SE & Co.KG, Tuttlingen, Germany):** This is a rigid shaving system which is introduced through the operating channel of hysteroscopes and it consists an inner tube which rotates inside the outer tube and is connected to a handheld motor unit. The resected tissue is simultaneously suctioned out to maintain a clear view of the uterine cavity. It is optimal to use under office settings by vaginoscopic approach and is much faster than the other available tissue retrieval systems and has a faster learning curve for surgeons. It is comparatively safer to use due to less complications and causes less damage to the surrounding endometrium.<sup>6,9</sup> (Figure 12)



**Figure 12:** (a) Integrated Bigatti Shaver (IBSV R) (Karl Storz SE & Co.KG, Tuttlingen, Germany). (b) focus on the available blades and electrodes.

#### D. Advances in fluid delivery systems

To begin with, contact hysteroscopes were used to peep into the uterus which were traumatic and led to obscuration of view by blood, mucus and debris. Hence, the need to distend the uterine cavity was realized and numerous attempts were made worldwide to search for an ideal distension media.

The distension media included both gaseous media like CO<sub>2</sub> and fluid media. Mechanical distension was also attempted using balloon distension of the uterine cavity. Among these, distension using fluids became the most popular and accepted method and still continues to be one. It was however reported by some authors that retrograde spill of fluid through the fallopian tubes into the intraperitoneal cavity can lead to spread of infections and its systemic absorption can cause fluid overload.

The need to maintain adequate intrauterine pressure (for adequate distension) and flow (to prevent obscuration of view by blood, mucus and debris) was recognized as well as the need of calculation of fluid deficit to prevent fluid overload. This led to all efforts being towards development of an ideal fluid delivery system which can serve all the above purposes. Some recent developments in fluid delivery systems are as follows:

1. **Mounir's pumpino (hsyteromat):** It is a low cost, simple to use fluid delivery system ideal to use in office settings. It has a controlled rate of fluid delivery @100-500mL/min with the preset pressures in the range of 20-450mmHg and working pressure of 0-25mmHg to prevent fluid overload. However, it does not display the fluid deficit in real time.<sup>3</sup> (Figure 13). It is extremely handy and portable, especially suited to true office hysteroscopy and mobile endoscopic surgeons.



Figure 13: Mounir's pumpino- office hysyteromat

2. **The Hysteroflow IIV R (Olympus Winter & Ibe GmbH, Hamburg, Germany):** This automatic fluid delivery pump, introduced in 2013, delivers fluid at maximum flow rate of 500mL/min and maintains the intrauterine pressure below 150mmHg to prevent fluid intravasation. Additionally, it displays the fluid deficit in real time and is equipped with an alarm system to alert the operating surgeon when this deficit exceeds.<sup>10</sup> (Figure 14)



Figure 14: Hysteroflow IIV R (Olympus Winter & Ibe GmbH, Hamburg, Germany)

3. **AquilexV R fluid management system (Hologic, Marlborough, MA, USA):** This automated fluid delivery system, introduced an year later in 2014, delivers fluid at with the maximum flow rate of 800mL/min (more than the hysteroflow system) with maximum pressure setting of 150mmHg and additionally has a safety threshold preset levels at 100mmHg. It is also equipped to calculate the fluid deficit based on volume. However, its main drawback is the need to interrupt the procedure for the change of canisters and bags.<sup>10</sup> (Figure 15)

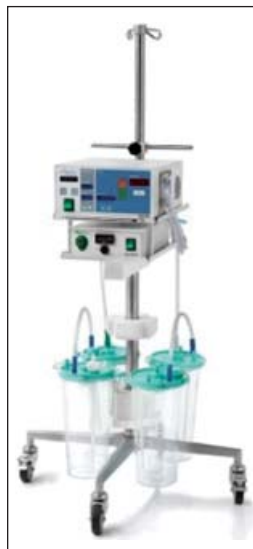

Figure 15: AquilexV R fluid management system (Hologic, Marlborough, MA, USA)



4. **HysteroluxV R fluid management system (Medtronic INC, Minneapolis, MN, USA):**

Very recently in 2018, another fluid delivery system has been developed with all the advantages of AquilexV R system with the additional advantage that it can continue to work when bags and canisters are being changed and the procedure can continue without any pause.<sup>10</sup> (Figure 16)



**Figure 16:** HysteroluxV R fluid management system (Medtronic INC, Minneapolis, MN, USA)

5. **The Hysteromat E.A.S.I V R (Karl Storz Endoscopy GmbH, Tuttlingen, Germany):**

This is the most commonly used system worldwide nowadays. It is a 'smart' system with pressure-controlled double roller pump and comes with four preset modes: *hysteroscopy*, *resectoscopy*, *laparoscopy*, and *shaver mode*, to be selected at the start of the procedure according to the sheath being used. The intrauterine pressures for each are memorized in the system (can also be adjusted manually for better control). There is an additional option of *blood/mucus mode*, which enhances the flow and suction of fluid to clear the intrauterine cavity for better visualization. Additionally, it also has



**Figure 17:** The Hysteromat E.A.S.I V R (Karl Storz Endoscopy GmbH, Tuttlingen, Germany)

a *bimodal instrument mode* to keep the intrauterine pressure constant even when the inflow diameter is less. (Figure 17)

E. **Advances in procedure**

1. **LeonardoV R laser system (D.w.L.S.; LeonardoV R, Biolitec, Jena, Germany):**

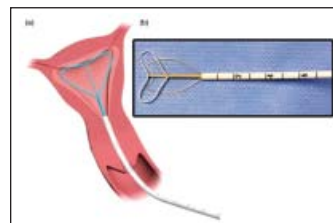
Diode lasers are the most commonly laser for intrauterine pathologies in the present times. The laser beam is generated and reaches the surgical site through the optical fibre and optical system. The advantage offered by laser is that it can be used in difficult to reach areas of uterus (like near the cornua) where resection using traditional instruments can be difficult to achieve and requires a lot of manipulation. It also provides good hemostasis causes precise tissue cutting. It works by drying and dehydration of the tissues which causes reduction in tissue volume so that it can be easily removal through the os and thus improves patient tolerability and compliance. There is controlled tissue penetration and absent electrical interference when laser is used for tissue resection. However, the main disadvantage of using diode laser is that it is costly and a good learning curve required to use it.<sup>11</sup>

F. **Advances in endometrial ablation**

Endometrial ablation is beneficial in patients with abnormal uterine bleeding and is usually performed under anesthesia. However, recently developed endometrial ablation devices have made this procedure safe to be performed under office settings with minimal complications.

1. **The MiniTouch endometrial ablation device (MicroCube, Fremont, CA, USA):**

With this device endometrial ablation is performed using microwave energy delivered by an intrauterine device placed inside the uterine cavity.<sup>6</sup> (Figure 18)

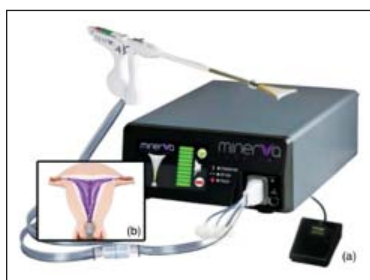

**Figure 18:** (a) The MiniTouch endometrial ablation device (MicroCube, Fremont, CA, USA). (b) focus on the intrauterine array.

## 2. The Minerva Endometrial Ablation System (MinervaSurgical, Redwood City, CA. USA):

This system has been approved by FDA in 2015 for AUB. It causes thermal ablation of endometrium by the following three mechanisms:

- **Hot array membrane:** The plasma releases thermal energy which causes ablation of tissue in direct contact with the silicone array membrane.
- **Heated intra-cavitary fluids:** The retained heated cavity fluids cause ablation of tissues which are not in direct contact with the silicone array membrane
- **RF energy:** Ablation is caused with penetrating bipolar RF energy which also creates plasma by ionizing argon gas contained in the silicone array membrane.<sup>3,12</sup> (Figure 19)



**Figure 19:** (a) The Minerva Endometrial Ablation System (MinervaSurgical, Redwood City, CA. USA). (b) endometrial ablation mechanism by means of argon gas ionization.

## Conclusion

Hysteroscopy is the gold standard investigation for diagnosis and treatment of a variety of intrauterine pathologies. Technological innovations have widened the horizons of hysteroscopic procedures and have enabled its easy accessibility and acceptability among a larger proportion of women. At the present with office hysteroscopy it is now possible to treat almost all the intrauterine pathologies in outpatient settings. However, with continuous progress and refinement of instruments and methodology even today, the future possibilities of uses of hysteroscopy remains unlimited. Newer vistas have been added with Narrow Band imaging, office resectoscopy, safer hysteromats, and artificial Intelligence (AI) which has made intrauterine surgery a better experience both for the surgeon and patient.

## References

1. Bozzini's clinical treatise on endoscopy: a translation. Q Bull Northwest Univ Med Sch.1974;23:332–354. Originally published, in German, as: Bozzini P. Der Lichtleiter oder die Beschreibung einer einfachen Vorrichtung und ihrer Anwendung zur Erleuchtung innerer Höhlen und Zwischenräume des lebenden animalischen Körpers. Weimar, Germany: Landesindustriecompoirs; 1807.
2. Pantaleoni DC. On endoscopic examination of the cavity of the womb. Med Press Circular. 1869;8:26–27.
3. Sharma R, Vitale SG, Riemma G, Manchanda R. Innovations in hysteroscopy. Sharma R, Manchanda R et al. Stepwise Access to Hysteroscopy, 1st ed. India: CBS Publishers & Distributors; 2020 :63-75. ISBN: 978-93-89688-53-5
4. Papalampros P, Gambadauro P, Papadopoulos N, et al. The mini-resectoscope: a new instrument for office hysteroscopic surgery. Acta Obstet Gynecol Scand. 2009; 88(2):227–230.
5. Dealberti D, Riboni F, Prigione S, et al. New mini-resectoscope: analysis of preliminary quality results in outpatient hysteroscopic polypectomy. Arch Gynecol Obstet. 2013;288(2):349-353. doi:10.1007/s00404-013-2754-7
6. Vitale SG, Haimovich S, Riemma G, et al. Innovations in hysteroscopic surgery: expanding the meaning of “in-office” [published online ahead of print, 2020 Jan 23]. Minim Invasive Ther Allied Technol. 2020;1-8. doi:10.1080/13645706.2020.1715437
7. Vitale SG. The Biopsy Snake Grasper Sec. VITALE: A New Tool for Office Hysteroscopy. J Minim Invasive Gynecol. 2019. doi: 10.1016/j.jmig.2019.12. 014.
8. Connor M. New technologies and innovations in hysteroscopy. Best Pract Res Clin Obstet Gynaecol. 2015;29(7):951-965. doi:10.1016/j.bpobgyn.2015.03.012
9. Bigatti G, Ansari SH, Di W. The 19 Fr. Intrauterine Bigatti Shaver (IBS(R)): a clinical and technical update. Facts Views Vis Obgyn. 2018;10(3):161–164
10. Manchanda R, Valenti G, Rathore A, Carugno J, Török P, Riemma G, Angelis MCD, Angelos GA Vilos, Pacheco LA, Vitale GS. Distension media delivery systems in hysteroscopy: past, present and future. Minim Invasive Ther Allied Technol. 2020;5. https://doi.org/10.1080/13645706.2020.1763402
11. Nappi L, Sorrentino F, Angioni S, Pontis A, Litta P, Greco P. Feasibility of hysteroscopic endometrial polypectomy using a new dual wavelengths laser system (DWLS): preliminary results of a pilot study. Arch Gynecol Obstet. 2017;295(1):3-7. doi:10.1007/s00404-016-4232-5
12. Scordalakes C, delRosario R, Shimer A, Stankiewicz R. Efficacy and patient satisfaction after NovaSure and Minerva endometrial ablation for treating abnormal uterine bleeding: a retrospective comparative study. Int J Womens Health. 2018;10:137-145. Published 2018 Apr 18. doi:10.2147/IJWH.S153699



# Surgical Anatomy of Female Pelvis

Jaiprakash Gurawalia<sup>1</sup>, Pushpinder Gulia<sup>2</sup>, Amit Sahni<sup>3</sup>, Vedant Kabra<sup>4</sup>

<sup>1</sup>Associate Consultant, <sup>2</sup>Senior Consultant, <sup>3</sup>Specialist, <sup>4</sup>Head of Department  
Department of Surgical Oncology, Manipal Hospitals, Sector-6, Dwarka, Delhi

## Introduction

Surgery is essentially the practical application of anatomical knowledge which facilitates better execution of operative procedure and minimizes its morbidity and mortality. Gynaecological surgeries extend from local excision to radical procedures and a thorough knowledge of pelvic anatomy helps in achieving the required outcome.

There are different approaches to female pelvic anatomy for gynecological, urogynecological, and onco-gynecological operations. We describe anatomy of pelvic spaces, vessels, nerves and ureter that would be helpful in all of these.

## Sacral Promontory

Sacral promontory, the entry gate of pelvis, is the most prominent as well as easily identified structure and thus forms a fixed reference point in patient with scarred anatomy. The level of promontory is significant for several reasons – bifurcation of common iliac vessels, ureter crossing from lateral to medial side over the bifurcation of iliac vessels, and formation of hypogastric nerves from the fibres of superior hypogastric plexus<sup>1</sup>.

## Blood Vessels

Abdominal aorta divides at L4 vertebral level into common iliac arteries and middle sacral artery<sup>2</sup>.

### Middle Sacral Artery

It continues caudally in the midline over anterior surface of the sacrum and coccyx.

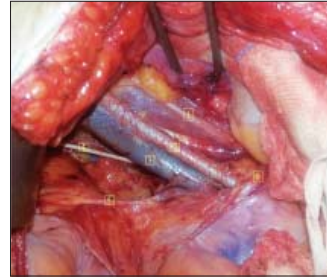### Common Iliac Vessels

They measure about 5cm in length and divide into external and internal iliac arteries at the level of sacral promontory anterior of sacro-iliac joint. The division of common iliac is the cranial boundary of pelvic node dissection. The right common iliac artery is ventral and medial to the vein and the left one is lateral and ventral to the vein.

### External Iliac Vessels

It runs along the medial border of psoas muscle

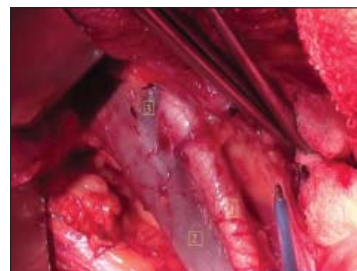until the femoral ring, having the genitofemoral nerve lateral to it. This nerve also forms the lateral boundary of the pelvic lymph node dissection (Figure 1). External Iliac artery gives rise to:



**Figure 1:** Structures seen after Right Pelvic lymph node dissection (Cranial part is towards right lower corner of the picture): 1- Genitofemoral Nerve running on Psoas muscle, 2- External Iliac Artery, 3- External Iliac Vein, 4- Obturator Nerve, 5- Obliterated hypogastric artery and 6- Ureter crossing common iliac bifurcation

- Deep Circumflex iliac artery.
- Inferior epigastric artery – travels above the transversalis fascia under the anterior abdominal wall. Together with the vein, it produces a prominence in anterior peritoneum called lateral umbilical fold which helps in its identification during laparoscopic port placement preventing it from injury which could lead to significant bleeding.

No branch originates from anteromedial aspect of external iliac artery, a fact that can be utilized while performing pelvic node dissection. The origin of the inferior epigastric artery or the deep circumflex iliac vein adjacent to it is the caudal limit of pelvic lymph node dissection (Figure 2).

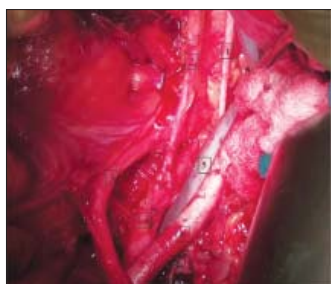


**Figure 2:** After right pelvic lymph node dissection (Lower part is cranial): 1 – Obturator nerve, 2 – Obliterated hypogastric, 3 – Ureter, 4 – Internal Iliac artery, 5 & 6 – External Iliac vein and artery

## Internal Iliac Vessels

The right internal iliac artery is medial to the vein while it is lateral to the vein on the left side. Internal iliac artery has two divisions:

- **Anterior division:** travels parallel and lateral to the ureter and supplies most of the pelvic viscera. Uterine artery is its first branch arising approximately 5–6 cm away from the division of internal iliac artery. Since proximal part of anterior division is devoid of any branches before origin of uterine artery, it provides a long length to be ligated safely in case of hemorrhage (Figure 3).



**Figure 3:** Right Deep circumflex iliac vein (3) crosses the external iliac artery (1) to join the external iliac vein (2) and also forms the caudal limit of the pelvic lymph node dissection (Lower part is cranial)

Uterine artery is the only vessel which crosses over the ureter horizontally helping in its easy identification while dissecting the ureter along its length. It divides into descending and ascending cervical branches before entering the uterus. The ascending cervical branch is formed few millimeters before its entry into the uterus allowing itself to be clamped easily during intrafascial hysterectomy. Uterine artery may supply the ureter through a small branch occasionally near the ureteric tunnel. This branch needs to be controlled during ureteric tunnel dissection.

Beyond the origin of uterine artery, it divides into superior vesical artery and obliterated hypogastric artery at a plane anterior to the uterine artery. Hypogastric (umbilical) artery (Figures 1 & 3) is the medial limit of the pelvic node dissection and also produces the medial umbilical fold, an important landmark that can be seen at the anterior abdominal wall.

Obturator artery is the only lateral branch arising from the anterior division. It lies exactly below the obturator nerve. The deeper limit of obturator lymph node dissection is obturator nerve,

dissection beyond which can lead to damage to the obturator vessels and significant bleeding.

- **Posterior division:** supplies gluteal region via its Iliolumbar, lateral sacral and superior gluteal branches and is out of scope of this article.

## Nerves

The pelvic structures are innervated by both the somatic and the autonomic systems. It can be divided into sympathetic and parasympathetic systems.

The sympathetic nerves cause contraction of internal anal sphincter (smooth muscle) but play a minor role in the contraction of the sphincter vesicae. The parasympathetic system is responsible for relaxation of urethral and anal smooth muscle sphincters and for the contraction of the detrusor. External anal sphincter and the external urethral sphincter (both striated muscles) are innervated by pudendal nerve (somatic innervation).

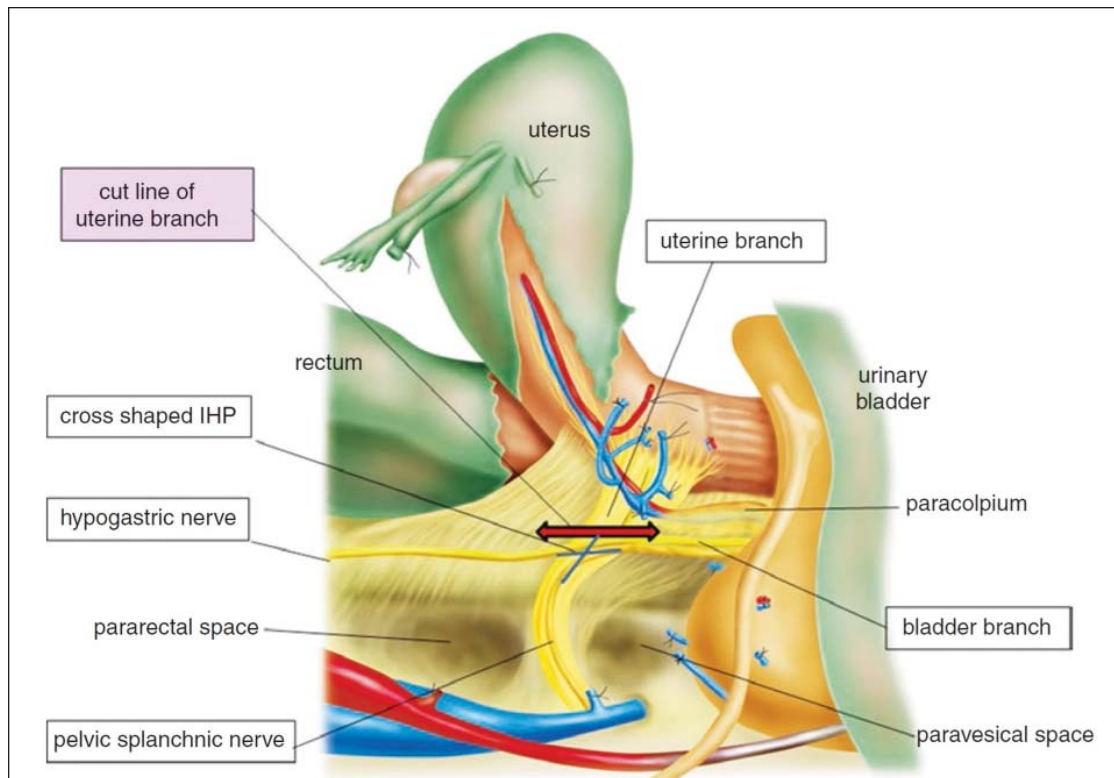
## Pelvic Autonomic Nerves

The most important components of pelvic autonomic system are the superior hypogastric plexus (SHP), the hypogastric nerves (HN) and the inferior hypogastric plexus (IHP)<sup>3</sup>.

The SHP is located around the lower part of the abdominal aorta and its bifurcation. It receives sympathetic fibers from the aortic plexus and the lumbar and pelvic parts of the sympathetic trunks. It divides into two hypogastric nerves at the level of sacral promontory. These nerves run postero-laterally to the posterior rectal wall, medial to the posterior division of the internal iliac artery, dorsal to the ureter and lateral to the uterosacral ligament finally terminating in IHP.

The IHP is located below the ureter and is cross shaped structure stretching from the lateral aspect of the rectum, passing the cervix and vaginal fornix laterally until the bladder base. At its posterior edge it receives parasympathetic afferents from pelvic splanchnic nerves (S2-S4). The efferents of the IHP are:

- **Vesical plexus** – runs lateral and caudal to ureter, branching into vesical and trigonal nerves below the ureterovesical junction. So, any dissection caudal and lateral to the ureter should be avoided to spare these nerves to prevent vesical function disorders.



**Figure 4:** Pelvic Autonomic Nerves and Plexuses

- Vaginorectal plexus – lies medial to the intersection between uterine artery and ureter and divides into two branches – one vaginal and other to upper rectum.
- Inferior rectal plexus – arises from caudal part of IHP in nerve sparing radical hysterectomy, IHP is identified and only uterine branch is divided preserving the bladder branches from the plexus thus improving post surgery bladder function (Figure 4)<sup>4</sup>.

#### Obturator Nerve

This is encountered during pelvic lymph node dissection and needs to be saved as it supplies muscles of the adductor compartment of the thigh. Proximally it can be found deep to the bifurcation of common iliac vessels. It courses towards thigh lateral to the obliterated hypogastric artery and can also be identified at its distal part deep to the external iliac vein when the nerve enters the obturator foramen. Careful dissection deep to the external iliac vein in this area will lead to the nerve after cloquet node is removed and the superior pubic ramus can be felt. This nerve also forms the posterior (deep) boundary of the pelvic node dissection as obturator vessels lie just deep to the nerve. Dissection deep to the nerve may lead to injury to obturator vessels and should be avoided.

#### Ureter

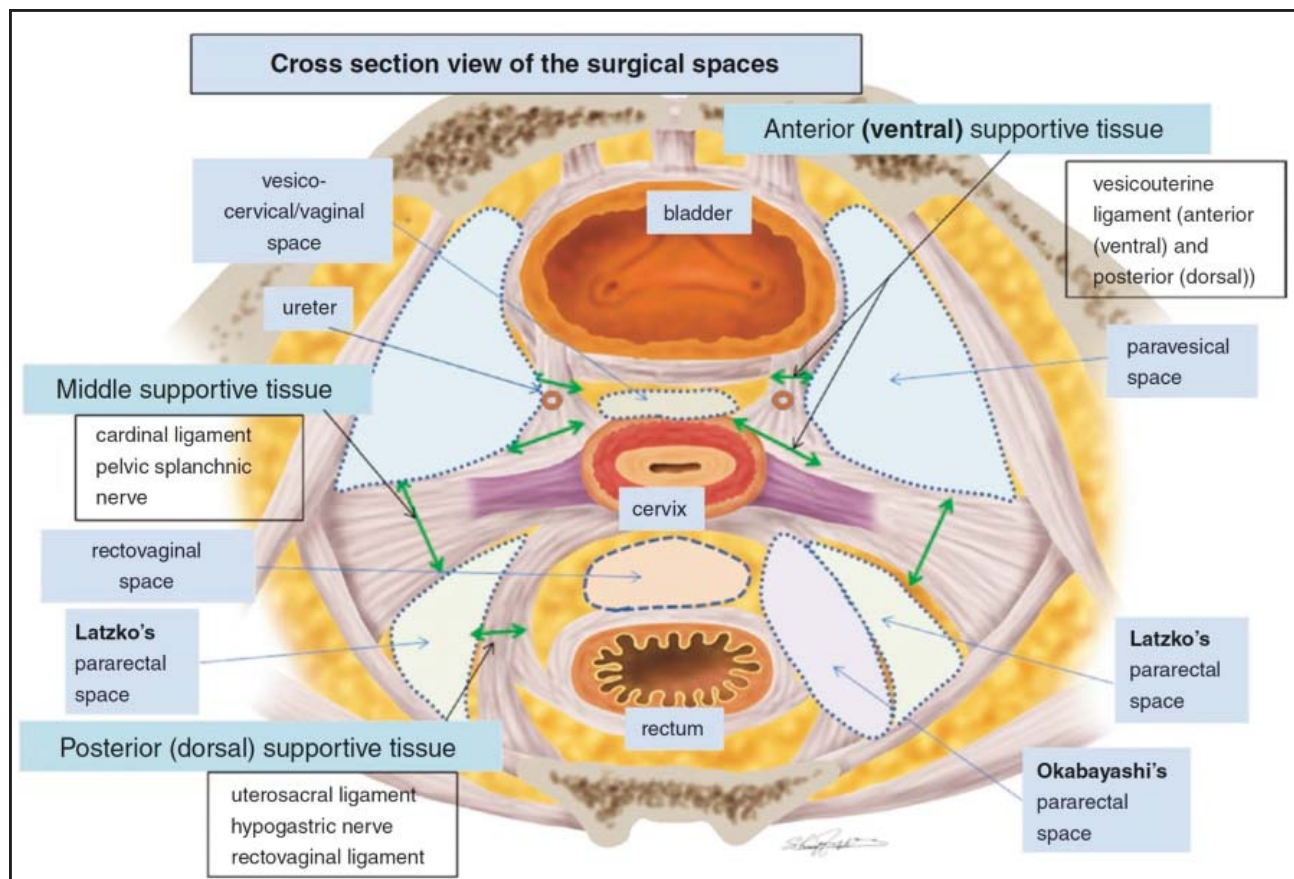
The right ureter enters the pelvis by crossing the external iliac artery (Figures 1 & 2) and the left ureter by crossing the common iliac artery. This is a common site of ureteral injury during infundibulopelvic (IP) ligament ligation. To avoid this, ureters should be identified before dividing the IP ligament.

In the pelvis, ureters descend in the lateral pelvic sidewall running parallel and medial to the internal iliac artery enveloped in a connective tissue sheath called 'mesoureter' and is attached to the posterior leaf of the broad ligament.

Subsequently, the ureters run above the uterine vein and under the uterine artery. This is another site of ureteral injury since it is located only 1.5 to 2 cm lateral to the cervical edge<sup>5</sup>. In order to avoid this, the uterus should be pushed to the other side and elevated while applying clamps during hysterectomy as this maneuver will increase the distance between the ureter and the uterine cervix.

The bleeding in the pararectal area can be distinguished due to the position of ureter in the space between the uterine artery and uterine vein. The arterial bleeding will stop on lifting the ureter





**Figure 5:** Pelvic Retroperitoneal Spaces as seen in Axial Section

as it will close the opening of uterine artery. In case of venous bleeding, lifting the ureter will not cease the bleeding but will give access to identify and control the bleeding point.

After crossing the uterine artery, the ureter enters the ureteral (or Wertheim's) tunnel. This area is variously known as anterior or ventral parametrium, bladder pillar and vesicouterine ligament<sup>6</sup>. Surgically, it is important to know that ureter divides these structures into a medial or anterior part and a lateral or posterior part. Ureter can receive a branch from the uterine artery, which should be identified during dissection of the parametrium.

### Pelvic Retroperitoneal Spaces

Retroperitoneal spaces contain neurovascular structures thus making their knowledge imperative for performing safe dissection. These are virtual spaces and should be developed early on during operation to expose vital structures and retract or separate organs during dissection.

These spaces are named based on their location with respect to organs and essentially are in continuum with each other (Figure 5). They are classified as follows<sup>7</sup>:

#### 1. Lateral spaces:

- A. Paravesical
- B. Pararectal
- C. The fourth space (Yabuki space)

#### 2. Median spaces:

- A. Prevesical / Retropubic (Retzius) space
- B. Vesicocervical / Vesicovaginal spaces
- C. Rectovaginal space
- D. Presacral or retrorectal space

##### 1A. Paravesical space –

It is a lateral extension of prevesical space and is present lateral to the urinary bladder and anterior and superior to the pararectal space. It is limited medially by the urinary bladder, laterally by obturator fascia, ventrally by the superior pubic ramus, dorsally by the cardinal ligament and caudally by the iliococcygeus muscle (part of the levator ani muscle).

It contains obliterated umbilical artery, the obturator neurovascular bundle, lymphatic tissue and, in the lateral and upper part, the external iliac vessels.

It is divided by obliterated hypogastric artery into medial (MPS) and lateral paravesical spaces (LPS)<sup>8</sup>. Dissection of these spaces facilitates easy and complete removal of uterus and its attachment in onco-gynaecological procedures. Exposure of LPS is done for pelvic lymphadenectomy, whereas MPS dissection is done for bladder mobilisation in case of adhesions or exenteration. The posterior limits of dissection for MPS and LPS are levator ani muscle and obturator nerve respectively.

Vascular connections between the obturator and external iliac or inferior epigastric vessels termed as Corona Mortis or accessory obturator vessels require attention as they can be source of troublesome bleeding<sup>9</sup>. They are either arterial (between 8 and 25 % of the cases) or venous (between 67 and 95%) and run posteriorly to the superior pubic ramus.

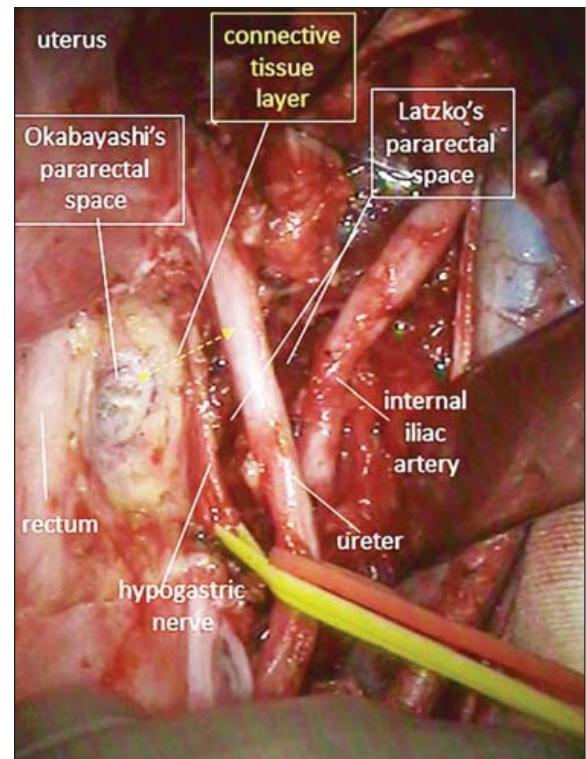
#### 1B. Pararectal space –

It lies lateral to the rectum on both sides, is limited ventrally by the base of broad ligament, caudally by the puborectalis muscle, laterally by the internal iliac artery and medially by the rectum and uterosacral ligament.

There are two different approaches for the dissection of pararectal space - oncological (lateral) approach where peritoneum is incised lateral to the infundibulopelvic ligament and endometriotic (medial) approach when the peritoneal incision is medial to the infundibulopelvic ligament.

The ureter divides pararectal space into into the medial (Okabayashi) and lateral (Latzko's) spaces. As the hypogastric nerve (HN) runs 2-3 cm dorsal to the ureter in the same connective tissue plane (mesoureter), Lemos et al<sup>10</sup> proposed that HN is the structure dividing the PRS into medial and lateral spaces (Figure 6).

Latzko's space is exposed by incising the posterior leaf of broad ligament lateral to the infundibulopelvic ligament and through dissection between the internal iliac artery and ureter. It exposes the uterine artery



**Figure 6:** Right ureter retracted laterally to show that hypogastric nerve divides pararectal space into Okabayashi's space (medially) and Latzko's space (laterally)

originating from the internal iliac artery. It is developed for pelvic lymphadenectomy or during radical hysterectomy.

Okabayashi's space lies between rectum and mesoureter<sup>11</sup>. For some authors, the medial limit is uterosacral ligament. It is named after the Japanese surgeon Hidekazu Okabayashi who first demonstrated the nerve-sparing radical hysterectomy in 1921. Dissection of this space is essential for identification and dissection of hypogastric nerves and is developed by opening the space between the posterior leaf of broad ligament and the ureter. This space is crossed transversely by lateral ligament of rectum (LLR) which consists of middle rectal vessels (MRA). Although LLR and MRA may be absent sometimes, they are important anatomic landmarks during nerve-sparing procedures as pelvic nerve plexus is located slightly caudal to them.

#### 1C. Yabuki space

It was first described by Yoshihiko Yabuki in 2000 and is also called the fourth place<sup>12</sup>.

It is located between the cranial portion of vesicouterine ligament and the ureter. It is dissected during nerve-sparing surgery as it contains the pelvic splanchnic nerves on the way to innervate bladder.

## 2A. Prevesical / Retropubic (Retzius) space

It is bounded anteriorly by the symphysis pubis and Cooper's ligament, posteriorly by the urinary bladder, continues laterally with the paravesical space and contains the dorsal clitoral neurovascular bundle and the proximal urethra.

In urogynaecology, this space is useful for stress urinary incontinence procedures and in oncogynaecology, its dissected during anterior exenteration and pelvic anterior peritonectomy.

## 2B. Vesicocervical/Vesicovaginal space

The vesicocervical is the upper part and vesicovaginal is the inferior part of the same space<sup>13</sup>. It is limited anteriorly by the posterior part of the bladder, posteriorly the cervix (in upper part) and vagina (in lower part), laterally by the vesico-uterine ligaments, inferiorly the first third of the urethra and superiorly the anterior peritoneal fold. This space is dissected following rule that "fat belongs to the bladder". The space is opened medially as lateral dissection will lead to vessels or ureteric injury.

## 2C. Rectovaginal space

This space lies beneath the peritoneal reflection of pouch of Douglas, between the uterus and posterior vaginal wall anteriorly and rectum posteriorly and extends upto the Levator ani. Laterally it is limited by the uterosacral and Mackenrodt ligament. Surgically, an avascular plane is created between the two layers of Denonvilliers fascia with the dictum that the "fat belongs to the rectum". Vaginal veins lie deep to the anterior layer of the fascia and would not bleed if the dissection proceeds between the two layers.

Complete dissection of this space upto levator ani facilitates excision of larger cuff of vagina during radical hysterectomy.

## 2D. Presacral or retrorectal space

It lies behind the rectum between the fascia

propria and Waldeyer fascia. This avascular plane should be carefully dissected in posterior exenteration as breaching Waldeyer fascia can injure presacral veins lying beneath it causing severe bleeding. This space also needs dissection in deep seated endometriosis and in sacro-colpopexy.

## Pelvic Lymph Nodes

Lymphatic drainage follows the course of main vessels. There exists an avascular plane between lymphatics and vessels except for small perforating vessels allowing easy dissection.

Lymphatic drainage of cervix can be divided into three major trunks<sup>14</sup> –

- Lateral trunk – most important route with three branches – upper, middle and lower and drains to interiliac, common iliac, obturator, inferior gluteal, superior gluteal and presacral.
- Posterior trunk – runs through uterosacral ligament and drain to common iliac, superior gluteal, presacral and aortic nodes. Drainage through this route is responsible for atypical locations of sentinel lymph node and is the rationale behind the inclusion of presacral lymphadenectomy.
- Anterior trunk – runs in the posterior aspect of bladder and drains into distal interiliac nodes.

Drainage of uterus also follows three major routes-

- From fundus follows the ovarian vessels to upper part of aortic lymph nodes.
- Along broad ligament draining to interiliac nodes.
- Through the round ligament to the inguinal lymph nodes.

Ovarian lymphatics mainly follow the ovarian vessels and drain to aortic nodes except few that drain into external and internal iliac nodes.

## Key Points

- Sacral promontory not only forms the entry to the pelvis but is a prominent and fixed landmark which can help identify planes and structures in a scarred pelvis.
- Understanding of potential pelvic retroperitoneal spaces is important as they contain important neurovascular structures and being continuous with each other would also facilitate spread of



infection from one area to the other.

- There is no branch of external iliac artery anteromedially and a safe dissection is possible in this area by remaining parallel to this artery.
- Ureter carries its own mesentery and blood supply rather than receiving segmental blood supply. However, a small branch of uterine artery supplies the distal part of the ureter and needs to be controlled while dissecting ureteric tunnel in radical hysterectomy.
- Only vessel that crosses ureter in pelvis is uterine artery.
- Bleeding in pararectal space from uterine artery can be distinguished from that of vein by lifting the ureter which would lessen or stop the arterial bleed (unless artery is completely transected) but not that from uterine vein.
- Proximal 5-6 cm of anterior division of internal iliac artery does not give any branch thus providing a long length for a safe ligation in case of hemorrhage from organs supplied by it.
- In nerve sparing hysterectomy, the inferior hypogastric plexus is transected in such a fashion that only the uterine branches are cut sparing the bladder branches.
- While dissecting bladder or rectum away from uterus / vagina it must be remembered that “fat belongs to the bladder and rectum”.

## References

1. Puntambekar S, Manchanda R. Surgical pelvic anatomy in gynecologic oncology. *Int Gynaecol Obstet* 2018; 143: 86–92.
2. Baggish M.S., Karram M.M. (2006), *Atlas of pelvic anatomy and gynaecologic surgery* 2<sup>nd</sup> Ed. Philadelphia: Saunders Elsevier.
3. Mauroy B, Bizet B, Bonnal JL, et al. Systematization of the vesical and uterovaginal efferences of the female inferior hypogastric plexus (pelvic): applications to pelvic surgery on women patients. *Surg Radiol Anat* 2007; 29:209-17.
4. Fujii S. Anatomic identification of nerve-sparing radical hysterectomy: a step-by-step procedure. *Gynecol Oncol* 2008; 111: S33-41.
5. Hurd WW, Chee SS, Gallagher KL, et al. Location of the ureters in relation to the uterine cervix by computed tomography. *Am J Obstet Gynecol* 2001; 184: 336-9.
6. Fujii S, Takakura K, Matsumura N, et al. Precise anatomy of the vesico-uterine ligament for radical hysterectomy. *Gynecol Oncol* 2007; 104: 186-91.
7. Gomel, V.; Brill, A. *Reconstructive and Reproductive Surgery in Gynecology*; Infoma Healthcare: London, UK, 2010; pp. 40–5.
8. Kadar, N. 3 Laparoscopic anatomy and dissection of the pelvis. *Baillière's Clin. Obstet. Gynaecol.* 1997, 11, 37–60, ISSN 0950-3552.
9. Berberoğlu M, Uz A, Ozmen MM, et al. Corona mortis: an anatomic study in seven cadavers and an endoscopic study in 28 patients. *Surg Endosc* 2001; 15:72-5.
10. Lemos N.L, Ribeiro R, Fernandes G.L, et al. Nerve-sparing routes in radical pelvic surgery. In *Minimally Invasive Gynecology*; Springer: Berlin/Heidelberg, Germany, 2018; pp. 61–75.
11. Fujii S, Takakura K, Matsumura N, et al. Anatomic identification and functional outcomes of the nerve sparing Okabayashi radical hysterectomy. *Gynecol Oncol* 2007; 107: 4-13.
12. Yabuki Y, Sasaki H, Hatakeyama N, et al. Discrepancies between classic anatomy and modern gynecologic surgery on pelvic connective tissue structure: Harmonization of those concepts by collaborative cadaver dissection. *Am J Obstet Gynecol.* 2005; 193: 7–15.
13. Selçuk I, Ersak B, Tatar I, et al. Basic clinical retroperitoneal anatomy for pelvic surgeons. *Turk. J. Obstet. Gynecol.* 2018, 15, 259–69.
14. Cibula D, Abu-Rustum NR. Pelvic lymphadenectomy in cervical cancer-surgical anatomy and proposal for a new classification system. *Gynecol Oncol* 2010; 116: 33-7.

## A Heartfelt Tribute



**Dr Susham Dhawan**  
(01.01.1935 – 29.03.2020)

**Devoted Doctor | Ardent Academician  
| Inspiring Mentor | Caring Parent**

Dr. Dhawan was born in a humble household in Lyallpur, with a burning desire to learn and excel. Her innate motivation led her to strive for academic excellence and eventually distinguish herself as an eminent clinician, academician and surgeon.

From Amritsar Medical College she moved to Chandigarh and had the privilege of working under the mentorship of Dr. Sant Ram Dhall in 1962, who at the time was actively involved in setting up of the Dept. Of

ObGyn at PGIMER. Marriage in 1963 brought her to Delhi where she worked at Irwin Hospital for over a decade. Thereafter, she served as Senior Consultant at Tirath Ram Shah Hospital, spearheading the upgradation of the hospital's medical infrastructure. Throughout her 40+ years of private practice she remained proactive in her academic pursuits.

Multiple hardships and family tragedies did not deter her from her passion and dedication. With a long and active professional career spanning almost 6 decades, Dr. Dhawan touched the lives of three generations of patients, students and colleagues. Anyone who knew her would bear testimony to her gentle nature and endearing personality.

After braving renal failure for almost five years, she peacefully left for her heavenly abode, at home in Chandigarh, on the 29<sup>th</sup> of March 2020.

She has left a deep impact on each and every soul she came across during her lifetime and is fondly remembered for her kind compassion, loving humility and selfless devotion.

# Ergonomics of Laparoscopy

Aayushi Jain<sup>1</sup>, Parveen Bhatia<sup>2</sup>

<sup>1</sup>Research Scholar, Maternal-Fetal Medicine, Department of Obst. & Gynae, Maimonides Medical Centre Brooklyn, New York,

<sup>2</sup>Founding Chairiman & Senior Consultant, Institute of Minimal Access, Metabolic & Bariatric Surgery, Institute of Robotic Surgery, SGRH & Medical Dir. Bhatia Global Hospital & Endosurgery Institute, New Delhi

## Introduction

Laparoscopic surgery has revolutionized the practice of gynecology. For patients, laparoscopy has brought the benefits of minimally invasive care - shorter hospital stays, reduced post-operative pain and recovery time. Surgeons chose laparoscopy as they can provide better outcomes to their patients. Ergonomics is a crucial aspect of laparoscopy, because if proper ergonomics are not followed, laparoscopy has the potential to be detrimental to the physical health and long-term wellbeing of surgeons.

This article explores the importance of ergonomics in laparoscopic surgery, challenges posed to surgeons as well as highlights optimal ergonomics and setup for laparoscopic procedures.

The term ergonomics is derived from the Greek word's "ergon" meaning work and "nomos" meaning natural laws or arrangement. Ergonomics is defined as "applying knowledge from human sciences to match jobs, systems, products, and environments to physical and mental capabilities of people in order to promote safety, health, and wellbeing while performing tasks effectively."<sup>1</sup>

Understanding and implementing good ergonomic conditions can reap dividends both in terms of day to day comfort, efficiency and safety of the operating team as well as long term wellbeing of surgeons.

## Risks Associated with Poor Ergonomics in the (OR)

The OR team comprising of the surgeon, first assist, scrub nurse and surgical technician in the operation theatre face significant ergonomic risks due to the nature of tasks they perform on a regular basis such as standing in static postures, holding instruments, equipment and materials, working long durations, using precision skills, and operating new equipment. The instruments, devices, and equipment used

in the OR may not be fitted to the worker, which can promote an onset of musculoskeletal pain and over time may develop musculoskeletal disorders. In high-volume laparoscopic surgery centers, numerous studies have reported the incidence of carpal tunnel syndrome, eye strain and cervical spondylosis among surgeons.<sup>2</sup>

Improving ergonomics in the OR environment can lead to less stress, strain, and fatigue for the worker, and help prevent musculoskeletal injuries to the surgical team and boost performance.

## Challenges Associated with Laparoscopic Surgery

Laparoscopic Surgery presents surgeons with certain challenges when compared to an equivalent open procedure; this in turn affects the efficiency of the surgeon and in turn the operative time.

### Lack of Tactile Feedback

One of the most salient lacunae of laparoscopic surgery is the significant reduction in tactile feedback. Laparoscopy takes away much of the tactile sensation surgeons are intuitively conditioned with in open surgery.

Two-dimensional Vision resulting in limited depth perception

Most laparoscopic cameras on the market today still offer two-dimensional vision, taking away depth perception and often true color of tissue that surgeons rely heavily on during open procedures.

### Fulcrum Effect of Instruments

Long graspers maneuvered through trocars get substituted for the surgeon's hand and this reduces efficacy and increases time of dissection. The fulcrum effect of instruments where the surgeon has to train their mind to map movement of their hand in one direction to the movement of the instrument tip in the opposite direction results in a steep learning curve as well as continued physical

strain. For instance, when a surgeon wishes to move the instrument tip to the left, they need to move their hand to the right.

### Decreased Degree of Freedom of Movement

Compared to the high degree of freedom available in open surgery due to utilization of the human wrist and fingers, laparoscopic surgery has only 4 degrees of freedom. This greatly decreases efficiency of surgical maneuver and poses ergonomic risk.

### Decoupling of Visual and Motor Axis

One of the most significant cognitive challenges for surgeons in their shift from open to laparoscopic surgery is to overcome the spatial separation of the axis of vision and the axis of the physical aspect of the procedure. The surgeon does not get a chance to directly look at the instruments or his hands and also at the field of surgery at the same time. He has to learn to adapt to the difficulty of combining the two functions into the same-channeled approach in order to dexterously manipulate the tissues without direct contact. Studies have shown that working in separate coordinate systems decreases performance, leading to higher rates of error in the procedure.<sup>3</sup>

### Static Posture

Several studies highlight posture as the main cause of pain. The static postures assumed during laparoscopic surgeries have been demonstrated to be more harmful than dynamic postures in open surgery. This is caused due to the fact that muscles and tendons build up lactic acid and toxins when held for prolonged periods in the same posture.

Laparoscopic procedures typically result in a straight back but twisted neck. This poor ergonomic posture adopted by surgeons during the procedure can result in discomfort and, in turn, injury. Additionally, during laparoscopic surgery the upper limbs are frequently positioned in an excessive excursion or abduction in order to use the long laparoscopic instruments, which further creates additional musculoskeletal stresses compared with the equivalent open surgical procedure.

### OR Crowding, Floor Space & Poor Cable Management

Furthermore, the average operating theatre is not designed to house all the equipment required for advanced laparoscopic procedures. This can lead

to a crowded working environment, which may further cause operative inefficiency and expose both patient and OR team to potential injury.

Operating Room (OR) crowding due to increase in the number of equipment, tubes & cables in the operating room, creates physical hazards for traffic in the operating room.

## Optimising The Environment & Overcoming Ergonomic Challenges

The goal of adjusting ergonomics during laparoscopic surgery is to ensure proper comfort, efficacy of the movements and minimize musculoskeletal injuries to the surgeon.

The factors affecting ideal ergonomic posture of the surgeon are:

1. OR table height
2. Position of the monitor
3. Foot pedals
4. Laparoscopic Port Placement
5. Choosing Laparoscopic Instruments
6. Arm Support
7. Integrated OR & Cable Management

### 1. OR Table Height

Similar to open surgery, the recommended angle at the elbow joint should be between 90 to 120 degrees.<sup>4</sup> This can usually be attained by making adjustments to the height of the table. The height of the table should be adjusted in such a way that laparoscopic instrument handles are slightly below the level of the surgeon's elbows. (Figure 1) The operating surface height is raised by insufflation of carbon dioxide requiring the operating table to be lowered. The ergonomic operating surface height should lie between 70% and 80% of the surgeon's ground to elbow distance.<sup>5</sup> (Figure 2)

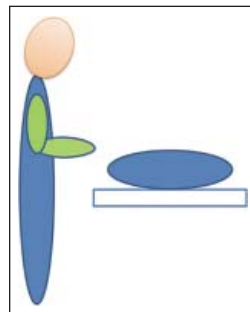


Figure 1: Optimal OR table height and elbow position<sup>5</sup>

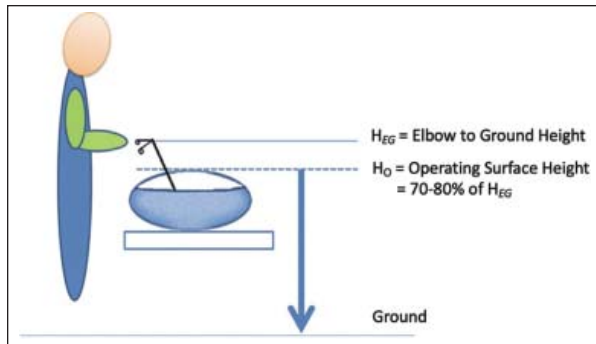


Figure 2: Ergonomic operating surface height<sup>5</sup>

## 2. Monitor position

The monitor is often placed on top of the laparoscopy tower and is mounted to it, limiting the possibility for any adjustment. However, the monitor should be placed directly in front of the surgeon in the horizontal plane and also in line with the forearm-instrument motor axis.

In order to avoid neck extension, the monitor should be placed lower than the surgeon's eye level in the sagittal plane. The most ideal viewing direction is approximately 15 to 40 degrees downward.<sup>6</sup> (Figure 3) Viewing distance is highly dependent on monitor size. Van Det et al suggested a distance of 80-120 cm to

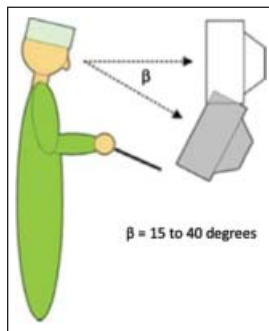


Figure 3: Monitor position should be 15-40 degrees downward<sup>5</sup>

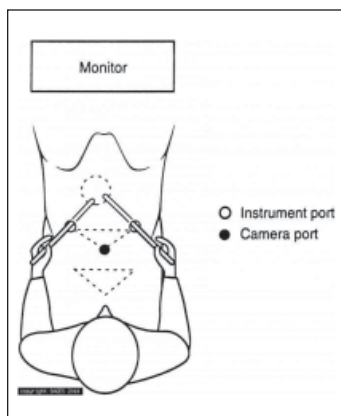


Figure 4: Coaxial Alignment Principle<sup>7</sup>

avoid excessive accommodation, convergence and staring. It should be far enough to avoid extensive accommodation of the eyes and contraction by the extraocular muscles, and close enough to avoid staring and loss of detail.<sup>4</sup> The monitor, target quadrant and the surgeon should be in a same axis for maximal ergonomic posture.<sup>7</sup> (Figure 4)

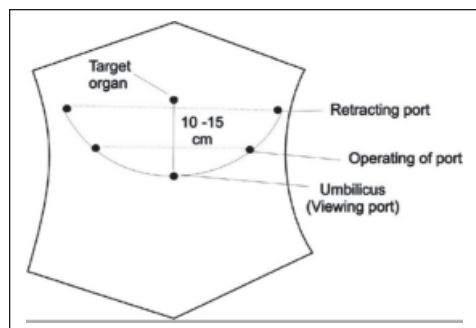
## 3. Foot Pedals

In laparoscopic surgery, foot pedals are normally utilized to control diathermy equipment. Poorly positioned foot pedals may result in instability of the surgeon's posture. Therefore, in order to optimize, the foot pedals should be aligned in the same direction as the instruments, towards the target quadrant and the principal laparoscopic monitor. A pedal that has an in-built footrest can present an added advantage to the surgeon by ensuring that the other foot is not in the air and thereby give better stability to the surgeon.

## 4. Laparoscopic Port Placement

There is no universal consensus about placement of ports for advanced laparoscopic procedures. The placement of ports is currently determined by the surgeons' preference based on individual experience. Placement of trocars in a triangular fashion facilitates smooth instrument manipulation along with adequate visualization during laparoscopy. This port placement technique is called triangulation.<sup>8</sup> (Figure 5) The target organ should be 15–20 cm from the center port used for placing the optical trocar. Ideally, the two remaining trocars are placed in the same 15–20 cm arc at a distance of 5–7 cm on either side of the optical trocars. This allows the instruments to work at a 60°–90° angle with the target tissue.<sup>9</sup> This also helps in avoiding problems of a long handle caused by placement of ports that is either too far or too near and the problem of abdominal wall interference. Additionally, this method of placing the ports minimizes instrument interference, creates less strain on the surgeon and gives them a comfortable position to perform the surgery. When necessary, two additional retracting ports can be placed in the same arc but more laterally to ensure that instruments do not clash.





**Figure 5:** Triangulation<sup>8</sup>

Most surgeons do end up customizing trocar positions. If port placement is done wrongly, surgeons have to push the abdominal wall which can cause great discomfort to the surgeon's hand.

### 5. Choosing Laparoscopic Instruments

The selection of laparoscopic instruments for a case should be done while ensuring that the instruments:

- Enable the surgeon to keep wrist in neutral position and not in a bent position
- Permit surgeon to keep both arms at the side of their body
- Avoid pressure point on the hands
- Allow surgeon to apply force with a powerful grip
- Allow fine manipulation with precise movements

### 6. Arm Support

A study reported that support of the shoulder, elbow and wrist significantly improved the accuracy of laparoscopic manipulations by the laparoscopic surgeon.<sup>9</sup> Moreover, a randomized controlled crossover trial noted a significant improvement in the accuracy of laparoscopic surgical performance on a simulator in novice surgeons using armrests.<sup>10</sup>

### 7. Integrated OR & Cable Management

When possible, it is recommended that the OR equipment be ceiling boom-mounted, enabling easy and versatile positioning of monitors relative to the operating team with no trailing cables on the floor.

Furthermore, many medical device companies now provide integrated ORs. The integrated OR comprises a system in which the laparoscopic equipment, including room and camera lights, gas

insufflation, diathermy and multiple flat-screen monitors, is permanently installed in ceiling-mounted booms to be operational on demand. This presents an ideal OR environment and is likely the direction ORs of the future are heading toward.

## Conclusion

Laparoscopic surgery is highly beneficial for patients with reduced post-operative pain and faster recovery but is more demanding for the surgeon. Over the years, the high technological complexity and at times poorly adapted equipment and environment have led to alarming complaints of fatigue and discomfort from surgeons during laparoscopic surgery. Promoting better understanding of ergonomics as well as integrating the recommendations highlighted in this article can not only make the work of a surgeon more comfortable in the operating room but also reduce physical strains on the surgeon, avoid long term musculoskeletal injuries and increase productivity intraoperatively.

## Bibliography

1. Choi, S. A Review of the Ergonomic Issues in the Laparoscopic Operating Room. *J HealthC Eng.* 2012; 3(4), 587–604.
2. Hemal AK, Srinivas M, Charles AR. Ergonomic problems associated with laparoscopy. *J Endourol.* 2001;15(5):499–503.
3. Wang Y, MacKenzie CL. *Human-Computer Interaction INTERACT '99.* Edinburgh, Scotland: IOS Press; 1999. Effects of orientation disparity between haptic and graphic displays of objects in virtual environments.
4. Van Veelen MA, Kazemier G, Koopman J, Goossens RH, Meijer DW. Assessment of the ergonomically optimal operating surface height for laparoscopic surgery. *J Laparoendosc Adv Surg Tech A.* 2002;12(1):47–52.
5. Quinn D, Moohan J Optimal laparoscopic ergonomics in gynaecology. *Obstet Gynecol.* 2015;17:77–82.
6. Hanna GB, Shimi SM, Cuschieri A. Task performance in endoscopic surgery is influenced by location of the image display. *Ann Surg.* 1998;227:481–484.
7. Soper NJ, Scott-Conner C. *The SAGES Manual. Volume 1: Basic Laparoscopy and Endoscopy.* Springer. 2012;1:265.
8. Supe AN, Kulkarni GV, Supe PA. Ergonomics in laparoscopic surgery. *J Minim Access Surg.* 2010;6:31–36.
9. Patil PV, Hanna GB, Frank TG, Cuschieri A. Effect of fixation of shoulder and elbow joint movement on the precision of laparoscopic instrument manipulations. *Surg Endosc.* 2005;19:366–8
10. Galleano R, Carter F, Brown S, Frank T, Cuschieri A. Can armrests improve comfort and task performance in laparoscopic surgery? *Ann Surg.* 2006;243:329–33.



# Endometriosis – Diagnosis and overview of management

Kanika Jain<sup>1</sup>, Madhu Goel<sup>2</sup>, Debasis Dutta<sup>3</sup>, Ashu Sharma<sup>4</sup>

<sup>1</sup>Senior Consultant Obst. & Gynae, Sir Ganga Ram Hospital, <sup>2</sup>Senior Consultant Gyne/Obst. Fortes La Femme, <sup>3</sup>Senior Consultant Obst. & Gynae, Sir Ganga Ram Hospital, <sup>4</sup>Senior Consultant Radiologist Veteran's Affairs Healthcare Phoenix, Arizona, USA

Endometriosis is a benign, progressive, chronic inflammatory disease which has a huge physical, sexual, reproductive, psychological and social impact on the life of the patient.

The exact pathogenesis of endometriosis is not clear, the most common theory being of retrograde menstruation. The endometriotic lesions are hormonally active and respond to oestrogen and progesterone. Studies have also found increased number of inflammatory cells like macrophages and pro-inflammatory cytokines like interleukin (IL)-1, IL-6 and tumor necrosis factor (TNF) in the endometrial lesions.

The most common sites of endometriosis are the ovaries with spread to anterior and posterior cul-de sac, broad ligament, Fallopian tubes, uterosacral ligaments, uterus, sigmoid colon, Appendix and Round ligaments. Less commonly involved, are the vagina, cervix, recto-vaginal septum, caecum, ileum, inguinal canal, perineal scars, urinary bladder, ureter and the umbilicus. Rare cases of endometriosis of gastrointestinal tract, bones, vertebra, central nervous system and lungs have been reported.

In recent times there has been a “paradigm shift” in the perception and management of endometriosis. It is being recognized that endometriosis is a lifelong disease and hence requires long term management strategy. The diagnosis of endometriosis is largely based on signs and symptoms with radiological support and no longer requires histopathology or laparoscopy for confirmation. The treatment base has shifted to primarily medical treatment with the goal being to minimize the surgery to once in the lifetime of the patient.

## Diagnosis of Endometriosis

The diagnosis of endometriosis is now based on the symptoms and signs of the patient with inputs from imaging studies. Hence, a detailed history

is an absolute must in a patient with suspected endometriosis.

Endometriosis can present at any age with variable symptoms. It can be a completely asymptomatic finding or may present with acutely distressing symptoms. These are-

- Severe dysmenorrhoea causing disruption in normal life. In adolescents there will be history of school absenteeism, multiple visits to the doctors, poor or no response to medications used to treat pain like NSAID's and OC pills. The social attitude to period pain, delay in seeking medical advice, inability of physicians to recognize endometriosis all lead to an average 7 to 10-year delay in making a diagnosis of endometriosis.
- Chronic pelvic pain – while initially the pain is cyclical and occurs only during and around menstruation, gradually it becomes chronic impacting the personal, social and professional life of the patient.
- Deep dyspareunia is again a classic symptom indicating rectovaginal endometriosis. Detailed history should be taken regarding frequency of intercourse, fear of intercourse, possibly leading to vaginismus and disturbed couple relationship.
- Cyclical intestinal complaints – perimenstrual dyschezia, bloating, diarrhea or constipation are frequent complaints of the patient leading to work absenteeism during menstruation.
- Fatigue is an often unrecognized classic symptom of endometriosis. The patients usually give history of tiredness, lack of energy and enthusiasm.
- Infertility – sometimes the only presenting symptom of endometriosis can be infertility and it can present as a surprise at the time of diagnostic laparoscopy.
- Heavy menstrual bleeding, post coital bleeding-menstrual disturbances may indicate an associated adenomyosis.

Sometimes the patient may present with non-

gynaecological cyclical symptoms like dyschezia, dysuria, haematuria, rectal bleeding, shoulder pain, sciatic pain.

In addition, history of diagnosis of ovarian cyst, PID, irritable bowel syndrome, fibrocystic breast disease are risk factors for subsequent diagnosis of endometriosis.

## Examination

Examination findings are variable. All patients should be examined thoroughly. There may, however, be no examination findings.

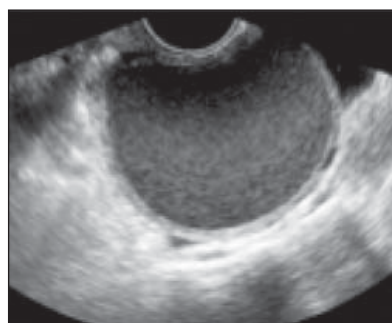- Inspection of vagina—A per speculum examination should be done to inspect the posterior fornix for any evidence of endometriotic nodules
- A bimanual examination should be done to check for the nodules in the vagina, nodularity and tenderness in the uterosacral ligaments, POD, evaluate the fixity of the uterus and to check for any palpable adnexal masses. Sometimes bimanual examination is not possible due to extreme pain. In young adolescents who are not sexually active, a rectal examination can be done.
- A rectovaginal exam can reveal mass involving rectosigmoid colon or adnexal masses
- Abdominal examination should be done in all cases.

A prospective study has stated that reliability of clinical examination in detecting endometriosis is improved during menstruation.

## Imaging Ultrasound

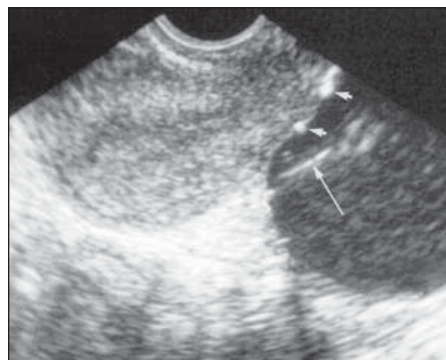
Ultrasound is the first line imaging technique in a patient of suspected endometriosis. It is done with the purpose of trying to establish a diagnosis, map the disease location and to assess the severity of disease prior to medical or surgical therapy.

Transvaginal scan-TVS can quite accurately diagnose

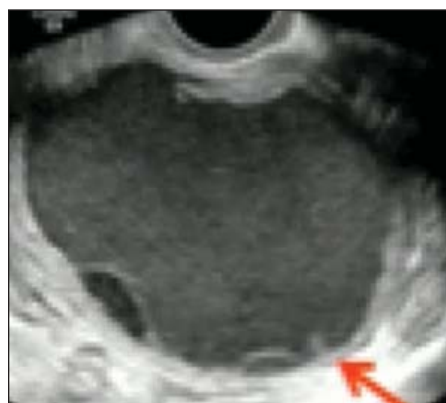

presence of endometrioma. The endometrioma typically has the following characteristics on ultrasound:

- Unilocular complex adnexal cyst
- LOW LEVEL ECHOES ~seen in 95%: NOT specific
- HYPERECHOIC WALL FOCI ~35%, cholesterol deposits, rare in other lesions



- SEPTATIONS in Unilocular/Multilocular cyst



- Multiplicity
- No neoplastic features
- Can be SPECIFIC if all features
- Reassuring for endometrioma when there is no internal vascularity
- Typical Benign Ovarian masses have High RI (> 0.5)

Ovarian endometriomas are only rarely sole findings. Thus, if ovarian endometrioma is diagnosed on ultrasound, all effort should be made to detect the presence of deep infiltrating endometriosis.

There are 4 basic steps when diagnosing a patient with known or suspected endometriosis.

**Step 1:** Routine evaluation of uterus and adnexae for sonographic signs of adenomyosis/ presence or absence of endometrioma

**Step 2:** Evaluation of transvaginal sonographic “soft markers”, that is site specific tenderness and ovarian mobility

**Step 3:** Assessment of status of POD using real time ultrasound based “sliding sign”

**Step 4:** Assessment of DIE nodules in anterior and posterior compartments

**TRUS** - In patients in whom TVS cannot be done, a trans rectal ultrasound can be done. It can help predict the presence of rectovaginal endometriosis and bowel wall involvement

Assess depth of infiltration by endometriosis

Size, number of lesions & distance from anal verge

To detect lesions on the posterior bladder wall

## MRI

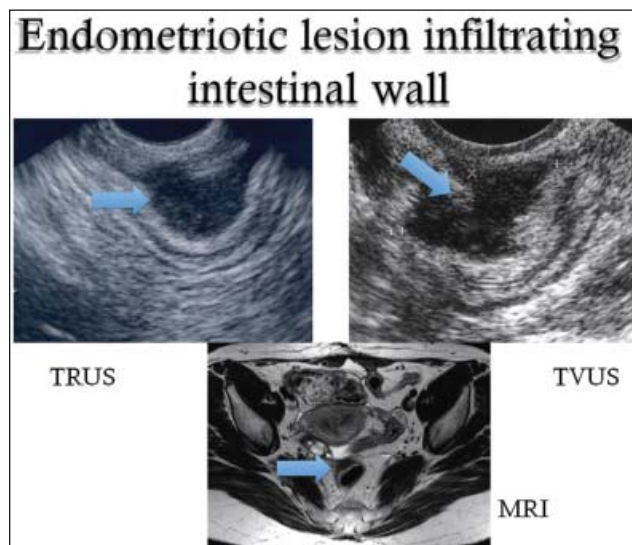
MRI is ONE STOP SHOP for deep infiltrating endometriosis. But it does not help with peritoneal endometriosis.

It can determine the extent of DIE specially when Laparoscopic inspection is limited by adhesions

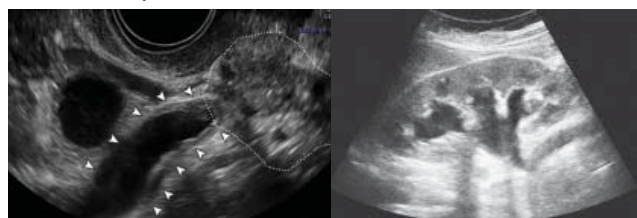
Allows complete mapping of lesions

Has high specificity to differentiate from other adnexal lesions.

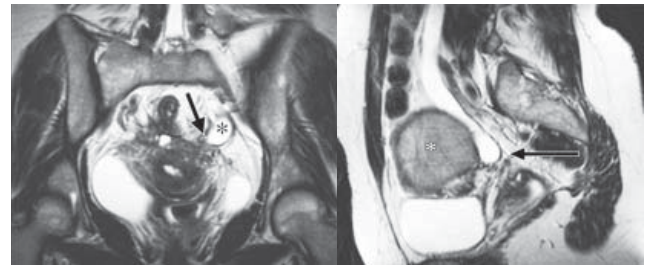
Combination of MRI and TVS increases accuracy to almost 100%



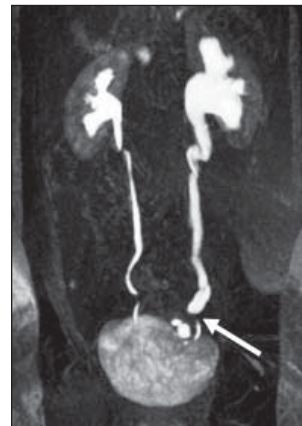DIE involving the ureter with hydronephrosis:  
As seen through various imaging modalities-  
Ultrasonic pictures



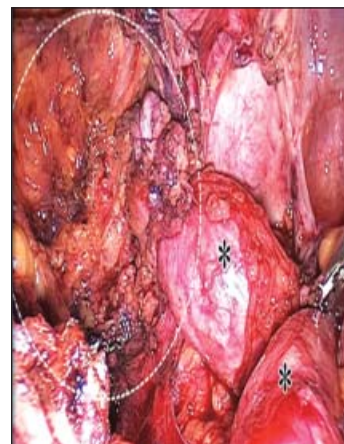
## MRI Pictures



## IVP



## Laparoscopic Findings of Same Patient



## Laparoscopy for Diagnosis of Endometriosis

Laparoscopy is considered to be the ‘gold standard for diagnosis of endometriosis’. A negative diagnostic laparoscopy in women with signs and symptoms is highly reliable for the exclusion of endometriosis (Wykes et al 2004).

There can be varied manifestations of endometriosis on laparoscopy

A good laparoscopy should be done by an expert surgeon and should include assessment of uterus and adnexae, peritoneum of ovarian fossa, vesico

uterine fold, POD and para rectal spaces, rectum and sigmoid, appendix, caecum & diaphragm. The policy on laparoscopy should always be to “see and treat” and laparoscopy should not be done for diagnosis alone.

## Management of Endometriosis

### Asymptomatic Endometriosis

Asymptomatic endometriosis is defined as incidental finding of peritoneal, ovarian or deep endometriosis without pelvic pain or infertility.

It does not require treatment, but it requires monitoring. An ultrasound should be repeated every 3-6 months. Treatment should be considered if there is sudden enlargement of the cyst or when malignancy cannot be ruled out, symptoms develop or if the patient cannot come for follow up regularly.

### Adolescent Endometriosis

Constitutes around 3 to 5% of patients suffering from endometriosis. The patients usually complain of severe dysmenorrhoea. It is an important cause of school absenteeism. In cases of early onset progressive dysmenorrhoea Mullerian anomaly with outflow tract obstruction should be ruled out.

Medical management forms the cornerstone of management of adolescent endometriosis and oral contraceptives remain the most commonly used treatment modality.

### Medical Management of Endometriosis

Endometriosis is a lifelong problem and is a progressive disease. In order to limit the number of surgeries in a particular patient, medical management is advocated & it can be started without the need for laparoscopy or histopathology

### Indications of Medical Management

- Empirical management to be started based on symptoms after adequate counseling.
- Prevention of recurrence following surgery
- If recurrence occurs
- When the patient refuses surgery

The pathophysiology of endometriosis revolves around increased production of estradiol, increased aromatase activity, increased production of inflammatory markers, progesterone resistance

The medical management is targeted towards controlling pain and suppression of hormonally active endometriotic tissue.

Various options available are:

### NSAIDs

NSAIDs are commonly used as first line treatment for endometriosis. It has a favourable effect on dysmenorrhoea. They act by inhibiting the enzyme COX that is crucial for the production of inflammatory mediators. Long term use of NSAIDs may have side effects like inhibition of ovulation, risk of gastric ulceration, cardiovascular disease.

### Combined Oral Contraceptives

They reduce endometriosis associated dyspareunia, dysmenorrhea and nonmenstrual pain. They have an advantage in terms of ease of use, widespread availability, cost, proven long term safety and an additional contraceptive effect

Various routes of contraceptives have been tried, example oral, vaginal contraceptive ring, transdermal patch etc. As compared to cyclic regime, continuous therapy has been shown to have better results.

There is a concern since endometriosis is a predominantly estrogen dependent disease, Estrogen component may mask the effect of progestin possibly by activating the disease.

### Progestins

Progesterone has multiple mechanisms of action that form the pathophysiologic basis of its use in endometriosis. It induces decidualization of the endometrium, inhibits estrogen induced mitosis, alters estrogen receptors, inhibits angiogenesis and expression of matrix metalloproteinase needed for the growth of the endometriotic implants.

Different progestins have been used in the treatment of endometriosis.

DMPA

Cyproterone acetate

Medroxy progesterone acetate

Desogestral

Dienogest

LNG IUD

Out of all the progestins maximum studies have



been done with Dienogest. It has high specificity for progesterone receptors and less anti-androgenic side effects. Continuous administration leads to decidualization and atrophy of the endometrial lesions. It also has anti-inflammatory, anti-angiogenic and anti-proliferative effects.

It is an effective and generally well-tolerated treatment but it should be used with caution as it causes a loss of bone density.

LNG IUS delivers progesterone locally and causes atrophy of the endometrium, hypomenorrhea with possible decreased retrograde menstruation and higher concentration of progesterone in the peritoneal cavity suppressing the activity of ectopic endometrium by anti-inflammatory and immunomodulatory functions. its long term use and better side effect profile LNG-IUS offers a great option in women who do not desire to conceive.

#### **GnRH Agonist**

Nafarelin, Leuprolide, Buserelin, Goserelin, Triptorelin can be used. Because of hypo oestrogenic symptoms and loss of bone density with GnRh agonist, use is limited to 6 months and add back therapy is needed in case of longer use. Use is mainly limited to postsurgical treatment.

#### **Anti Progestogens**

Gestrinone has been used in a dose of 1.25 mg or 2.5 mg twice weekly, however it is not available in India

#### **Aromatase Inhibitors**

Aromatase inhibitors block estrogen synthesis both in the periphery and the ovaries. Anastrozole, letrozole and exemestane are third generation aromatase inhibitors that can be administered orally. They are reversible, more potent and have faster onset of action.

In women with pain from rectovaginal endometriosis refractory to other medical or surgical treatment, clinicians can prescribe aromatase inhibitors with OCP, progestogens or GnRh analogues as they reduce endometriosis associated pain. Letrozole 2.5 mg can be given daily for 12 weeks with progesterone add back

Long term medical management has to be individualized for each patient and depends on the severity of pain, availability, cost, side effects etc

## **Surgical Treatment of Endometriosis**

The goal of treatment of endometriosis is to limit the number of surgeries required to minimum, preferably one surgery in the lifetime of the patient.

Pre-operative good bowel preparation should be a mandate in all cases of surgery for endometriosis.

#### **Surgery for Endometriosis in Infertility**

Sometimes you encounter endometriosis at the time of diagnostic laparoscopy for infertility, the dictum is to see and treat. Hence consent counselling and preparation for diagnostic laparoscopy should be adequate. Endometriosis can present in a myriad of ways starting from powder burn lesions to clear vesicles, hence at the time of diagnostic laparoscopy this should be kept in mind.

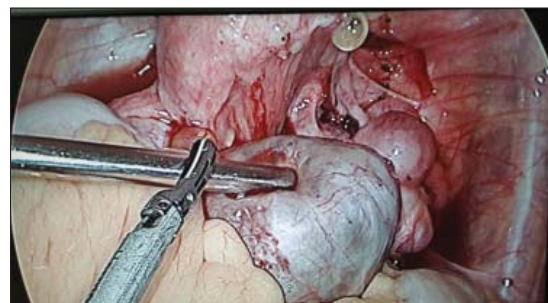
**Peritoneal Endometriosis:** Exclusively endocrine therapy has results comparable to surgery in these cases.

#### **Ovarian Endometriosis**

**Endometriomas:** In cases of endometriomas cystectomy is always better than drainage. Separate the ovary with the endometrioma from the pelvic side wall where it is usually adherent. Usually the cyst will rupture. Extend the opening of the cyst wall adequately to expose the cavity. Multiple incisions and excessive opening should be avoided to prevent damaging the ovarian cortex, functional ovarian tissue and hilum. Irrigate and inspect the cavity. Meticulous dissection and in the correct plane should be the dictum & with minimal use of thermal energy to preserve as much as possible of normal ovarian tissue.

Always look for other areas of endometriosis and treat them as well. In all cases, adequate pre-operative planning should be done to guard against surprises.

#### **Laparoscopic Picture Showing Severe Endometriosis**



DIE- Deep infiltrating endometriosis: cases have to be dealt with by a multidisciplinary approach. DIE is associated with fibrotic changes and distortion of anatomy. Complete cure for pain may require complete excision and may include resection of parts of intestine, ureters & bladder.

Adequate pre-operative discussion explaining the risk of injury to viscera and the possible need for bowel resection /ileostomy/ureterolysis and reimplantation/anastomosis must be explained.

Adequate complete resection of all endometriotic nodules must be ensured as otherwise there is an increased risk of recurrence and repeat surgeries further increase the chances of intestinal & urinary complications.

Pre-operative ureteral stenting may be performed in suspected ureteral/ bladder involvement. Endoscopic access has become the standard for treatment of endometriosis in view of better visualisation & access to lesion in the depths of pelvis.

Adhesiolysis should be performed with scissor/ blunt dissection to minimize collateral thermal spread by energy sources.

Nodules can be mobilized by scissors or low thermal energy sources like CO2 laser, or plasma.

### Hysterectomy

In some cases of endometriosis hysterectomy may be required. Hysterectomy with removal of both ovaries and all visible endometriotic nodules should be done as hysterectomy with ovarian conservation was reported to have a 6 fold increase in the development of recurrent pain and an 8.1 times greater risk of reoperation.

Sometimes Nerve Sparing Laparoscopic Modified Radical Hysterectomy is required for DIE.

Consideration should be given to hormone replacement therapy after hysterectomy. For HRT, tibolone or oestrogen plus progesterone is the preferred choice.

### Endometriosis and Infertility

Endometriosis can cause infertility. Various mechanisms have been postulated

- Altered pelvic anatomy – distorted tubo ovarian relationship can result in infertility

- Altered peritoneal function – increased volume of peritoneal fluid and increased concentrations of prostaglandins, proteases, inflammatory and angiogenic cytokines have been demonstrated in the peritoneal fluid. These alterations may have an adverse effect on the ovum, sperm, embryo or Fallopian tubes
- Altered hormonal and cell mediated function – IgG, IgA antibodies and lymphocytes may be increased in the endometrium of women with endometriosis. These may alter endometrial receptivity and embryo implantation.
- Endocrine and ovulatory abnormalities – it has been postulated that women with endometriosis may have LUFS, luteal phase dysfunction and abnormal follicular growth
- Impaired implantation
- Impaired oocyte and embryo quality
- Altered tubo ovarian transport

Various factors play a crucial role when planning for treatment of infertility with endometriosis. These are-

Age

Tubal factors

Male factors

Previous ovarian surgery

Associated pain

Previous treatment taken

Stage of endometriosis

The treatment of patients of infertility with endometriosis needs to be individualized. Some common tenets of management are-

- Adjunct medical therapy before or after surgery -not recommended to improve pregnancy rates
- Stage 1 and 2 endometriosis with infertility will benefit from laparoscopy. COH with IUI can be contemplated depending upon other associated risk factors like maternal age etc
- Stage 3 or 4 endometriosis - prefer laparoscopy if young age (<35 years), short duration of infertility (<3 years), no other infertility factor, good ovarian reserve (AMH>2.5ng/ml), no history of previous cystectomy
- Stage 3 or 4 endometriosis prefer IVF if advanced age, duration of infertility is long, low ovarian reserve, coexists with other factors, recurrence of cyst after previous cystectomy/ adhesiolysis



To Conclude: Endometriosis is a progressive, hormone dependant Disease of the reproductive age group. It's management is different for differing case scenarios and the treatment should be thus tailored accordingly.

## References

1. Bedaiwy MA, Allaire C, Yong P, Alfaraj S. Medical Management of Endometriosis in Patients with Chronic Pelvic Pain. *Semin Reprod Med.* 2017;35(1):38-53. doi:10.1055/s-0036-1597308
2. Endometriosis: diagnosis and management NICE guideline 2017
3. Catherine B Wykes<sup>1</sup>, T Justin Clark, Khalid S Khan Accuracy of laparoscopy in the diagnosis of endometriosis: a systematic quantitative review *BJOG* 2004 Nov;111(11):1204-12. doi: 10.1111/j.1471-0528.2004.00433.x.
4. Fertility and Sterility® Vol. 98, No. 3, September 2012 0015-0282 Endometriosis and infertility - A committee opinion -The Practice Committee of the American Society for Reproductive Medicine
5. Management of women with endometriosis Guideline of the European Society of Human Reproduction and Embryology ESHRE Endometriosis Guideline Development Group September 2013
6. Rafique S, Decherney AH. Medical Management of Endometriosis. *Clin Obstet Gynecol.* 2017;60(3):485-496. doi:10.1097/GRF.0000000000000292
7. Saeed Alborzi MD et al Diagnostic accuracy of MRI, TVS and TRUS in Deep Infiltrating Endometriosis 2018 Feb 23 doi: 10.1097/MD.00000000000009536
8. Surgical Treatment of Endometriosis. Part 1: Ovarian Endometrioma Working group of ESGE, ESHRE and WES, Human Reproduction Open, Volume 2017, Issue 4, 2017, hox016

## Election Announcement

The election for the post of president of AOGD 2021-2022 has been declared. Due to exceptional circumstances because of the covid 19 pandemic, this year there will be e-voting. However, if in future we plan to have e-voting then there has to be change in the constitution. Following the withdrawal of the nomination of Dr. Asmita Rathore for the post of Vice-President of AOGD 2021-2022. Dr. Jyotsna Suri has been declared Vice president elect of AOGD for the year 2021-2022.

The secretariat of AOGD is in the process of developing data base of its members till 20/11/2020. The members of AOGD will verify their names, mobile numbers and emails address by 30/11/2020.

The election for the post of president AOGD 2021-2022 will be held between 5/12/2020 till 10/12/2020. The result will be declared on 11/12/2020

The Ordinary and Life members of AOGD only will have voting rights. (Ordinary Members and Life Members shall be deemed to be active members of the Association. Ordinary members mean a member who is actively involved in the practice of and/or research in Obstetrics and Gynaecology, Human Reproduction and Family Welfare and is holding a DGO, MD, DNB, MRCOG or DRCOG degree or is holding an equivalent postgraduate degree/diploma recognized by the Medical Council of India Act, 1956 Schedule or by the State Medical Council and any up to date Schedule from time to time as recognized by MCI. Member to be enrolled must have completed his/her post-graduation as recognized by MCI/equivalent body and must have been fully registered with MCI).

The Associate members of AOGD will not have any voting rights. (Associate members are those doing post-graduation in the field of Obstetrics and Gynaecology or postgraduates from allied branches and interested in the science of Obstetrics and Gynaecology and/or Family Welfare will be eligible for registration as Associate Members).

# Laparoscopic Management of Endometriosis (Part 1)

Urvashi Prasad Jha<sup>1</sup>, Neema Sharma<sup>2</sup>, Mamta Mishra<sup>3</sup>

<sup>1</sup>HOD & Director, <sup>2</sup>Director, <sup>3</sup>Director, Fortis Flt Lt Rajan Dhall Hospital

## Introduction

Surgical intervention for endometriosis in the form of laparoscopy is the mainstay of management today. In order to have optimum results for symptom relief and to minimize the chances of recurrence a complete corrective procedure is required.

The “gold standard” of definitive diagnosis of endometriosis also, currently is laparoscopic visualization.<sup>1</sup>

The surgical goals in endometriosis are to remove all visible endometriotic disease, conserve as much ovarian tissue as possible, lyse all adhesions, particularly in patients complaining of painful symptoms, restore anatomy to as near normal as possible and avoid unnecessary tissue trauma.

Biopsy of a lesion with histopathological confirmation of endometriosis is ideal in peritoneal disease but negative histopathology doesn't exclude it<sup>2</sup>. However, in ovarian endometriomas larger than >4cm it is mandatory to have a histopathology and exclude malignancy<sup>3</sup>.

Endometriosis in the abdominopelvic cavity may present as three different entities, peritoneal lesions, deep endometriosis (DE) and ovarian endometriotic cysts (endometriomas).

Preoperative planning of endometriosis surgery is very important.

## Pre-operative Counselling

Counsel about the following possibilities:

Ovarian reserve and compromise from both pathology and surgery.

Preoperative freezing of oocytes should be discussed. IVF could be proposed as the first step particularly in patients who have been operated previously, who have a low ovarian reserve and/or when there is male factor infertility.

Take a fully informed comprehensive consent

For the possibility of appendectomy

Need for cystoscopy, ureteric catheterization & repair

Complication of other organ damage and need for repair like small or large bowel

Need for bowel resection anastomosis and temporary colostomy

Conversion to laparotomy

Post-operative possible use of drains, urinary catheters, stoma

Recurrence or persistence of disease & associated symptoms

Need for repeat laparoscopy/ies/ laparotomy/ hysteroscopy

Lack of pain relief since pain attributed to endometriosis may have another origin.

Risks associated with extensive excisional surgery & morbidity

Possible prolonged hospitalisation/ stay/ICU stay

Excessive blood loss requiring blood transfusion.

Budget issues

## Patient Assessment

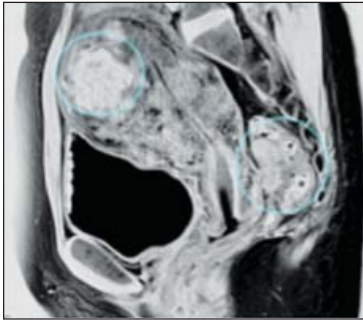
Detailed patient's history is taken. Use direct questioning to ask about uterine bleeding pattern bladder, bowel symptoms, dyspareunia including depression and anxiety to help detect organs involved by endometriosis. Identifying these preoperatively facilitates intra-operative identification & complete excision of disease.

Examination is undertaken to rule out rectovaginal nodule, tender uterosacrals and disease in POD.

Per rectal examination allows the surgeon to evaluate the mobility of the nodule of the dorsal cul-de-sac and thus to predict how difficult the surgery may be and the chances of involvement of a colorectal surgeon.

Pelvic ultrasound and/or MRI is required to determine the number, size and location (unilateral or bilateral) of the cysts, presence of endometriotic nodules, extent of the Pouch of Douglas obliteration, presence of hydronephrosis and level of infiltration of deep endometriosis. MRI is often not necessary to diagnose bladder endometriosis

in addition to TVS, but it can be helpful to identify the relation between the nodule and the ureteral ostia and when additional complex rectovaginal endometriosis is suspected.



**Fig 1:** MRIPicture of the pelvis. dense adhesions between the posterior wall of the cervix and anterior wall of the rectum (right circle) and adenomyosis (left circle)<sup>4</sup>

If rectal bleeding (haematochezia) is reported by the patient, colonoscopy is indicated for differential diagnosis of primary bowel disease. Once the decision to perform surgery has been taken, a contrast enema is important, because it is the only examination that allows evaluation of the degree and length of bowel occlusion at the level of the sigmoid or high rectosigmoid in case of DE.

IVP may be required to rule out non functioning kidney which may be due to ureteral extrinsic endometriosis.

Check ovarian reserve - AMH, AFC (Antral follicular count), FSH, E2

Assess serum tumour markers in case of complex ovarian cystic masses and suspicion of malignancy at imaging. (CA 125, CEA, CA 19.9, HE 4)

### Pre-operative Preparation

Pre-operative pyridium one tablet three times a day for one day is prescribed before the procedure (for coloring and easy identifications of urine).

Peri-operative thromboprophylaxis include low molecular weight heparins, DVT prevention stockings and use of Intermitting Compression Device (ICD) pumps

Bowel preparation, liquid diet, Peglec, laxatives are helpful particularly in case of deep endometriosis. An empty bowel provides more space in the pelvis during the dissection; the use of rectal probes or manipulators in a clean bowel will cause less contamination with faeces on the perineum, especially when the vagina has to be opened. In the

case of opening the bowel, it will minimise faecal soiling of the abdomen.

A bowel surgeon, a urologist, a thoracic surgeon and even a plastic surgeon may need to be involved and should be available on site in case of need.

### Patient's Position

If hysteroscopy is planned with the laparoscopy legs should be in a modified lithotomy position, so that thighs are in a straight line with abdomen to allow easy manoeuvrability of instruments. Patient's buttocks should be just beyond the edge of the table – for manipulation of the uterus and the hysteroscope when dealing with anterior & lateral wall lesions. Patient's hands should be on the sides covered with a towel. Cautery pad should be under the buttocks ensuring wholesome contact of pedal with the patient. Use a high port (Lee-Wang's position) if there are large endometriomas till umbilicus. The author uses a personally modified higher port than the Lee Wang's point.

Pre-operative placement of ureteral stents is suggested when-

1. surgery of large bladder endometriosis is planned
2. ureteral endometriosis is suspected pre-operatively
3. hydronephrosis is present

there is a history of previous ureteral surgery.

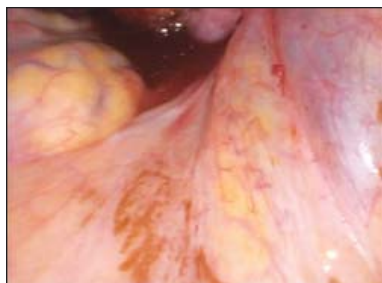
The use of a uterine manipulator achieves maximum mobility of the uterus, thereby improving visualization and facilitating counter traction and dissection. A rectal probe is helpful in moving the bowel. The vaginal probe helps in resection the rectovaginal nodule.

### Intra-operatively

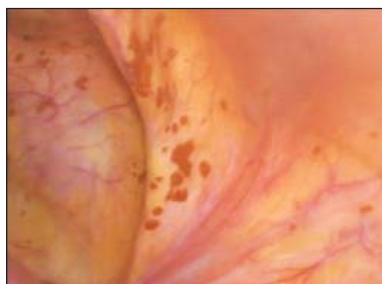The best results are with best efforts at the first surgery. Have patience, allocate enough operating time. Use sharp dissection, particularly with dense fibrotic adhesions at interface with organs, combination of hydrodissection, blunt dissection and peeling. Use plenty of warm saline lavage.

### Peritoneal Endometriosis

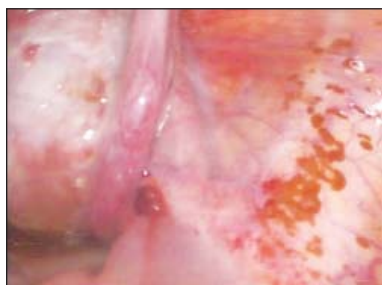A peritoneal lesion that is very small (<2mm) and is clearly superficial may be best treated with bipolar coagulation. To minimize tissue destruction lift the



**Fig 2:** Case of right infundibulopelvic ligament with surface endometrisos



**Fig 3:** Brownish multiple areas of superficial peritoneal endometriosis inthpelvis



**Fig 4:** Peritoneal endometriosis

peritoneum away from the underlying structure. In contrast, a deeply invasive lesion requires use of either excision or ablation. Excision is started by cutting through the peritoneum and into the loose connective tissue with scissors, knife or laser. If there is any lesion in close proximity to the ureter or on the intestine, excision without the use of thermal energy is usually most appropriate.

“Ablation of endometriotic lesions plus adhesiolysis to improve fertility in minimal-mild endometriosis is more effective compared to diagnostic laparoscopy alone” (Evidence level 1a)<sup>1</sup>

The Cochrane Collaboration meta-analysis suggests an improved pregnancy rate (6R 1.66, 95%; CI 1.01-2.51) and a pregnancy continuing beyond 20 weeks (OR 1.64, 95% CI 1.05-2.57), with laparoscopy in these patients<sup>5-7</sup>.

In infertile patients an intraoperative tubal patency testing confirms the status of the tubes.

A simultaneous hysteroscopy and D & C may also provide evidence of associated genital tuberculosis in a small group of patients.

## Ovarian Endometrioma

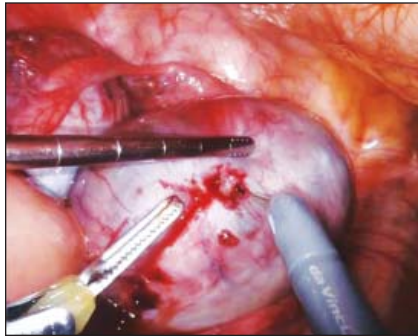
The European Society for Gynaecological Endoscopy (ESGE), the European Society of Human Reproduction and Embryology (ESHRE) and the World Endometriosis Society (WES) have formed a working group to provide a series of recommendations on the practical aspects of the different surgical procedures for the treatment of endometriosis<sup>8</sup>.

### Steps of Laparoscopic surgery

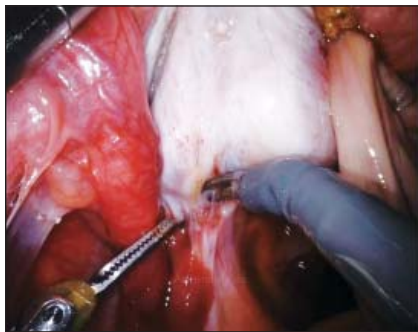
1. Examine the pelvic organs, upper abdomen and appendix.
2. Obtain peritoneal washings
3. Perform meticulous peritoneal adhesiolysis. This is of utmost importance to achieve clearance of underlying endometriotic disease in the abdominopelvic organs. What may seem an unaccessible and unapproachable condition at first glance may gradually unfold to a correctable state with gradual stepwise adhesiolysis. It is always a good idea to start with releasing the descending colon from its physiological or other adhesions to the white line and lateral pelvic wall. Similarly, adhesions of the caecum, appendix and large ovarian endometriomas or adherent sigmoid colon can be lysed. Adhesions of the large or small bowel to posterior surface of the uterine fundus, posterior uterine wall or endometriomas are dissected keeping in mind that the adhesions are deeper and broader under the surface than what they appear to be. As dissection proceeds deeper into the pelvis, it may be necessary to dissect the ureter away from the overlying peritoneum and adjacent bowel or uterosacral ligaments to reach the ovaries and or the fallopian tube.
4. Restore the anatomy. Ovary is separated from the ovarian fossa by adhesiolysis by applying traction in the correct direction. Cysts inadvertently rupture during the process. Extend the opening of the cyst. Multiple incisions and an excessive large opening should be avoided to prevent damaging the ovarian cortex. When the ovary is not adherent, the



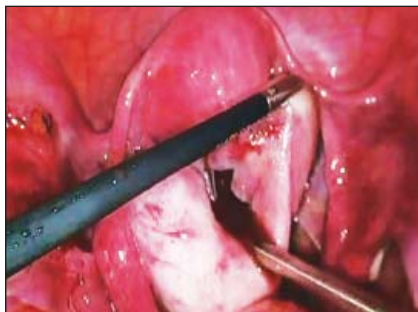
incision should ideally be over the thinnest part of the ovarian endometriotic surface or, if this is not visible, on the antimesenteric border. Irrigate and aspirate thoroughly. After exposing the cyst wall either cystectomy or laser ablation or electrocautery can be performed.



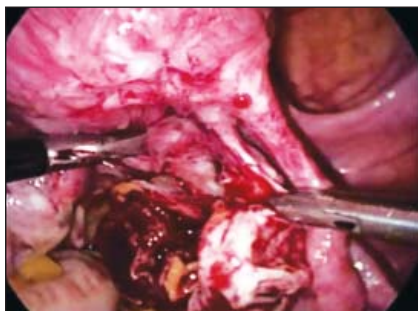**Fig 5:** Incision made on the thinnest part of an endometrioma.



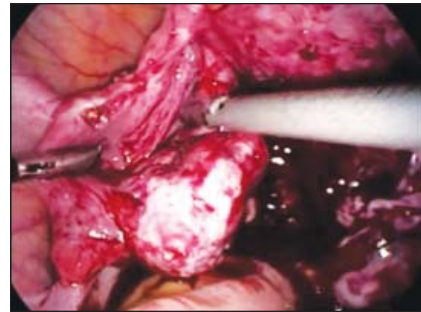
**Fig 6:** Endometrioma being separated from the ovarian fossa



**Fig 7:** Ovarian cyst aspiration



**Fig 8:** Release of ovarian ligament



**Fig 9:** Restoring the tube and ovarian relationship

## 5. Cystectomy

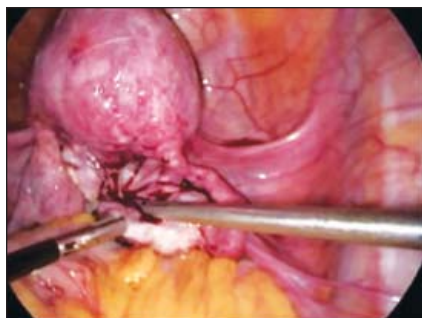Freshen the edges of the cyst wall, identify the capsule. With gentle traction and counter traction the cyst wall is separated from the ovarian parenchyma. Avoid use of excessive force to separate a highly adherent cyst from the ovary, as this will likely cause tearing of the ovarian tissue, excessive bleeding, plus increase the need for coagulation or diathermy, and thus further damage the normal ovarian tissue. The ovarian ligament may require to be pulled up or medially or retracted and should be carefully dissected to avoid bleeding. To aid identification of the cyst wall saline can be injected under the cyst capsule. Look for hidden endometriomas in the depth of the ovary, paravesical space & within the leaves of the broad ligament.

Ensure haemostasis. It may be necessary to reconstruct the ovary in case of big endometriomas by suturing. If a suture is used, it should ideally be placed inside the ovary, as the exposed suture may be prone to adhesion formation. Cyst walls should ideally be removed in a specimen retrieval bag.

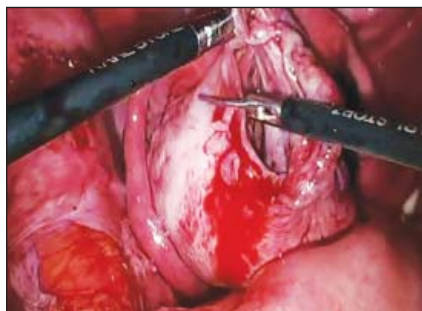Restoring tubo ovarian anatomy is of particular value in patients of infertility by releasing local mini / micro adhesions in the mesosalpinx and meso ovary, over the tubal serosa and at the distal tubal end.

If associated hydrosalpinx exists, which is not often seen in endometriosis, then a salpingectomy (unilateral or bilateral, as appropriate) should be undertaken provided pre-operative discussion and consent has been obtained from both the patient and her partner. The implications of bilateral salpingectomy, in particular can be profound as the only recourse to pregnancy thereafter would be through assisted reproductive techniques.

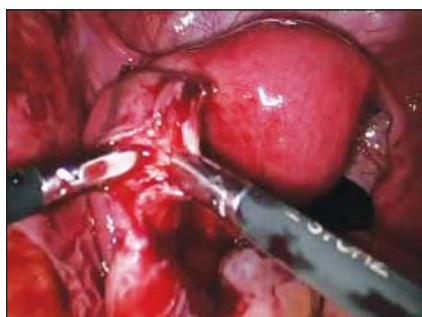



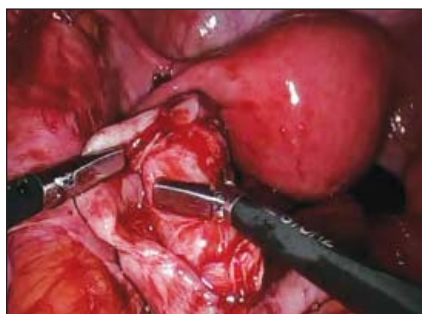**Fig 10:** Release of the ovarian ligament



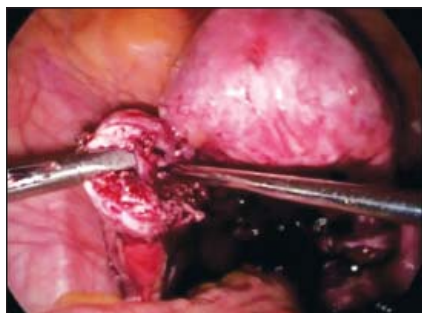**Fig 11:** Freshen the edges of the cyst wall



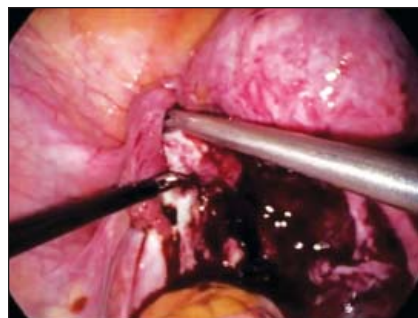**Fig 12:** Identify the cyst wall



**Fig 13:** Traction and counter traction on the cyst wall



**Fig 14:** Hydrodissection of the cyst wall



**Fig 15:** Cyst separated from the ovarian fossa

## 6. Laser Ablation

The entire inner surface of the cyst wall is ablated using the laser beam. Power settings of 30–55 W for CO<sub>2</sub> laser beam and 6–10 W for CO<sub>2</sub> fibre are usually used. The laser should be applied in such a mode that it can ablate the tissue while preserving the underlying healthy tissue. Aim to vaporise the endometriotic cyst lining only until haemosiderin pigment-stained tissue is no longer visible (until the colour changes from reddish to yellow-white). Apply it at an angle perpendicular to the inner surface of the cyst. Use intermittent irrigation to maintain good visibility and to remove carbon debris. This is an effective ovarian tissue sparing technique<sup>9</sup>.

Nevertheless, a large majority of surgeons abandoned ablative techniques 10 reporting better outcomes with stripping techniques with respect to cyst ablation in terms of recurrence of endometrioma and spontaneous pregnancy rates.

## 7. Plasma energy ablation

The entire inner surface of the cyst wall is ablated using plasma energy in the coagulation mode set at 10 to 40, at a distance averaging 5 mm from the tip of the hand piece. Principle is the same as laser coagulation<sup>11</sup>.

## 8. Electrocoagulation

Electrosurgery is widely used for the treatment of ovarian endometrioma. Coagulate the cyst lining systematically using bipolar forceps. 25–40 W setting is frequently used. The key point is to use very short coagulation times to minimise ovarian tissue damage, as the depth of the destruction can be difficult to judge. Spray coagulation or fulguration techniques with monopolar energy are also useful and minimize damage of underlying ovarian tissue.

### 9. Combined technique

A combined technique using both excision and ablation can be used to prevent excessive bleeding and ovarian tissue removal/damage from the ovarian hilum, particularly for larger endometriomas. Open and drain the cyst followed by identification of the cleavage plane, as described above. Strip 80–90% of the cyst wall and perform a partial cystectomy, as described above, up to the ovarian hilum. Laser, plasma energy or bipolar can then be applied to treat the remaining endometriotic tissue (10–20%).

### 10. Two- or three- step approach for large endometriomas

For large endometriomas, a two- or three-step procedure may be considered. The

first step involves opening and draining the endometrioma, inspecting the cyst cavity and taking a biopsy. Administer a GnRH agonist (GnRHa) therapy for 3 months, during which time the thickness of the cyst wall significantly decreases with atrophy and reduction in stromal vascularisation of the cyst.<sup>12</sup>

Complete the surgery with a second laparoscopy in the form of either cystectomy, CO2 vaporisation, bipolar diathermy or plasma ablation of the cyst wall lining. Although women have to undergo two invasive procedures, the potential benefit is that this may facilitate the management of larger ovarian endometriomas, reduce recurrence rates and limit decrease in ovarian reserve.

## Calendar of Virtual Monthly Clinical Meetings 2020-21

29 <sup>th</sup> May, 2020	B L Kapoor Hospital
26 <sup>th</sup> June, 2020	VMMC & Safdarjung Hospital
31 <sup>st</sup> July, 2020	AIIMS
14 <sup>th</sup> August, 2020	Lady Hardinge Medical College
28 <sup>th</sup> August, 2020	Army Hospital- Research & Referral
11 <sup>th</sup> September, 2020	Apollo Hospital
25 <sup>th</sup> September, 2020	DDU Hospital
23 <sup>rd</sup> October to 6 <sup>th</sup> November, 2020	AOGD Annual Conference Activities
27 <sup>th</sup> November, 2020	MAMC & LNJP Hospital
18 <sup>th</sup> December, 2020	Sir Ganga Ram Hospital
1 <sup>st</sup> January, 2020	ESI Hospital
29 <sup>th</sup> January, 2021	Dr RML Hospital
26 <sup>th</sup> February, 2021	UCMS & GTB Hospital
26 <sup>th</sup> March, 2021	Lady Hardinge Medical College
23 <sup>rd</sup> April, 2021	Apollo Hospital

# Laparoscopic Management of Deep Infiltrating Endometriosis (Part 2)

Urvashi Prasad Jha<sup>1</sup>, Neema Sharma<sup>2</sup>, Mamta Mishra<sup>3</sup>

<sup>1</sup>HOD & Director, <sup>2</sup>Director, <sup>3</sup>Director, Fortis Flt Lt Rajan Dhall Hospital

## Deep Endometriosis (DE)

Working group comprising members of the European Society for Gynaecological Endoscopy (ESGE), ESHRE and the World Endometriosis Society (WES) group has defined DE as the involvement of endometrial-like tissue with a depth of more than 5 mm beyond the peritoneum. It may involve the uterosacral ligaments, the vagina, the bowel, the bladder and the ureters. Surgical removal of rectovaginal DE lesions is required when lesions are symptomatic, impairing bowel, urinary, sexual and reproductive functions. Medical treatment of rectovaginal DE can reduce the symptoms but does not cure the disease<sup>13</sup>.

The most commonly used classification system of endometriosis, the rASRM classification, does not provide sufficient information for DE; correlation with symptoms is poor, and it does not predict surgical difficulty level or outcome.<sup>14</sup>

The ENZIAN classification showed a significant correlation between the extent of the disease, difficulty and length of surgery and symptoms.<sup>15-18</sup>

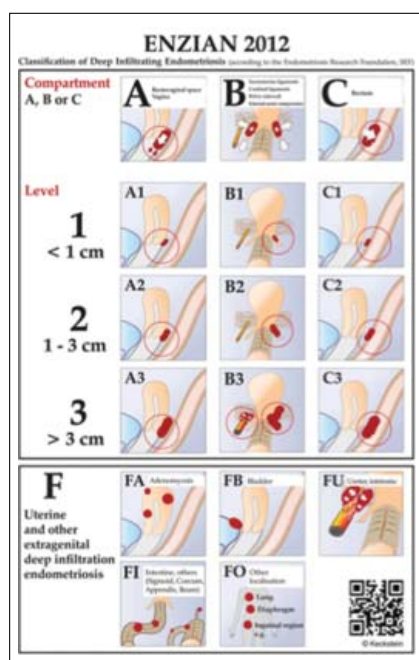


Fig 16: xxx

**Revised ENZIAN classification for DE.** The system classifies the clinical findings of endometriosis according to their localisation (compartment) and size (<1 cm, 1–3 cm, >3 cm). The ENZIAN classification focusses on the three dimensions (compartments) in the pelvis: A = craniocaudal axis or compartment (rectovaginal space, vagina), B = laterodorsal axis (uterosacral and cardinal ligaments), C = dorsal axis (rectosigmoid). Other localisations as uterus, bladder, ureter, other bowel involvement and extragenital localisations are respected as well and described with suffix F). The ENZIAN Classification is under revision (2019) again and is under publication.

## Steps of Surgery for DE

1. During the surgery, three manipulators (Uterine, vaginal and rectal) can be mobilized individually in order to help identify the limit between the vagina, the rectal wall, and other pelvic structures.
2. Mobilize the fixed ovaries on the pelvic side wall. Endometrioma is drained and managed.
3. Suspend the ovaries with sutures or special device like a T lift which enhances accessibility to the ovarian fossa and the pararectal spaces.
4. Retroperitoneal dissection of the ureters is done and should be followed upto the cardinal ligament. If hydronephrosis was missed before surgery, a ureteral stent should be placed.
5. Pararectal spaces are opened longitudinally, medially from the uterosacral ligaments, and as close to the lateral side of the bowel as possible in order to avoid injury to the hypogastric and splanchnic nerves. The end result should see the endometriotic nodule remaining attached to the central part between the bowel and the uterus. Pushing the uterus into anteversion will elevate the nodule with the bowel hanging from it. Dissection is continued until the opening of the healthy rectovaginal space.
6. An alternative surgical technique named 'the

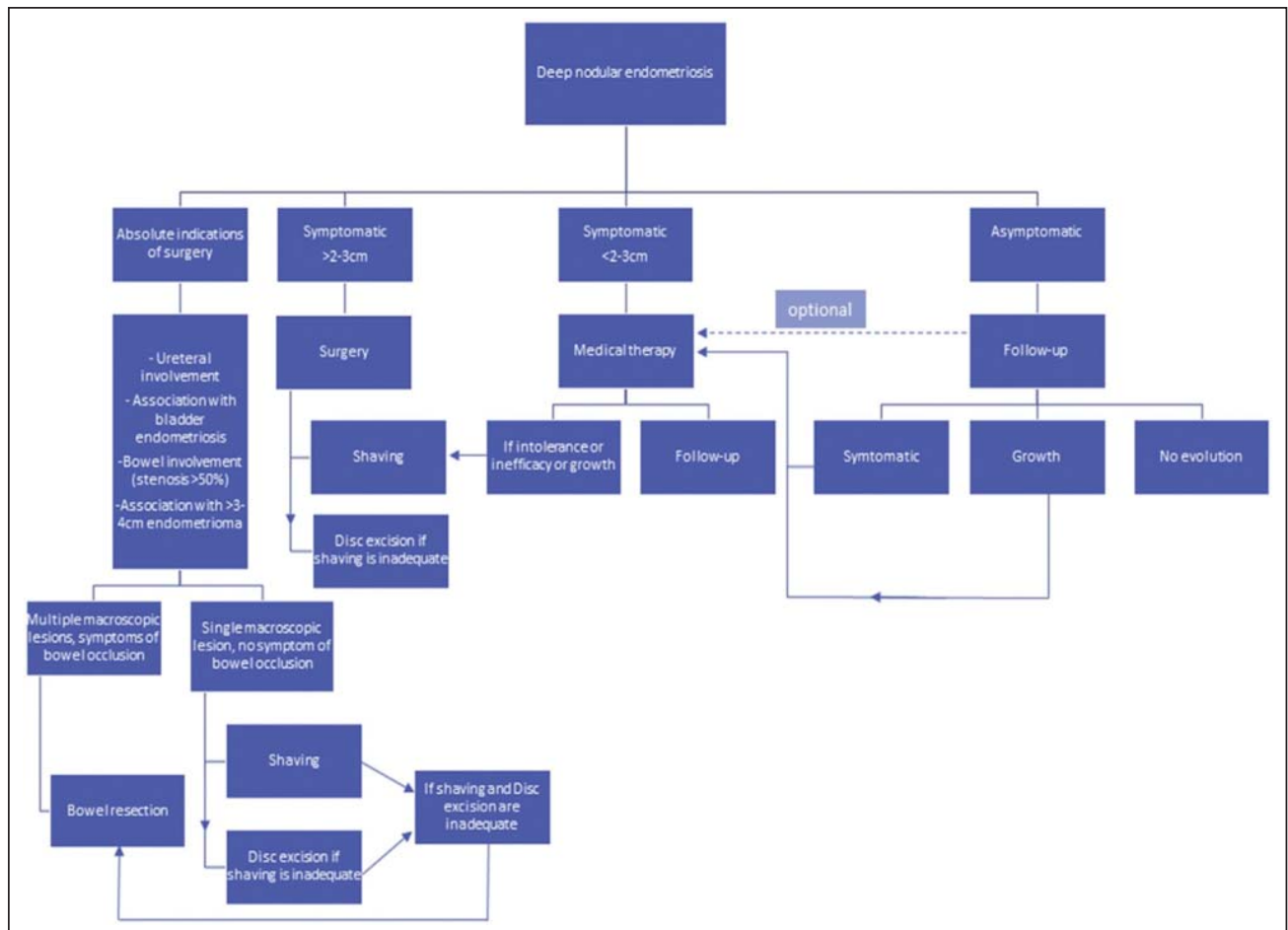


Fig 17: Algorithm for surgical management of rectovaginal DE<sup>23</sup>.

reverse technique' can also be applied, in which the DE lesion is separated first from the cervix and the vagina and only in a second stage from the rectum.<sup>19,20</sup> The removal of the nodule from the mobilized rectum can be facilitated with a probe or sponge inserted transanally into the lumen.

7. In case of bowel infiltration, several procedures could be considered subject to the consent of the woman with the disease characterization and extent.<sup>21,22</sup>

#### 8. Rectal shaving

Once the lateral sides of the rectum are freed, rectal shaving is performed on the ventral wall of the rectum to remove the endometriotic lesion completely. Any damage to the bowel should be identified by gently stretching the bowel over the rectal manipulator to identify thinned areas. Another method to detect leakage is to administer air into the rectal lumen while the pelvis is filled with water or to fill the bowel with diluted methylene blue.

In the case that a muscularis/partial thickness defect is identified, this can be sutured in one layer by using absorbable sutures along the healthy margins. In the case of a full thickness defect (opening of the mucosa), a two-layer technique or a conversion to disc excision using a transanal stapler, which provides a tight stapled line involving healthy rectal wall, is suggested.

#### 9. Discoid excision

If the rectal wall is still infiltrated by implants of DE after shaving, it will appear hollow, rigid and thickened when palpated with a laparoscopic probe and/or a rectal probe. The semi-circular stapler allows large discoid excision (5–6-cm diameter on average) when the shaved area is located between 8 and 10 cm above the anus. The end-to-end circular stapler can also be used to remove discoids up to 3 cm in diameter located in the upper rectum and rectosigmoid junction.



## 10. Colorectal resection.

Mobilization of the rectum is carried out at least 20 mm below the rectal nodule. The proximal dissection line is close above the lesion. Mobilisation and dissection of the bowel from the mesorectum and mesocolon are performed in contact with the dorsal wall of the rectosigmoid, which offers the possibility to preserve the mesorectum and mesosigma. This technique is used especially for short segments and if no other extraperitoneal structures are involved. When preparing the intestine this way, care must be taken not to damage the microvasculature of the intestinal wall from thermal injury and inadvertent damage to its blood supply.<sup>24</sup>

## 11. Complications

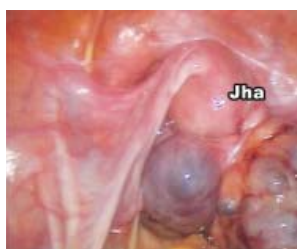A national snapshot of the surgical management of deep infiltrating endometriosis of the rectum and colon has been performed in France including a total of 1135 patients from 56 health care facilities.<sup>25</sup> Rectal shaving was performed in 48.1% of cases, disc excision in 7.3%, colorectal segmental resection in 40.4%, and sigmoid colon segmental resection in 6.4%. Complications such as anastomotic leakage occurred in 0.8% of cases, pelvic abscess in 3.4%, and rectovaginal fistula in 2.7%. The rate of rectovaginal fistula in patients managed by

disc excision (3.6%) or segmental resection (3.9%) was noted to be 3 times higher than the rate described in patients who underwent the shaving (1.3%).

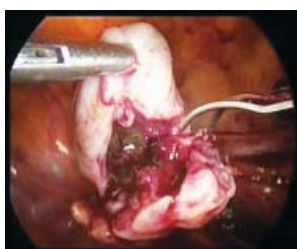Among a series of 568 women undergoing surgery for deep endometriosis, Kondo et al<sup>26</sup> observed a conversion rate of 2.3% and postoperative major complications in 9.3%. In this large series, 40% of the patients underwent rectal surgery as follows: rectal shaving was performed in 32.2% (n 1/4 183), excision of rectal lesion and suture in 3% (n 1/4 17), and segmental bowel resection in 4.4% (n 1/4 25). The rate of major postoperative complications was found to be lower in the shaving group (6.7%) than in the segmental resection group (24%). According to these results, the authors concluded that surgery for deep endometriosis is associated with major complications regardless of the type of rectal surgery.

## Post Procedure and Postoperatively

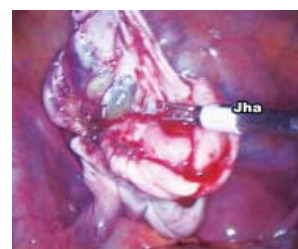1. Check Rectal integrity with a Toomey's syringe or Foley's catheter to pump in Air/methylene blue.
2. Use adhesion prevention barriers such as Interceed or Seprafilm
3. Antibiotics are given as one shot when the vagina has been opened, whereas full-



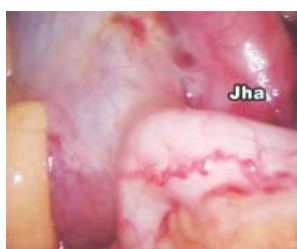**Fig 18:** Endometriomas with adhesions in pouch of Douglas



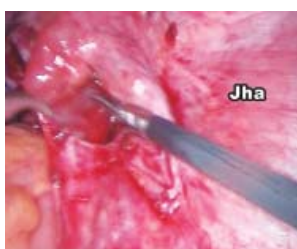**Fig 19:** Small multiple endometriomas dissected



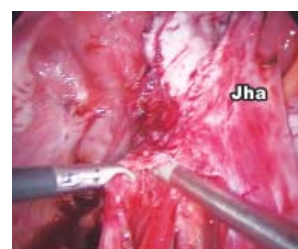**Fig 20:** Peeling of large endometriotic cyst wall in progress; Cautery vessel on the side of the cyst wall rather than ovarian surface



**Fig 21:** Adherent appendix to endometrioma



**Fig 22:** Retroperitoneal dissection of ureter

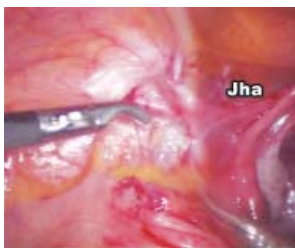

**Fig 23:** Retroperitoneal dissection of ureter enables safer excision of endometriotic disease in the area

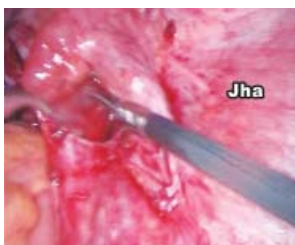thickness resection requires 7 days of antibiotic treatment. Following a muscularis defect and single-layer suture, or full-thickness resection and double-layer suture, the patient remains nil by mouth for 4 and 7 days, respectively.

4. Deep endometriosis surgery is associated with urinary retention and/or bladder dysfunction. Urinary retention generally resolves within a few weeks, occasionally after as long as 9 months
5. Watch for signs and symptoms of bowel perforation. Computed tomographic scan can be helpful, an early repeat laparoscopy is recommended whenever in doubt. If performed within 24 hours after perforation, treatment can be conservative with a bowel suture and lavage. If a perforation is missed and diagnosed after 24 hours, four-quadrant peritonitis will be found, necessitating a thorough peritoneal lavage and colostomy.
6. Check AMH, FSH, E2.
7. Use postoperative thromboprophylaxis.
8. Use GNRH etc for treating remaining micro-disease, unresectable disease and to down regulate the ovary.
9. Check tubal patency (from adhesiolysis) after surgery.
10. Perform IUI/IVF sooner rather than later if appropriate.

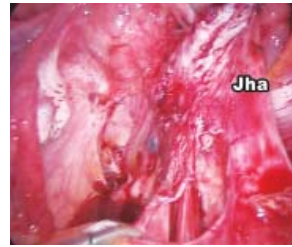*The retroperitoneal approach in advanced endometriosis*



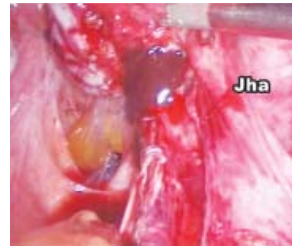**Fig 24:** Entering the retroperitoneal sapce



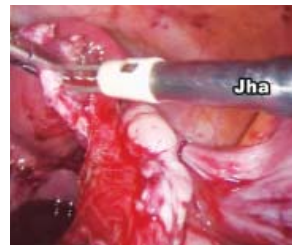**Fig 25:** Broad ligament opening up



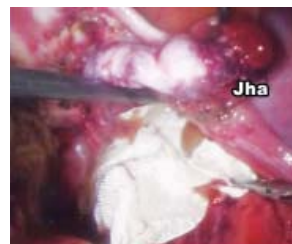**Fig 26:** Retroperitoneal ureteric dissection



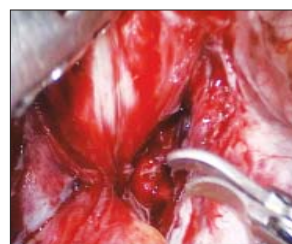**Fig 27:** Otherwise unidentified small, buried endometriomas are seen ruptured when retroperitoneal dissection



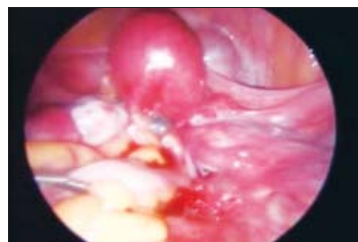**Fig 28:** With ureter dissected, electrocautery for hemostasis is safe



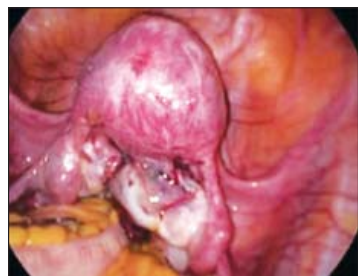**Fig 29:** Covering the dissected-raw area with interceed with a view to adhesion prevention



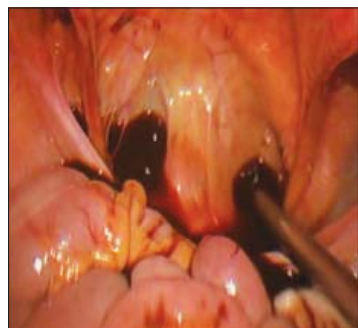**Fig 30:** Sharp dissection at the rectovaginal septum



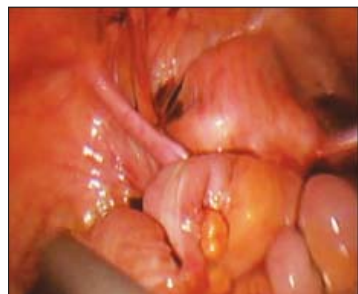**Fig 31:** Frozen pelvis at first glance and initial assessment



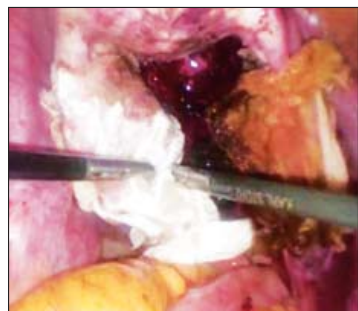
**Fig 32:** Kissing ovaries



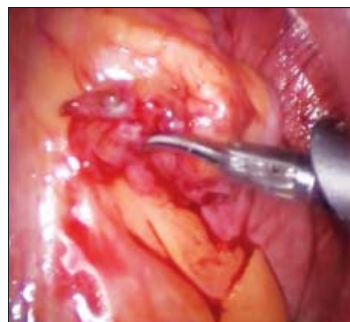**Fig 33:** Haemorrhagic ascitis with frozen pelvis



**Fig 34:** Frozen pelvis with adhesions between colon and uterine fundus preventing visualization of pelvis structures



**Fig 35:** Interseed as adhesive barrier



**Fig 36:** Appendix with endometriosis

## Endometriosis of the Urinary Tract

Urinary tract DIE may be found in up to 6% of women presenting with pelvic endometriosis and may involve either the bladder or ureters.<sup>27</sup>

Ureteral endometriosis is most commonly unilateral, involving a small segment of distal left ureter and often represented by a perureteric ring.<sup>28</sup> It may be intrinsic or extrinsic, depending on whether the uroepithelium and submucosal layer of the ureteral wall are infiltrated. Extrinsic compression of the ureter appears to be more common than intrinsic disease. Ureteral involvement is usually due to the lateral spreading of deep endometriosis primarily infiltrating the rectovaginal space or the uterosacral ligaments, and is associated in two-thirds of cases with ipsilateral ovarian endometriomas. When ureterolysis is insufficient for the removal of ureter stenosis, ureteral resection is immediately performed with either end-to-end ureteral anastomosis or ureterocystoneostomy. Performing a retroperitoneal dissection of the ureters right up to the level of the extrinsic compression with excision of the fibrotic endometriotic tissue is recommended. If the muscularis of the ureter gets damaged in the process, an intra-ureteric stent must be placed in situ. Using ureteric catheterization routinely is not considered necessary in milder cases because stiffening of the ureter may make dissection more difficult and predispose to ureteric injury.

Progressive ureteral stenosis may be responsible for the destruction of the renal parenchyma and gradual kidney function loss. This can be preoperatively estimated by renal scintigraphy. If kidney function is lost, a nephrectomy may need to be undertaken. That the kidney has been preoperatively affected must be demonstrated in the pre-operative period itself or immediately after



surgery to prevent blame from intraoperative damage to the kidney from asymptomatic postoperative renal atrophy.

In patients with the intrinsic involvement of the ureter, complete excision of the involved area with end-to-end ureteric anastomosis, creation of a Boari flap, and re-implantation of the ureter may be necessary.

Bladder endometriosis usually presents as an adenomyotic nodule originating from the anterior uterine wall and peritoneum, progressing forward toward the bladder, which it covers at the submucosal and mucosal layer. Both are infiltrated and pushed into the bladder cavity, eventually becoming visible on cystoscopy. Symptomatic bladder DE requires the complex excision of the nodule and hollowing out of the nodule of the myometrium. Complete removal of bladder endometriosis is usually possible, but that of the uterus may not be so. Surgical management should be performed by an experienced multidisciplinary teams involving the urologist and the gynecologist.

Double-J ureteral stents should be inserted either pre- or intra-operatively in these circumstances. Ureterolysis is considered satisfactory when the fibrous ring surrounding the ureter is completely removed to a point where the remaining ureter appears distally normal.

Cystoscopy is performed followed by ureteric stenting. On laparoscopy the bladder nodule may be visible, or the round ligaments may be pulled medially, obliterating the ventral compartment due to fibrosis. Dissection begins between the bladder and the uterus and the anterior vaginal wall, opening the vesicovaginal space upto the distal border of the nodule which is indicated by the soft characteristic of connective tissue. However, the tissue planes may sometimes be lost due to the disease, and the dissection may have to go through fibrotic tissue. The bladder is further mobilized from both sides and the Retzius space may be opened to ensure subsequent suturing without tension. Dissection is a little easier when the bladder is filled with 100cc saline. Once the nodule is identified it is excised making sure all the fibrotic tissue around it is removed after opening the bladder and visualizing the trigone. After resection, the bladder defect is closed horizontally with a running suture using 3-0 PDS, or another absorbable monofilament material

### Postoperatively

1. The transurethral Foley catheter should remain in place for 8 to 10 days. Then, a radiological cystogram is highly recommended to check the integrity of the suture.
2. Ultrasound KUB with residual urine should be performed before discharge.
3. Ureteral stents can be removed after 6 weeks after correction of ureteral endometriosis and 1 week after bladder endometriosis
4. Postoperative medical treatment to induce prolonged amenorrhea is a good idea in patients who do not intend to conceive.

### Complications

1. A typical risk of partial bladder resection is secondary haemorrhage with bladder tamponade (i.e. large intravesical hematoma).
2. Postoperative hydronephrosis may occur by accidental occlusion of the ureteral ostia

## Procedures Specific to Treating Pelvic Pain

### Laparoscopic Uterine Nerve Ablation

There are now randomized, clinical trials that quite clearly show that laparoscopic uterine nerve ablation (LUNA) has no role in the treatment of pelvic pain or of endometriosis-associated pelvic pain.<sup>29,30</sup> For endometriosis treatment, Laparoscopic uterine nerve ablation does not improve dysmenorrhea, dyspareunia, or nonmenstrual pelvic pain. LUNA should not be performed for endometriosis-associated pelvic pain.

### Presacral Neurectomy

This has been investigated in two randomized trials as an adjunctive procedure to conservative surgery. In both studies, there was a significant and substantial decrease in midline menstrual pain but no effect on other types of pain.

There is insufficient evidence to recommend the use of surgical pelvic neuroablation in the management of dysmenorrhea, regardless of cause.<sup>31</sup> It has been shown that complete excision of endometriotic disease relieves the pain effectively, whether or not associated with LUNA.



## Recurrence of Endometriosis After Surgical Intervention

Recurrence rates after surgery are 20–30% at 2 years with greater frequency in younger patients, with larger cysts, receiving medical treatments and not conceiving.<sup>32</sup> In patients who have recurrence of endometriosis without achieving pregnancy, after having had a previous surgery, the options are either repeat surgery, ultrasound-guided aspiration with or without sclerotherapy or IVF-ET. The decision to undertake a particular option should be individualized after a fully informed counseling session with the couple about the pros and cons of each option. In older women, the advantage of IVF is that it can be performed without further delay and would tackle multiple co-existent infertility issues, if present. However, more than one IVF cycle would be required to achieve the same results as repeat surgery.

Surgery would not increase the risk of multiple pregnancies. The concern that repeat surgery may lead to decreased pregnancy rates has not been validated. The 5-year cumulative pregnancy rate after the first surgery was seen to be 40.8% versus 32.4% after the second surgery.<sup>33</sup> On the other hand, the 'effect of repetitive laparoscopic surgery is similar to that observed after first-line surgery'. These pregnancies are usually obtained by means of ART.

It must be borne in mind that re-operations are technically more complex and should be undertaken by really experienced laparoscopic surgeons. Although the ASRM Guidelines recommend IVF-ET as a better option to repeat surgery, feel the final decision should be taken also considering the presence of pain and other symptoms and large (>4 cm) endometriomas.

Endometrioma aspiration may predispose to ovarian abscess necessitating oophorectomy, and sclerotherapy may cause pelvic adhesions.<sup>34</sup> More data are needed to make definitive grade A recommendations. Hence, management should be tailored to each patient's circumstances.

## Conclusions

### Ten Commandments for Surgical Management of Endometriosis

1. "The laparoscopic diagnosis of endometriosis should be made earlier rather than later", both in infertile patients and those with pain. Hence,

the threshold to perform the gold standard of diagnosis – laparoscopy should be low. A hysteroscopy should be performed concurrently to exclude associated genital tuberculosis (TB). The therapeutic laparoscopic procedure should ideally be undertaken at the same sitting.

2. The magnification offered at laparoscopy greatly facilitates near complete clearance of macroscopic disease using the endoscopic approach. "Operative laparoscopy has become the 'gold standard' of surgical treatment of endometriosis today" with all its obvious benefits.
3. In India, in view of the high prevalence and "association of genital Kochs", its presence should be actively looked for.
4. At laparoscopy, all efforts should be made to "achieve complete clearance of endometriosis as far as possible, in the first attempt itself". Laparoscopic surgery should be performed by experienced, meticulous surgeons with great degree of patience and diligence. Lesser experienced laparoscopic gynaecological surgeons must actively seek mentoring at surgery to develop their own skills when dealing with this disease that has such poor outcomes.
5. "Meticulous, complete documentation" should be maintained and shared with the patient.
6. "Pre-operatively, detailed counseling" should take place. A well thought out plan should be discussed with the patient interest, safety and best outcome. This plan should be time bound.
7. "A fully informed decision should be taken" by the patient jointly with her gynaecologist and IVF specialist, in those with infertility.
8. "The laparoscopic infertility expert and IVF specialist" should have complete synchrony in their approach and simultaneously follow ups planned at predetermined intervals with each of these.
9. "Ovarian reserve should be tested pre and post-operatively in such patients".
10. The presence of Deep endometriosis, is a real challenge to achieving complete excision, despite all advances in surgical techniques and improved surgical experiences worldwide. If indicated DE should be tackled laparoscopically at the same time with a multidisciplinary approach, as appropriate.

## Bibliography

1. [http://www.eshre.eu/guidelines\\_and\\_legal/page.aspx/16](http://www.eshre.eu/guidelines_and_legal/page.aspx/16).
2. Prasannan-Nair C, Manias T, Mathur R. Management of endometriosis related subfertility. *The Obstetrician & Gynaecologist* 2011;13:1–6.
3. American Fertility Society. Classification of endometriosis. *Fertil Steril* 1979;32: 633–4..
4. Human Reproduction Open, pp. 1–25, 2020
5. Parazzini F. Ablation of lesions or no treatment in minimal-mild endometriosis in infertile women: a randomized trial. Gruppo Italiano per lo studio dell'Endometriosi. *Hum Reprod* 1999;14: 1332–4.
6. Al-Inany HG. Evidence may change with more trials: concepts to be kept in mind. *Hum Reprod* 2000;15:2447–9.
7. Al-Inany H. Laparoscopic ablation is not necessary for minimal or mild lesions in endometriosis associated subfertility. *Acta Obstet Gynecol Scand* 2001;80:593–5.
8. Human Reproduction Open, pp. 1–6, 2017
9. Roman H, Auber M, Makdad C, Martin C, Diguët A, Marpeau L, Bourdel L. Ovarian endometrioma ablation using plasma energy versus cystectomy: a step toward better preservation of the ovarian parenchyma in women wishing to conceive. *Fertil Steril* 2011;96:1396–1400.
10. Johnson NP, Hummelshoj L, World Endometriosis Society Montpellier C. a. Consensus on current management of endometriosis. *Hum Reprod* 2013;28:1552–1568.
11. Roman H, Auber M, Bourdel N, Martin C, Marpeau L, Puscasiu L. Postoperative recurrence and fertility after endometrioma ablation using plasma energy: retrospective assessment of a 3-year experience. *J Minim Invasive Gynecol* 2013;20:573–582.
12. Donnez J, Nisolle M, Gillet N, Smets M, Bassil S, Casanas-Roux F. Large ovarian endometriomas. *Hum Reprod* 1996;11:641–646.
13. Koninckx PR, Ussia A, Adamyan L, Wattiez A, Donnez J. Deep . endometriosis: definition, diagnosis, and treatment. *Fertil Steril* 2012;98:564–571.
14. Johnson NP, Hummelshoj L, Adamson GD, Keckstein J, Taylor HS, Abrao MS, Bush D, Kiesel L, Tamimi R, Sharpe-Timms KL *et al.* World Endometriosis Society consensus on the classification of endometriosis. *Hum Reprod* 2017;32:315–324.
15. Haas D, Chvatal R, Habelsberger A, Schimetta W, Wayand W, Shamiyeh A, Oppelt P. Preoperative planning of surgery for deeply infiltrating endometriosis using the ENZIAN classification. *Eur J Obstet Gynecol Reprod Biol* 2013a;166:99–103.
16. Haas D, Shebl O, Shamiyeh A, Oppelt P. The rASRM score and the Enzian classification for endometriosis: their strengths and weaknesses. *Acta Obstet Gynecol Scand* 2013b;92:3–7.
17. Haas D, Wurm P, Shamiyeh A, Shebl O, Chvatal R, Oppelt P. E cacy of the revised Enzian classification: a retrospective analysis. Does the revised Enzian classification solve the problem of duplicate classifica- tion in rASRM and Enzian? *Arch Gynecol Obstet* 2013c;287:941–945.
18. Morgan-Ortiz F, Lopez-de la Torre MA, Lopez-Zepeda MA, Morgan- . Ruiz FV, Ortiz-Bojorquez JC, Bolivar-Rodriguez MA. Clinical characteristics and location of lesions in patients with deep infiltrating endometriosis using the revised Enzian classification. *J Turk Ger Gynecol Assoc* 2019;20:133–137.
19. Kondo W, Bourdel N, Jardon K, Tamburro S, Cavoli D, Matsuzaki S, . Botchorishvili R, Rabischong B, Pouly JL, Mage G *et al.* Comparison . between standard and reverse laparoscopic techniques for rectovagi- . nal endometriosis. *Surg Endosc* 2011;25:2711–2717.
20. Bourdel N, Comptour A, Bouchet P, Gremeau AS, Pouly JL, Slim K, . Pereira B, Canis M. Long-term evaluation of painful symptoms and . fertility after surgery for large rectovaginal endometriosis nodule: a . retrospective study. *Acta Obstet Gynecol Scand* 2018;97:158–167.
21. Abrao MS, Borrelli GM, Clarizia R, Kho RM, Ceccaroni M. Strategies for Management of Colorectal Endometriosis. *Semin Reprod Med* 2017;35:65–71.
22. Donnez O, Roman H. Choosing the right surgical technique for deep endometriosis: shaving, disc excision, or bowel resection? *Fertil Steril* 2017;108:931–942.
23. Donnez. Surgery for deep rectovaginal endometriosis. *Fertil Steril* 2017.
24. Hudelist G, Aas-Eng MK, Birsan T, Berger F, Sevelde U, Kirchner L, Salama M, Dauser B. Pain and fertility outcomes of nerve-sparing, full-thickness disk or segmental bowel resection for deep infiltrating endometriosis-a prospective cohort study. *Acta Obstet Gynecol Scand* 2018;97:1438–1446.
25. Roman H. A national snapshot of the surgical management of deep infiltrating endometriosis of the rectum and colon in France in 2015: a multicenter series of 1135 cases. *J Gynecol Obstet Hum Reprod* 2017;46(2):159e65.
26. Kondo W, Bourde IN, Tamburro S, Cavoli D, Jardon K, Rabischong B, *et al.* Complications after surgery for deeply infiltrating pelvic endometriosis. *BJOG* 2011;118(3):292e8.
27. Nezhat CR, Nezhat F, Admon D, *et al.* Laparoscopic management of genitourinary endometriosis. *J Am Assoc Gynecol Laparosc* 1994; 1:S25.
28. Bosev D, Nicoll LM, Bhagan L, *et al.* Laparoscopic management of ureteral endometriosis: the Stanford University Hospital experience with 96 consecutive cases. *J Urol* 2009;182:2748–52.
29. Sutton C, Pooley AS, Jones KD, *et al.* A prospective, randomized, double-blind controlled trial of laparoscopic uterine nerve ablation in the treatment of pelvic pain associated with endometriosis. *Gynaecol Endosc* 2001;10:6.
30. Vercellini P, Aimi G, Busacca M, *et al.* Laparoscopic uterosacral ligament resection for dysmenorrhea associated with endometriosis: result of randomized, controlled trial. *Fertil Steril* 2003;80:310–9.
31. Johnson N, Wilson M, Farguhar C. Surgical pelvic neuroablation for chronic pelvic pain: a systematic review. *Gynaecological Endoscopy* 2000;9:351–61.
32. Barri PN, Coroleu B, Tur R, *et al.* Endometriosis-associated infertility: surgery and IVF, a comprehensive therapeutic approach. *Reprod Biomed Online* 2010;21:179–85.
33. Vercellini P, Somigliana E, Vigano P, *et al.* Surgery for endometriosis- associated infertility: a pragmatic approach. *Hum Reprod* 2009;24.2:254–69.
34. Muzii L, Marana R, Caruana P, *et al.* Laparoscopic findings after transvaginal ultrasound-guided aspiration of ovarian endometriomas. *Hum Reprod* 1995;10:2902–3.

# Surgical Approach to Adenomyosis

**Punita Bhardwaj<sup>1</sup>, Harshad Virani<sup>2</sup>, Puja Singh<sup>3</sup>**

<sup>1</sup>Senior Consultant, Gynaecology Endoscopy & Robotics Unit, Sir Ganga Ram Hospital, New Delhi

<sup>2,3</sup>PG Gynaecology Endoscopy

Adenomyosis is a benign condition of the uterus. Presence of endometrial glands and stroma within the myometrium is characteristic of the disease pathology.

- It was described by Austrian pathologist **C.F. Von Rokitansky** in the year 1860.<sup>1</sup>
- Proposed theories of pathogenesis of uterine adenomyosis are -
- Wolffian body theory by **F Von Recklinghausen** in 1893<sup>2</sup>
- Mucosal invading theory by **T Cullen** in 1896<sup>3</sup>
- Mullerian duct hypothesis by **R Kossmain** in 1897<sup>4</sup>
- Serosa extending theory by **NS Iwanoff** in 1898<sup>5</sup>
- Epithelial heterotopy theory by **R Meyer**<sup>6</sup>
- Deep infiltrating endometriosis and adenomyosis have hormonal<sup>7</sup>
- Immunological<sup>8</sup> genetic<sup>9</sup> pathways which are common to both.
- Invasion of endometrium into myometrium is adenomyosis

It is diagnosed when glandular invasion is beyond 2.5 mm of endomyometrial junction<sup>10</sup> Or when the adenomyotic foci distance from the endomyometrial junction is 25% of total myometrial thickness<sup>11</sup>, smooth muscle hyperplasia is present around an adenomyotic foci<sup>12</sup>

Posterior Uterine wall is more commonly involved.

## Incidence

Varies widely 5.7% to 69.6%<sup>13</sup>

## Symptoms

Large proportion of patient are asymptomatic.

Majority had menorrhagia not associated with depth of invasion 62%, dysmenorrhoea associated with depth of invasion 42%<sup>14</sup>, dyschezia, mictalgia, subfertility in younger women.

## Classification of Adenomyosis

**Thomas Cullen**<sup>3</sup> in 1908 classified adenomyosis as focal and diffuse lesions.

Diffuse lesion is associated with multiple spots of adenomyosis within the myometrium.<sup>13</sup> Focal lesions are islands of ectopic endometrium and hypertrophic myometrium merging with surrounding myometrium.

In 2012 **G. Benaggiano** et al brought back the focus on classification<sup>14</sup>

In 2014 **G Grimbizis** et al based on clinical and histological variance suggested a classification<sup>16</sup>

Diffuse, focal adenomyomas, cystic juvenile adult, polyploid (typical atypical), endocervical and retroperitoneal.

New Sonographic classification of adenomyosis Table below<sup>17</sup> Ultrasound score system used to classify the severity of Adenomyosis

## This emphasizes several important issues –

- Types of diseases –diffuse, focal adenomyomas using ultrasound (TVS)
- Adenomyosis further divided by area of involvement of myometrium (external/ internal)
- Depth of disease in the uterus quantified through a schematic scoring system

## Diagnosis

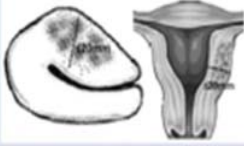











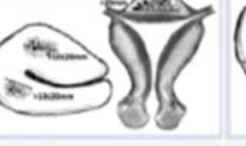


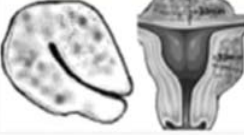




Adenomyosis is not always diagnosed pre-operatively.

First choice of image modality is transvaginal sonography. The sonographic features being areas of heterogeneity within myometrial thickening. The hyper echoic regions are surrounded by hypoechoic areas which is the smooth muscle hyperplasia.

Ultrasound sensitivity varies between 48 to 80%<sup>18</sup>

Ultrasonography is observer dependent

MRI is a more accurate, non-invasive technique for diagnosing adenomyosis. It can detect the widening of the junctional zone and depth of myometrial invasion. 80% adenomyosis uteri is associated with endometriosis and fibroids<sup>12</sup>

SCORE	DIFFUSE ADENOMYOSIS OF THE OUTER MYOMETRIUM	DIFFUSE ADENOMYOSIS OF THE INNER MYOMETRIUM OR JUNCTIONAL ZONE (JZ)	FOCAL ADENOMYOSIS OF THE OUTER MYOMETRIUM	FOCAL ADENOMYOSIS OF THE INNER MYOMETRIUM OR (JZ)	ADENOMYOMA
1	• 1 myometrial wall involvement with myometrial wall thickness $\leq 20$ mm 	• maximum JZ thickness $> 6$ mm • diffuse infiltration of the JZ $\leq 20$ mm in length 	• 1 focal intramyometrial lesion $\leq 10$ mm 	• 1 focal lesion of the JZ by hyperechoic tissue or cystic areas $\leq 10$ mm 	• 1 adenomyoma with the largest diameter $\leq 20$ mm 
2	• 2 myometrial wall involvement with wall thickness $\leq 20$ mm • 1 myometrial wall involvement with wall thickness $> 20 \leq 30$ mm 	• maximum JZ thickness $> 8$ mm • diffuse infiltration of the JZ $> 20$ mm in length or $< 50\%$ of the uterus 	• $\geq 2$ focal intramyometrial lesions $\leq 10$ mm • 1 focal intramyometrial lesions $> 10 \leq 20$ mm 	• $\geq 2$ focal lesions of the JZ $\leq 10$ mm • 1 focal lesion of the JZ $> 10 \leq 20$ mm 	• 2 adenomyomas with the largest diameter $\leq 20$ mm • 1 adenomyoma with the largest diameter $> 20 \leq 30$ mm 
3	• 1 myometrial wall involvement with wall thickness $> 30$ mm • 2 myometrial wall involvement with wall thickness $> 20 \leq 30$ mm 	• diffuse infiltration of the JZ $> 50 \leq 80\%$ of the uterus 	• $\geq 2$ focal intramyometrial lesions $> 10 \leq 20$ mm • 1 focal intramyometrial lesion $> 20$ mm 	• $\geq 2$ focal lesions of the JZ $> 10 \leq 20$ mm • 1 focal lesion of the JZ $> 20$ mm 	• 2 adenomyomas with the largest diameter $> 20 \leq 30$ mm • 1 adenomyoma with the largest diameter $> 30 \leq 40$ mm 
4	• 2 myometrial wall involvement with wall thickness $> 30$ mm • all the uterus involvements with globally enlarged uterus 	• 80% to total infiltration of the JZ 	• $\geq 2$ focal intramyometrial lesion $> 20$ mm • $\geq 3$ focal intramyometrial lesions 	• $\geq 2$ focal lesions of the JZ $> 20$ mm • $\geq 3$ focal lesions of the JZ 	• $\geq 3$ adenomyomas • 1 adenomyoma with the largest diameter $> 40$ mm 

## Treatment

- Medical
- Surgical

There are 3 types of conservative surgical treatments.

- Type 1- Complete excision of adenomyosis<sup>16,19,20,21</sup>

- Type 2 – Partial adenomyomectomy<sup>19,21,22</sup>
- Type 3- Non excisional technique<sup>21,22</sup>

Difference in Type 1 & Type 2 adenomyomectomy

Adapted from Horng et al. 2014

Characteristics	Type 1	Type 2
Disease Excision	Complete	Cytoreduction
Residual Disease	None	Optimal or Suboptimal
Surgical Technique	Easier	Difficult
Risk of Entering the endometrium	Low	High
Risk of Damaging Functional Myometrium	Low	High
Uterine Integrity	Conserved	Probably conserved
Risk of Gestational Uterine Rupture	Low	High
Symptom Control	Good or Excellent	Acceptable
Fertility Preservation	High	Probably low

The variety of approaches for surgical treatment are shown in table below depending on extent of excision.



Type of Surgery	Techniques and Variants
Complete Excision	Classic Technique - Hyams 1951- GrImblzis 2008
Adenomyomectomy	Triple Flap Method - Osada 1011
	U- Shaped Suture- Sun2011
	Overlapping Flaps - Tacheshi 2006
Cystectomy	Classic Technique
Cytoreductive Excision	Classic technique - Fujishita 2004
	Transverse H incision - Fujishita 2004
Partial Adenomyomectomy	Wedge resection of uterine wall - Sun 2011
	Assymetric dissection of uterine wall - Nishida 2010
Non-Excisional Surgery	Uterine artery ligation – Wang 2002
	Electrocoagulation of myometrium - Wood 1998
	Endometrial resection - Wood 1998
Laparoscopic	Endometrial ablation - Preuthhupan 2010
Hysteroscopic	Hysteroscopic cystectomy
Combined	High frequency ultrasound - Yang 2009
Others	Endometrial non-hysteroscopic ablation by Radiofrequency Ryo 2006 Microwave - Kanaoka 2004 Balloon -Chan 2001

The first conservative surgical treatment was reported in 1952<sup>24</sup>.

The surgical approach depends upon the extent of disease, the location, choice of patient for uterine preservation and skills of gynecologist

## Laparotomy

### Partial Reduction Surgeries

**Wedge resection** of the uterine wall like the name suggests Wedge resection of adenomyosis is done. The defect is closed with the remaining seromuscular layers.

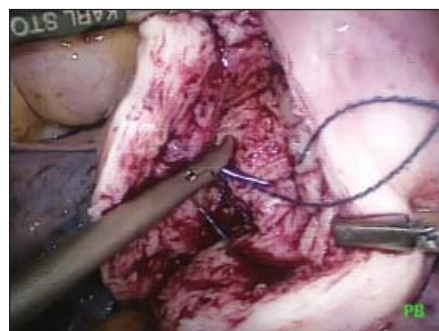
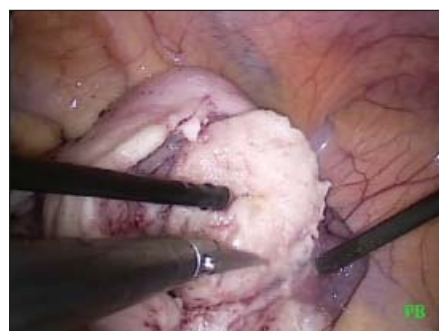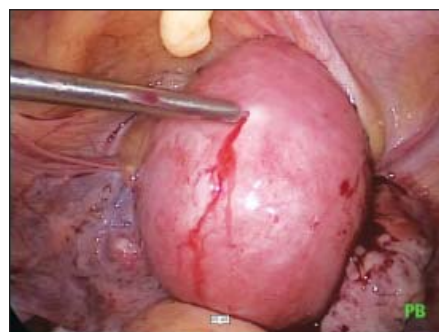Here part of Adenomyoma tissue may remain on either side of the incision.<sup>25</sup>

The efficacy on menorrhagia and dysmenorrhoea is small. Recurrence is seen due to left over adenomatous tissue

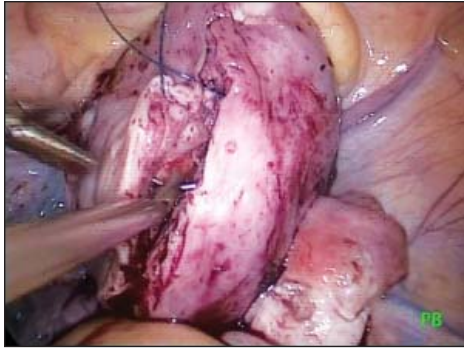
### Modified Reduction Surgery

A. Classic Technique – This technique requires recognition of extent of lesion by inspection, palpation.

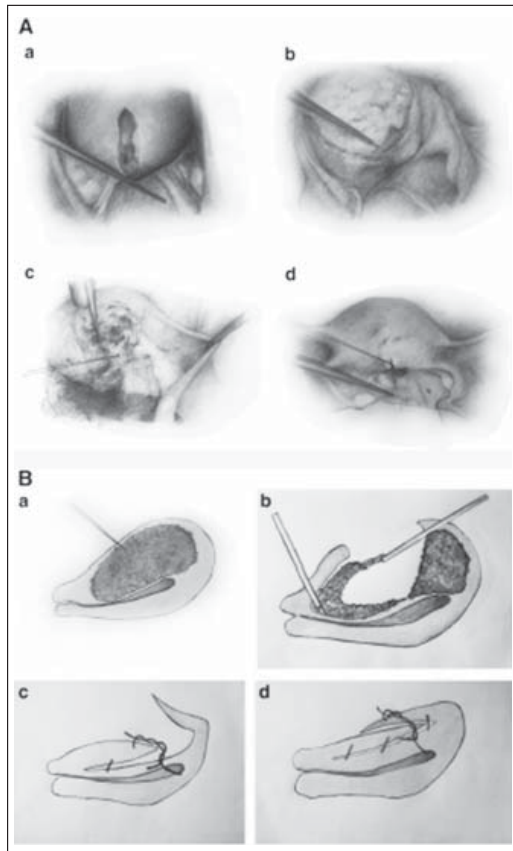
Vertical incision over the adenomyoma on the uterine wall is given lesion is excised with sharp dissection, dead space suturing is done in 1 and 2 layers. The endometrial cavity if open is sutured with absorbable suture.



Vasopressin injection in adenomatous uterine



Vasopressin injection in adenomatous uterine



Grimbizis. Uterine sparing surgery for adenomyosis. Fertil Steril 2014<sup>16</sup>

**B. Transverse H** incision of uterine wall.<sup>26</sup> This technique requires a vertical incision from the fundus, transverse incision on the fundus and the lower body are given using electrocautery/ scissors separating the uterine serosa and myometrium. After opening of the serosa, adenomyomatous tissue is excised. The myometrial layers are stitched together in 1 to 2 layers with tensionless suturing. First layer of suturing takes care of hemostasis.

With the H incision technique 38.7% achieved pregnancy, 16.1% had miscarriage, 22.5% had live births.<sup>27</sup>

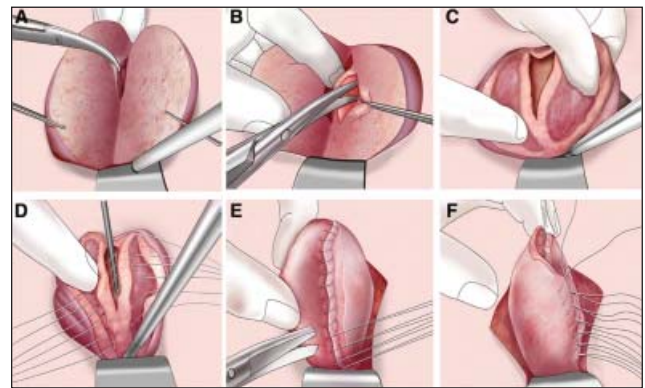
### C. Wedge shaped uterine wall removal

Thin wedge shaped removal of adenomyotic tissue after sagittal incision in the uterine body is carried out. Continuous horizontal mattress technique is used to reconstruct the defect. Cut edges are inverted by baseball continuous Lambert stitch to reduce adhesions over the suture line of bowel, omentum and peritoneum. With this technique 30% achieved pregnancy and 22.8% had live birth<sup>(28)</sup>

### Complete Adenomyosis Excision

**Triple flap method** can be used both for diffuse and nodular adenomyosis.

It also helps in prevention of uterine rupture in pregnancy post-surgery.<sup>19, 29, 30,31,32</sup>



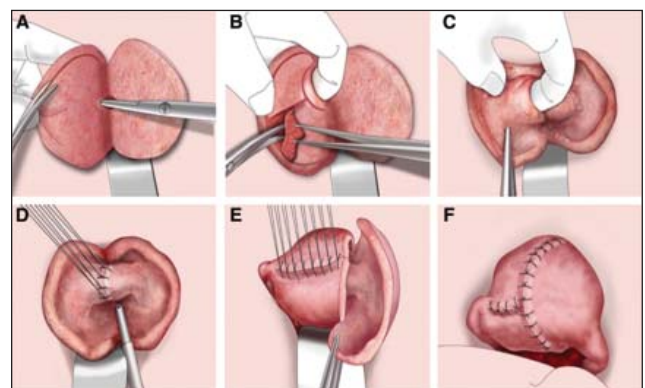
**Fig 1:** Osada Uterine Adenomyosis and adenomyoma Fertil Steril 2018

Triple flap technique involves

Complete excision of adenomyotic tissue Fig 1a, 1b, 2a, 2b

Using palpation and cold knife scissors fig 1b, 1c 2b, 2c

Creation of a flap



**Fig 2:** Osada. Uterine adenomyosis and adenomyoma. Fertil Steril 2018

Serosal side uterine muscle is used to fill the muscle defect and uterine reconstruction is done to safeguard subsequent pregnancy rupture Fig 1DEF, Fig 2 DEF

Recurrence occurred in 3.5%

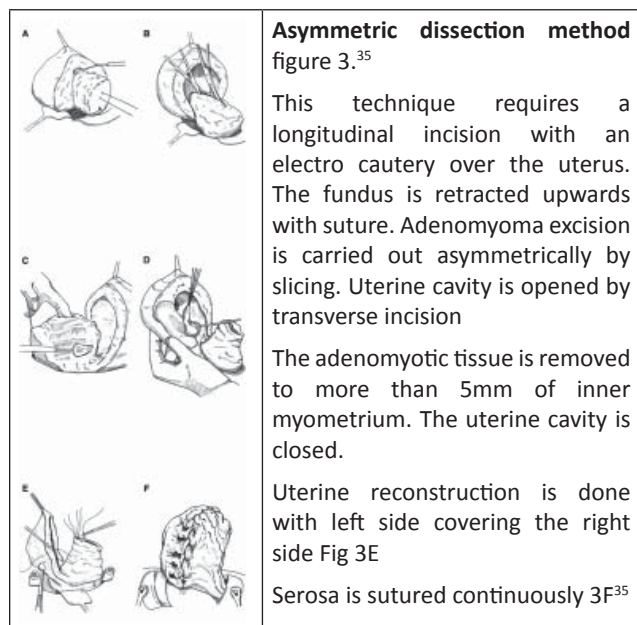
### Double Flap Method<sup>33,34</sup>

Uterine cavity is not opened

The uterine reconstruction is done by serosal side uterine muscle flap

Adenomyomectomy in both these techniques require palpation and extensive suturing so open surgery is preferable

If these criteria can be fulfilled laparoscopy assisted adenomyomectomy can be done.



Osada adenomyosis and adenomyoma. Fertil Steril 2018

Spontaneous uterine rupture was seen in five cases in the series<sup>36</sup>

## Adenomyomectomy

### The Challenges

Adenomyosis is quite often misdiagnosed as fibroids on ultrasound. MRI is a better detector of this condition, costs being a limiting factor.

### Extent of Removal

There are no surgical planes between Adenomyosis and healthy uterine tissue so it becomes difficult to define the area and extent of excision

Ultrasonography guidance could be used to define extent

### Technical Problems

Adenomyotic tissue being tough, it is difficult to excise. Suturing also involves expertise as the tissue is tough and cutting through can happen.

### Associated problems

Intraoperative bleeds, post-operative adhesions (pain and infertility) disease recurrence or uterine rupture post conception.

### Post adenomyomectomy pregnancy

When operating close to fallopian tubes one has to be mindful of fertility issues.

Adequate uterine cavity should be ascertained for future pregnancy and fetal growth.

Precautions during and post-surgery should be taken to prevent adhesions

Excessive excision of myometrium causes reduced uterine capacity for pregnancy Uterine scar with reduced elasticity can predispose to uterine rupture during pregnancy.

**Open technique** is the gold standard in extensive disease with its risks and morbidity

**Laparoscopically assisted vaginal excision:** Laparoscope is introduced to rule out adhesions. Bilateral uterosacral ligament is removed followed by posterior colpotomy. Uterus is delivered vaginally. Adenomyotic tissue is excised by palpation & electrocautery. Closure of myometrium is done in 1-2 layers and serosa is closed too.<sup>37</sup>

**Laparoscopic Adenomyomectomy** is now being used to prevent the morbidity of open surgery with useage of microsurgical principles and greater precision there is reduction in bleeding, trauma, adhesions and pain.

Initially laparoscopic adenomyomectomy was carried out as wedge resection with some adenomyosis tissue remaining on either side of the incision.

### Laparoscopic Modified Adenomyomectomy

Transtrocar ultrasonography can be used to define the extent of disease.<sup>38</sup>

**Sun et al 2011.**<sup>25</sup> Serosa is marked by bipolar coagulation, transverse uterine incision is made by monopolar electro cautery till non-disease tissue reached and excised. The cave like wound

is closed by a U shaped Suture of muscle layers. Seromuscular layer is closed with a figure of eight stitch one cm apart.

**Laparoscopic approach** has access constraints and hence one has to improvise

**Morita et al** in 2004<sup>39</sup> delineated the lesion with MRI and used pre-op GNRH for 3 to 4 months. Case series of three patients with focal adenomyosis were done. They had good symptom control.

**Takeuchi et al** 2006<sup>33</sup> Used radical excision technique where a flap was made and used to fill the dead space with overlapping. They used preoperative Leuprolide acetate/ OC's.

The symptoms post operatively showed improvement via VAS 10 to VAS 2.5.

**Grimbizis** 2008<sup>40</sup> demonstrated safety and feasibility of laparoscopic adenomyomectomy.

Studies indicating the feasibility of laparoscopic adenomyomectomy

Study	Cases	Average size of Lesion	Average Operating Time (min)	Average Blood Loss (ml)	Adjuvants
Morita et al <sup>(39)</sup>	3	5.83 cm	91.7	53.3	Preoperative GnRH agonist
Takeuchi et al <sup>(33)</sup>	14	24 g	101.5	225	Preoperative GnRH Agonist (x 9) Oral contraceptive pill
Grimbizis et al <sup>(40)</sup>	6	5 cm	100.5	163	Nil
Wang et al <sup>(41)</sup>	2	4.25 cm	NR	NR	Oxytocin infusion for 1 patient
Sun et al <sup>(25)</sup>	13	4.4 cm	91	216	Nil
Kang et al <sup>(46)</sup>	37	60 g	115.7	80	Uterine artery occlusion

NA not applicable NR not reported

A meta-analysis of RCT was published in 2009<sup>(42)</sup> comparing open / laparoscopic myomectomy

More studies are required for adenomyomectomies in the same vein

### Steps to reduce problems during laparoscopy

**Extent of tissue excision** is defined by Transtrocac ultrasonography<sup>38</sup>

## Hemorrhage

Use of GNRH pre-operatively to decrease the lesion size, reduction in vascularity which eventually helps in excision.<sup>48</sup> It also helps in correction of anaemia.

Reduction of operative bleeding helps in laparoscopic approach in place of laparotomy.

Disadvantages of GnRH usage –Recognition of adenomyotic tissue in normal size uteri becomes difficult. Tissue planes are lost. Risk of perforation of endometrium increases, excision of large amount of adenomyotic tissue becomes difficult.<sup>26</sup>

## Vasopressin

Causes smooth muscle constriction of vessels and reduces blood loss transiently (20 to 40 minutes) Used in concentration of 10 units in 100cc normal saline

The problem of puncture site bleeding and **delayed bleeding** should be kept in mind<sup>44</sup>

## Defect Closure

Closure with absorbable suture in one or multiple layers.

U-shaped suture helps in securing Hemostasis and reducing tissue tension during suturing **Sun et al**<sup>25</sup> It also helps in correction of anaemia.

## Laparoscopic Uterine Artery Occlusion /Ligation

The uterine artery can be ligated by an anterior approach.<sup>45</sup> UV fold is opened and bladder is pushed down, uterine arteries are identified and ligated.

Uterine artery can be ligated at the origin by dissection in the triangle of round ligament, external iliac artery and infundibulopelvic ligament

Uterine artery tied at origin

**Kang et al**<sup>46</sup> Described the role of uterine artery occlusion in laparoscopic adenomyomectomy.

Shrinkage of uterus Post surgery at six months 24.7%, twelve months 59.2%.

Uterine artery Occlusion does not cause decreased ovarian reserve **Qu et al**<sup>47</sup>

Not enough studies have been done to advocate uterine artery ligation in cases of infertility hence



thorough counselling should be in place before offering it to cases of infertility

**Kwan et al** in 2013<sup>48</sup> demonstrated transient occlusion of uterine artery using endoscopic vascular clip with no injury to the vessel on laparotomy which could also be used in laparoscopic adenomyomectomy.

### Timing of Surgery

It has an impact on intraoperative blood loss. There is increased vascular reactivity allowing for contraction of vessels during follicular phase.

### Adhesions

This can cause post-operative pain, secondary infertility and bothersome next surgeries. Following the microsurgery principles with good haemostasis can go a long way in adhesion prevention Adhesion barriers could also be used.

### Uterine Rupture in Pregnancy

Isolated case reports of uterine rupture of gravid uterus in cases of adenomyosis without cytoreductive surgery has been recorded.<sup>(49)</sup>

Adenomyomectomy may be associated with excision of normal myometrium. There may be remnant adenomyotic tissue in the scar. Both these factors contribute to weakening of scar making the repair less than optimum.

True incidents of adenomyomectomy scar rupture is not yet known

Factors contributing to scar rupture may be size of adenomyosis lesion excision, adequacy of dead space obliteration, level of haemostasis, stitching techniques, time to conception possibility of uterine and rupture in future pregnancies should be discussed pre-operatively in detail.

### Combined Surgical Medical Treatment

Medical treatment post-surgery improves the results of surgery. Two year follow-up study post adenomyomectomy combined with medical treatment gave better symptom control and relapse rates.<sup>50</sup>

### Robotic Adenomyomectomy

This is another surgical option robotic technique

which is the learning curve between open and laparoscopic approach.

Costs are prohibitive

Moreover challenges of laparoscopic approach are not fully ameliorated by robotic approach.<sup>51</sup>

### Laparotomy/Laparoscopy

Laparotomy was the gold standard for adenomyosis management surgically. Advantage being palpation during surgery. But if MRI can delineate laparoscopy is the go to method both for ablation and excision.<sup>39</sup>

Moreover with practice laparoscopic suturing presents no more difficulty than as in myomectomy.<sup>40</sup>

### Superior Technique?

There is no statistical clinical difference in practice in either technique.

Modifications aim to maximize adenomyotic tissue excision and to give good scar integrity for future pregnancy.

### Conclusion

Tailored approach to individual disease profile is the way forward with careful case selection and proper counselling via potential risk and impact on future fertility.

Control of symptoms Dysmenorrhoea 81%, Menorrhagia 50% , Pregnancy rates 46%.

Further studies are required for managing adenomyosis with an aim to develop safer and less invasive methods to promote the management of adenomyosis as data supporting this intervention still suboptimal.

### References

1. Rokitsky C (1860) Über Uterusdrusen-Neu-Bildungen in Uterus und Ovarial – Sarcomen. Zeitschrift der Kaiserlich Koenigl Gesellschaft der Aerzte zu Wien 37:577-81
2. Von Recklinghausen FD (1893) Über die Ad-nocysten der uterustumoren and Ueberreste des Wolffschen Organs Deutsche Medizinische Wochenschrift 19 824-6
3. Cullen T (1896) Adeno-myoma uteri diffuse be-nignum. John Hopkins Hosp Rep 6: 133-54
4. Kossmann R (1897) Die Abstammung der Drüseneinschlüsse in den Adenomyomen des Uterus und der Tube. Archiv für Gynaecologie 54:381
5. Iwanoff N (1898) Drüssiges Cystenhaltiges Uterusfibrom compliciert durch Sarcom und Carcinom. Monatsschrift für Geburtshilfe und Gynaecologie 5: 295-300

6. Meyer R (1903) Eine unbekannte Art von Adenomyom des Uterus mit einer kritischen Besprechung der Urnierenhypothese V. Reckling-hausens Zeischrift fur Geburtshilfe Ung Gynaecologie 49:464-507
7. Leyendecker G & Wildt L (2011) A new concept of endometriosis and adenomyosis : tissue injury and repair (TIAR). *Horm Mol Biol Clin Invest* 5: 125-42
8. Liu X, Nie J & Guo SW (2011) Elevated immunoreactivity to tissue factor and its associations with dysmenorrhea severity and the amount of menses in adenomyosis. *Human Reprod* 26:337-45
9. Juo SH, Wang TN, Lee JN, et al. (2006) CYP17, CYP11A1 and COMT polymorphisms and the risk of adenomyosis in Taiwanese women. *Human Reprod* 21:1498-502
10. Uduwela AS, Perera MAK, Aiqing L & Fraser IS (2000) Endometrial –myometrial interface : relationship to adenomyosis and changes in pregnancy. *Obstet Gynecol Surv* 55:390-400
11. Ferenczy A (1998) Pathophysiology of adenomyosis. *Hum Reprod Update* 4:312-22
12. Matalliotakis IM, Kourtis AI, Panidis DK (2003) Adenomyosis. *Obstet Gynecol Clin North Am* 30(3): 63-82
13. Azziz R (1989) Adenomyosis: current perspectives. *Obstet Gynecol Clin North Am* 16 (3): 221-35
14. Sammour A, Pirwany I, Usubutun A, Arsenault J, Tulandi T (2002) Correlations between extent and spread of adenomyosis and clinical symptoms. *Gynecol Obstet Invest* 54:213-6
15. Benagiano G, Habiba M, Brosens I (2012) The Pathophysiology of uterine adenomyosis: an update. *Fertil Steril* 98:572-9
16. Grimbizis G, Mikos T, Tarlatzis B, Uterus-sparing operative treatment for adenomyosis fertility and Sterility 2014, Volume 101, Issue 2, 472-487.e8.(2014)
17. New Sonographic Classification of Adenomyosis: Do type of degree of adenomyosis correlate to severity of symptoms? Caterina Exacoustos, MD, PhD, Giulia Morosetti, MD, Francesca Conway, MD, Sara Camilli, MD, Francesco Giuseppe Martire, MD, Lucia Lazzeri, MD, PhD, Emilio Piccione, MD and Errico Zupi, MD
18. Ascher SM, Arnold LL, Patt RH, Schrufer JJ, Bagley AS, Semelka RC, Zeman RK, Si-non JA (1994) Adenomyosis: prospective comparison of MR imaging and transvaginal sonography. *Radiology* 190:803-6
19. Osada H, Silber S, Kakinuma T, Nagaishi M, Kato K, Kato O. Surgical procedure to conserve the uterus for future pregnancy in patients suffering from massive adenomyosis. *Reprod Biomed Online* 2011;22:94-9.
20. Protopapas A, Milingos S, Markaki S, et al, Cystic uterine tumors. *Gynecol Obstet Invest*. 65;275-80(2008)
21. Takeuchi H, Kitade M, Kikuchi I, et al. Diagnosis, laparoscopic management and histopathologic findings of juvenile cystic adenomyoma: a review of nine cases. *Fertil Steril*. 94.862-8(2010)
22. Wood C, Surgical and Medical treatment of adenomyosis. *Hum Reprod Update*. 4:323-36(1998)
23. Horng HC, Chen CH, Chen CY, et al. Uterine – sparing surgery for adenomyosis and or adenomyoma. *Taiwan J Obstet Gynecol* 53:3-7.(2014)
24. Van Praagh I Conservative surgical treatment of adenomyosis uteri in young women: Local excision and metroplasty. *Can Med Assoc J* 1965: 93:1174-5.
25. Sun AJ, Luo M, Wang W, Chen R, Lang JH. Characteristics and efficacy of modified adenomyomectomy in the treatment of uterine adenomyoma. *Chin Med J (Engl)* 2011;124:1322-6
26. Fujishita A, Masuzaki H, Khan KN, Kitajima M, Ishimaru T. Modified reduction surgery for adenomyosis. A preliminary report of the transverse H incision technique. *Gynecol Obstet Invest* 2004;57:132-8
27. Fujishita A, Hiraki K, Kitajima M, Matsumoto Y, Satoh H, Masuzaki H, et al. Shikyusenkinsho to shikyu no onzonchiryo. (Uterine adenomyosis and uterine preservation treatment.) *J Obstet Gynecol Prac (Tokyo)* 2010;59:769-76
28. Saremi AT, Bahrami H, Salehian P, Hakak N, Poolad A. Treatment of adenomyomectomy in women with severe uterine adenomyosis using a novel technique. *Reprod Biomed Online* 2014 ; 28:753-60
29. Osada H, Abe M, Takeya C, Mizutani M, Oogame Y, Ysubata K, et al Nanchisei shikyusenkinsho no gekateki chiryo. (Surgical treatment of severe uterine adenomyosis) *Gynecol Obstet Surg, Medical View, Tokyo* 2003;14:101-8
30. Osada H, Shikyusenkinsho no hozonryaho: Shikyusenkinsho tekishutsujutsu (Conservative surgery for adenomyosis : adenomyomectomy by the Triple – flap method) *J Jpn Soc Endometriosis* 2006; 27:39-42.
31. Osada H, Shikyusenkinsho. (Uterine adenomyosis) In: Osada H. Jissen fu-jinka fukkukyoka –shujutsu. (Laparoscopy for gynecology: a comprehensive manual and procedure DVD) Tokyo: Medical view, 2009: 118 – 53.
32. Osada H, Nagaishi M, Teramoto S. Shikyukin furappuho niyoru shikyu-senkinsho tekishutsujutsu: Rinshoteki choki-yago oyabi shikyuharesu-yabakaka no kento. [Adenomyomectomy by uterine muscle flap method: Clinical outcome and investigation of the preventive effect on uterine rupture.] *Obstet Gynecol (Tokyo)* 2017;84:1303-15.
33. Takeuchi H, Kitade M, Kikuchi I, Kikuchi I, Shimanuki H, Kumakin J, et al. Laparoscopic adenomyomectomy and hysteroplasty : a novel method *J Minim Invasive Gynecol* 2006; 13 : 150-4.
34. Kitade M, Kumakiri K, Kuroda J, Jinushi M, Ujihira Y, Ikuma K, Ozaki R, et al. Shikyusenkinsho gappei-funin ni taishite fukkukyoka-shikyu-onzon-ryahowa yukoka? – jutsugoninshinritsu to senko-shujutsu no umu ni yoru shusankiyago no kento [ Is laparoscopic uterine preservation surgery effective against infertility associated with uterine adenomyosis ? – A study of perinatal prognosis by postoperative pregnancy rate and the presence of prior surgery. ] *J Jpn Soc Endometriosis* 2017;38:70.
35. Nishida et al. Conservative surgical management for diffuse adenomyosis. *Fertil Steril* 2010;94:715-9
36. Nishida M, Otsubo Y, Ichikawa R, Arai Y, Sakanaka S. Shikyusenkinsho- Kakushutsujutsu-go ninshin-ji no

- shikuyharetsu-yabo ni tsuite (Prevention of uterine rupture during pregnancy after adenomyomectomy). *Obstet Gynecol Surg. Medical View. Takyo* 2016 ;27: 69-76.
37. Wada S, Kudo M, Minakami H. Spontaneous uterine rupture after a laparoscopic adenomyomectomy. A case report. *J Minim Invasive Gynecol* 2006;13 166-8
  38. Nabeshima H, Murakami T, Nishimoto M, Sugawara N, Sato N. Successful total laparoscopic cystic adenomyomectomy after unsuccessful open surgery using transtrocar ultrasonographic guiding. *J Minim Invasive Gynecol* 2008; 15: 227-30
  39. Morita M, Asakawa Y, Nakakuma M, Kubo H. Laparoscopic excision of myo-metrial adenomyomas in patients with adenomyosis uteri and main symptoms of severe dysmenorrhoea and hypermenorrhoea. *j Am Assoc Gynecol Laparosc.* 2004;11:86-89
  40. Grimbizis GF, Mikos T, Zepiris L, Theodoridis T, Miliaras D, Tarlatzis BC et al Laparoscopic excision of uterine adenomyomas *Fertil Steril* 2008;89 953-61
  41. Wang CJ, Yuen LT, Chang SD, Lee CL, Soong YK. Use of cytoreductive surgery to treat infertile women with localized adenomyosis. *Fertil Steril.* 2006;86:462.e5-462e8
  42. Jin C, Hu Y, Chen XC, et al. Laparoscopic versus open myomectomy – a meta-analysis of randomized controlled trials. *Eur j Obstet Gynecol Reprod Biol.* 2009;145:14-21.
  43. Fedele I, Bianchi S, Frontino G, Hormonal treatments for adenomyosis. *Best Pract Res Clin Obstet Gynaecol*, 2008;22:333-339.
  44. Reich H, Laparoscopic myomectomy. *Obstet Gynecol Clin North Am.* 1995;22:757-780.
  45. Rakesh S, Meenakshi S, Chaitali M, Shweta R, Pratima K, Gayatri R, Laparoscopic myomectomy with uterine artery ligation: review article and comparative analysis, *j Gynecol Endosc Surg*, 2011;2:3-10.
  46. Kang I, Gong, j, Cheng Z, Dai H, Hu I. Clinical application and midterm results of laparoscopic partial resection of symptomatic adenomyosis combined with uterine artery occlusion. *j Minim Invasive Gynecol*, 2009;16:169-173.
  47. Qu X. Cheng Z, Yang W, Xu I, Dai H, Hu I. Controlled clinical trial assessing the effect of laparoscopic uterine arterial occlusion on ovarian reserve, *j Minim Invasive Gynecol*, 2010;17:47-52.
  48. Kwon Y-S, jung D-Y, Lee S-H, Ahn jw, Roh Hj, Im KS. Transient occlusion of uterine arteries with endoscopic vascular clip preceding laparoscopic myo-mectomy, *j Laparoendosc Adv Sur Tech.* August 2013;23(8):679-683, [http://dx. doi. org/10. 1089/lap. 2012. 0540](http://dx.doi.org/10.1089/lap.2012.0540).
  49. Coghlin DG. Pregnancy with uterine adenomyoma. *Can Med Assoc J* 1947;56:315-6.
  50. Wang PH, Liu WM, Fuh ji, Cheng MH, Chao HT, Comparison of surgery alone and combined surgical –medical treatment in the management of symptomatic uterine adenomyoma, *Fertil Steril*, 2009;92:876-885.
  51. Akar ME, Leezer KH, Yalcinkaya TM. Robot – assisted laparoscopic mamagement of a case with juvenile cystic adenomyoma. *Fertil Steril.* 2010;94:e55-e56.

## Answer: November 2020 Issue

### Crossword

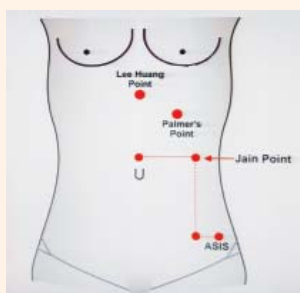
#### Across

1. Enzian                      2. Obturator                      7. Discoid Excision                      8. Five

#### Down

1. Endosee      2. Osada      3. Adenomyosis      4. Ceiling      5. Uterine      6. Bipolar

## Pictorial Quiz Answers



Ans 1. **Lee Hung Point:** It is point in the midline midway, between xiphoid process and umbilicus

**Jain Point:** It is located 10-13 cm lateral in the left para- umbilical position

**Palmer's Point:** It is located in left upper quadrant, 3cm below the costal margin and in the midclavicular line

# 42<sup>nd</sup> Annual Conference (1<sup>st</sup> E-Conference) AOGD

## Prize Winners

Competition Paper/Free Paper/Poster/Slogan/Quiz  
30<sup>th</sup>-31<sup>st</sup> October & 1<sup>st</sup> November, 2020

Category	Award	Name	Institute	Title
Research Paper- <b>Best Competition Paper</b>	<b>Gold Medal</b>	Dr Priyanka Pangtey	Safdarjung Hospital	Efficacy of See and Treat Approach at Colposcopy in Via Based Screening
	<b>Silver Medal</b>	Dr Aanchal Varma	University College of Medical Sciences and GTB Hospital	The Next Frontier: Liquid biopsy for diagnosing ovarian cancer- quantification of cell-free dna and p53 mutational analysis
	<b>Bronze Medal</b>	Dr Ankita Jain	University College of Medical Sciences and Guru Teg Bahadur Hospital, New Delhi	Association of Fetal Urine Production Rate and Fetal Inflammatory Response Syndrome in Cases of PPROM
Dr Neera Agarwal's Medal for Best paper on theme topic: <b>High Risk Pregnancy</b>	<b>Gold Medal (tie)</b>	Dr Suvidya Singh	Maulana Azad Medical College, New Delhi	Maternal and Perinatal Outcomes in Critically-Ill Pregnant Women Infected with COVID-19
		Dr Keerti Chandra	Lady Hardinge Medical College, New Delhi	Ophthalmic Artery Peak Ratio: a novel marker of feto-maternal outcome in severe pre-eclampsia
Dr Suneeta Mittal's Medal for Best paper on theme topic: <b>Benign Gynaecological Conditions</b>	<b>Gold Medal</b>	Dr Krithika V S	All India Institute of Medical Sciences, New Delhi	Myo-inositol and D-chiro-inositol Combination on Menstrual Cycle Regulation in Young Girls with PCOS - A randomized open-label study
Dr U.P Jha & Raj Soni's Medal for Best paper on theme topic: <b>Infertility &amp; IVF</b>	<b>Gold Medal</b>	Dr Garima Maan	Lok Nayak Hospital & MAMC	Evaluation of Uterine Causes of Infertility by Transvaginal Ultrasound (TVS), hysterosalpingography (HSG) and hysteroscopy (HYS)
Dr U.P Jha & Dewan Balakram's Medal for Best paper on theme topic: <b>Gynae - Oncology</b>	<b>Gold Medal</b>	Dr Megha Nandwani	Dr. B Borooah Cancer Institute	Carcinoma Vulva: A study from Northeast India
Mr S. Bhattacharya & Dr Ganguli's Medal for Best paper on theme <b>-Miscellaneous Category</b>	<b>Gold Medal</b>	Dr Reema Kumar Bhatt	Army Hospital Research and Referral, Delhi	Our Initial Experience with Chromosomal Microarray Analysis for Prenatal Diagnosis in Fetuses with Structural Abnormalities
	<b>Silver Medal</b>	Dr Ipshita Sahoo	AIIMS, New Delhi	Evaluating The Efficacy of COVID-19 Screening Questionnaire for Labour Room and Ward Admissions in the Pandemic Era
<b>Poster Presentation</b>	<b>Gold Medal (tie)</b>	Dr Shivaani Arora	AIIMS, Rishikesh	Curious Case of Von Wyk Grumbach Syndrome
		Dr Rajeswari Ponniah	VMMC, Safdarjung Hospital, Delhi	Aggressive Angiomyxoma of Vulva-A 14 Year Long Follow Up
	<b>Silver Medal (tie)</b>	Dr Anupriya Narain	MAMC and Lok Nayak Hospital, Delhi	Pregnancy with Tubercular Pericarditis Presenting as a Cardiac Emergency: Review of a rare case
		Dr Vidushi Kulshrestha	All India Institute of Medical Sciences, New Delhi	Assessment for Depression Among Pregnant Women Visiting Tertiary Care Facility During COVID-19 Pandemic



<b>Slogan</b>	<b>First Prize</b>	Dr Swati Aggawal	Lady Hardinge Medical College	COVID-19 Mahamaari Se Tham Gai Sansaar Ki Gati, Par Ruk Na Saki Prasav Peeda Aur Santaan Utpatti. Aao Karein Pran Thamenge Na Humare Kadam, Banaenge Iss Kathin Samay Mein Bhi Garbhavastha Ko Sugam
	<b>Second Prize</b>	Dr Bhawani Shekhar	Sir Gangaram Hospital	We Have Bridled The Wayward Covid Ride We, Obstetricians Take Every Challenge in Our Stride!
	<b>Third Prize</b>	Dr Prerna Tayal	Lady Hardinge Medical College	The Current COVID Times are Pretty Tough, Pregnancy at This Hour may be Quite Rough. But We AOGDians are Here to Help, Coz We Always Put Service Before Self
Dr Batra's Medal winner for <b>AOGD Quiz</b>	<b>Gold Medal (tie)</b>	Dr Garima Maan	Lok Nayak Hospital & MAMC	
		Dr Pallavi Behl	Guru Teg Bahadur Hospital and University College of Medical Sciences	
		Dr Kanika Gupta	Max Super Speciality Hospital, Saket	
	<b>1<sup>st</sup> Runner Up</b>	Dr Aanchal Verma	University College of Medical Sciences	
	<b>2<sup>nd</sup> Runner Up</b>	Dr Sugandha Bansal	Vardhaman Mahavir Medical College and Safdarjung Hospital	
Dr S N Mukherjee <b>Rotating Trophy</b>	<b>Best AOGD Monthly Clinical Meeting</b>	Maulana Azad Medical College & Lok Nayak Hospital, Delhi		

## Appreciation Prize for Free Papers

(Alphabetical order)

S. No	Category	First Name	Prize	Institution	Title
1	Infertility & IVF	Dr Babita Kumari	Appreciation Prize	Lady Hardinge Medical College	Correlation of Serum AMH with Clinical, Biochemical and Ultrasonographic Parameters Among Infertile Women with PCOS
2	High Risk Pregnancy	Dr Bhanu Priya	Appreciation Prize	UCMS and GTBH	Maternal Neonatal Outcomes in Covid Negative and Covid Probable Obstetric Women Presenting with Covid Like Symptoms
3	High Risk Pregnancy	Dr Garima Kachhawa	Appreciation Prize	All India Institute of Medical Sciences, New Delhi	Evaluation of Oxidative Stress Markers and Endothelial Function Assessment During Pregnancy and Correlate with Development of Hypertension in Pregnancy: A prospective cohort study
4	Miscellaneous	Dr Lakshmi Shankar	Appreciation Prize	Maulana Azad Medical College and Associated Lok Nayak Hospital	Clinical Correlation of Vitamin D Deficiency in Pregnancy with COVID-19
5	High Risk Pregnancy	Dr Latika Chawla	Appreciation Prize	AIIMS Rishikesh	Management of Cesarean Scar Pregnancy: A challenge
6	High Risk Pregnancy	Dr Pallavi Behl	Appreciation Prize	University College of Medical Sciences and Guru Teg Bahadur Hospital	Furosemide vs. Amlodipine in Postpartum Blood Pressure Control: A double blind randomized clinical trial

7	High Risk Pregnancy	Dr Parul Jaiswal	Appreciation Prize	All India Institute of Medical Sciences, New Delhi	Glanzmann Thrombasthenia in Pregnancy: Every obstetrician's nightmare
8	Benign Gynaecological Conditions	Dr Rakhi Rai	Appreciation Prize	All India Institute of Medical Sciences, New Delhi, India	A Prospective Randomized Comparative Clinical Trial of Hysteroscopic Septal Resection Using Conventional Resectoscope Versus Mini-resectoscope
9	Benign Gynaecological Conditions	Dr Sakshi Tandon	Appreciation Prize	Gangaram Institute of Postgraduate Medical Education and Research, New Delhi	Effect of Mode of Delivery on Levator Hiatus Biometry and External Anal Sphincter Morphology
10	Miscellaneous	Dr Sathindra Sadhvi Balasundaram	Appreciation Prize	Maulana Azad Medical College	Serum Adiponectin Levels in Pregnant Women with and without Gestational Diabetes Mellitus
11	High Risk Pregnancy	Dr Saumya Kulshrestha	Appreciation Prize	AIIMS, New Delhi	Introducing Clinical Debriefing Session in COVID Positive Obstetric Patients admitted in Trauma Centre - A quality improvement initiative
12	High Risk Pregnancy	Dr Shama Aafreen	Appreciation Prize	Lady Hardinge Medical College	Evaluation of Prenatal Ultrasound Markers for Prediction of Respiratory Distress in Early Preterm Newborns
13	Gynae Oncology	Dr Sharda Patra	Appreciation Prize	Dr B. Borooah Cancer Institute, Guwahati	Factors Predicting Survival Following Recurrence in women with advanced ovarian cancer treated with interval debulking surgery - A retrospective study
14	Miscellaneous	Dr Shivangi Sharma	Appreciation Prize	Vardhman Mahavir Medical College and Safdarjung Hospital, New Delhi.	Ultrasonographic Assessment of Cervix for Prediction of Successful Induction of Labour
15	Miscellaneous	Dr Swati Agrawal	Appreciation Prize	Lady Hardinge Medical College & Smt. SSK Hospital, New Delhi, India	Enhancing Postpartum IUCD Coverage at a Tertiary Care Facility: A quality improvement initiative

## Appreciation Prize for Poster Presentations

(Alphabetical order)

S. No	First Name	Prize	Institution	Title
1	Dr Anamika Baghel	Appreciation Prize	Hamdard Institute of Medical Sciences And Research, New Delhi, India	Vaginoscopic Resection of Oblique Vaginal Septum in an Unmarried Female with Ohvira Syndrome
2	Dr G Raja	Appreciation Prize	AIIMS, Bhubaneswar	Pregnancy with Breast cancer
3	Dr Kavita Khoiwal	Appreciation Prize	All India Institute of Medical Sciences, Rishikesh	An Extremely Unusual Case of a Ginormous Malignant Ovarian Tumour
4	Dr Manisha Vinnakota	Appreciation Prize	Lady Hardinge Medical College	Bromocriptine: A novel management in peripartum cardiomyopathy

5	Dr Millo Suka	Appreciation Prize	Lady Hardinge Medical College	Comparison of Objective Method of Symphysis Fundal Height Measurement with Conventional Method of Fundal Height Measurement for Detection of SGA
6	Dr Monica Sharma	Appreciation Prize	Maulana Azad Medical College	Persistent Thrombocytopenia in Pregnancy associated with Ebstein Barr virus
7	Dr Monika Kanyal	Appreciation Prize	Esi-Pgimsr, Basaidarapur, Delhi	Classical Caesarean for Large Cervical Fibroid
8	Dr Nisha Yadav	Appreciation Prize	Sir Gangaram Hospital, New Delhi	Severe Preeclampsia with Pulmonary Edema, Mimicking COVID-19 Infection in Pregnancy
9	Dr Panchampreet Kaur	Appreciation Prize	Sitaram Bhartia Institute Of Science And Research, New Delhi	Maternal Hyponatremia Leading to Neonatal Seizures: A case series and review of literature
10	Dr Pragati Aggarwal	Appreciation Prize	Hamdard Institute Of Medical Sciences And Research Jamia Hamdard New Delhi	Transplacental COVID Antibodies and Cytokine Storm in Newborn: Antibodies do not confer protection
11	Dr Ritu Yadav	Appreciation Prize	Aiims New Delhi	A Rare Case of Chronic Refractory ITP in Pregnancy with Unusual Complication and Successful Management
12	Dr Suma Shet	Appreciation Prize	Aiims Jodhpur	Herlyn Werner Wunderlich Syndrome
13	Dr Sunaina Agarwal	Appreciation Prize	Esi-Pgimsr	A Case Report on the Management of a Referred Case of Intra Operative Extensive Bladder Trauma during LSCS
14	Dr Tarun Kumar Das	Appreciation Prize	Sir Gangaram Hospital, New Delhi	Osteosarcoma in Pregnancy: A rare case
15	Dr Zaheda Aziz	Appreciation Prize	Aiims Bhubaneswar	Teratoma, the Culprit: Anti NMDAR Encephalitis with mature ovarian teratoma

## Statistics of 42<sup>nd</sup> Annual e-Conference of AOGD, 2020

1. Total number of registration	825
2. PG Registration	230
3. International Faculty	23
4. National Faculty	279
5. Total number of Free Paper	125
6. Total number of Poster	67
7. Total number of Competition Papers	102
8. Average daily attendance at the Conference	750-800
9. Average daily attendance at each Workshop	350-400


# Cross Word Puzzle

**Ruma Satwik**

Consultant, Centre of IVF and Human Reproduction, Sir Gangaram Hospital, New Delhi

## CROSSWORD

Test your knowledge of Reproductive Anatomy and Physiology



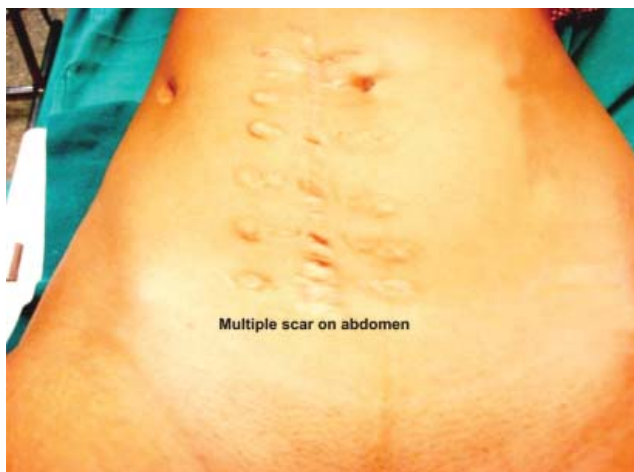### Across

1. Classification for Deep Endometriosis (6)
2. Nerve found deep to the bifurcation of common iliac vessels(9)
7. Operative technique to excise deep infiltrating recto-sigmoid endometriosis (7,8)
8. Depth of endometrial-like tissue below the peritoneum in deep endometriosis should be > ----- mm (4)

### Down

1. Handheld, battery operated, portable office hysteroscope with a touch screen display of 3.5 inches (7)
2. Open Adenomyomectomy technique that employs palpation, cold knife excision and Triple flap method for reconstruction (5)
3. Glandular tissue present 2.5mm below the endomyometrial junction (11)
4. In order to reduce OR floor crowding, Laparoscopic equipment should be ----- mounted. (7)
5. The vessel that crosses the ureter in the pelvis (7)
6. Energy source that is used with Versascope hysteroscope (7)

## PICTORIAL QUIZ



Ques 1. What are the various non-umbilical laparoscopic entry point in case of severe adhesions in the abdomen?

Answer to November Crossword and Pictorial Quiz given on Page No. 56



## AOGD Events Held

- On 6<sup>th</sup> August, 2020 - A programme on **"breast feeding"** for patients at DDUH by multidisciplinary patient sub-committee, AOGD
- On 6<sup>th</sup> August, 2020 - A webinar on **"Revisiting the genes behind gynaecological cancers- implications in clinical practice."** By Gynae forum, Dwarka in association with Manipal Hospital, under \*Aegis of Multidisciplinary committee of AOGD
- On 25<sup>th</sup>-26<sup>th</sup> August, 2020 - A Public awareness lecture on **"Menopause"** by Multidisciplinary committee AOGD in association with Lioness club Anaya
- On 28<sup>th</sup> August, 2020 - A Health talk on **"Menopause"** by Multidisciplinary patient sub committee, AOGD along with Lioness club Ananya
- On 3<sup>rd</sup> September, 2020 - A panel discussion on **"PPH"** by Multidisciplinary committee of AOGD
- On 8<sup>th</sup> September, 2020 - A Webinar on **"Emergency Contraception"** by Multidisciplinary committee of AOGD
- On 22<sup>th</sup> September, 2020 - A Webinar on **"Calcium therapy in pregnancy"** by multidisciplinary committee of AOGD
- On 28<sup>th</sup> September, 2020 - A Webinar on **"Ovarian Factor Evaluation & Ovarian Reserve Testing"** by multidisciplinary committee, AOGD
- On 4<sup>th</sup> October 2020 - Webinar on **"Infertility"** by AOGD Infertility Committee.
- On 5<sup>th</sup> October 2020 - Webinar on **"Cervical Stenosis: Overpassing Safely"** and panel discussion on **"Intrauterine Adhesions: Diagnostic & Therapeutic Challenges, Experience and Evidences"** in Endoscopy Fiesta by Endoscopy Committee AOGD & IAGE Delhi Chapter.
- On 5<sup>th</sup> October 2020 - Webinar on **"Transcending Hormones"** by Reproductive Endocrinology Committee, AOGD DGF South-West Delhi and Sonoschool India.
- On 8<sup>th</sup> October 2020 - Public awareness webinar on **"Menstrual Disorders and PCOD"** by Rural Health Committee of AOGD in association with LIONESSE CLUB.
- On 10<sup>th</sup> October 2020 - Webinar on **"Onco-fertility"** by IMA Dwarka Gynae Forum and Infertility Committee of AOGD.
- On 10<sup>th</sup> October 2020 - Webinar on **"Oncology Classes Part I"** by DF South-West and Multidisciplinary Patient Sub Committee of AOGD.
- On 14<sup>th</sup> October 2020 - Webinar on **"Endoscopy E-Summit"** by AOGD and Maharashtra Chapter of IAGE.
- On 20<sup>th</sup> October 2020 - Webinar on **"Breast Lumps: What to do, when to do?"** by Rural Health Committee AOGD and women doctors wing IMA West Ghaziabad.
- On 28<sup>th</sup> October 2020 - Webinar on **"Antepartum Haemorrhage"** by Obs. & Gyn. Society of Delhi, Kolhapur, Navi Mumbai and Thane.
- On 23<sup>rd</sup> October 2020 - **E-Quiz -Slogan Competition**
- On 24<sup>th</sup> October 2020 - **E-Poster & Free Papers**
- On 26<sup>th</sup> -29<sup>th</sup> October 2020 - **Pre Conference Workshops**
- 30<sup>th</sup>-31<sup>st</sup> October & 1<sup>st</sup> November 2020 - **42<sup>nd</sup> Annual Virtual AOGD Conference**
- 2<sup>nd</sup> -6<sup>th</sup> November 2020 - **Post Conference Workshops**

## Forthcoming Events

- On 26<sup>th</sup> November, FOGSI-JOGI-E-PICSEP 2020 Webinar will be held under the aegis of AOGD
- On 27<sup>th</sup> November, AOGD Monthly Meeting will be Organized by MAMC & LNJP Hospital, New Delhi
- On 28<sup>th</sup> November, **"Virtual CME on Diabetes in Pregnancy: Providing Optimum Care"** under the aegis of Quality Improvement and Safe Motherhood Committee of AOGD & Delhi Diabetic Forum to Celebrate World Diabetes Day
- On 29<sup>th</sup> - 30<sup>th</sup> November, **"Sankalp Family Planning Workshop for WA"**.

## Journal Scan

**Geeta Mediratta**

Senior Consultant, Institute of Obstetrics & Gynaecology, Sir Ganga Ram Hospital, New Delhi

Source: The Journal of Minimally Invasive Gynecology (JMIG), The, 2020-11-01, Volume 27, Issue 7, Pages S1-S2, 2020

### Laparoscopy in Pregnancy: A primer

M A Stuparich, S Nahas and S Behbehani

#### Abstract 1

**Study Objective:** To present principles and techniques for safe and efficient laparoscopic surgery during pregnancy.

**Design:** Stepwise demonstration of techniques with narrated video footage.

**Setting:** Laparoscopic surgery during pregnancy is safe and effective with an associated miscarriage rate of 1.3%. When feasible, it should be performed early in the 2<sup>nd</sup> trimester. In this video, we review key principles and techniques to safely perform laparoscopic surgery during pregnancy.

**Patients or Participants:** A 34-year-old female at 18 weeks 4 days gestation presents with a 7 cm ovarian mass causing right lower quadrant (RLQ) pelvic pain.

#### Interventions

The key principles for safe and effective laparoscopic surgery during pregnancy include:

1. Auscultation of fetal heart tones before and after the procedure
2. Use of pneumatic compression devices for thromboprophylaxis
3. Left lateral tilt of the patient to relieve pressure on the aorta and vena cava from the gravid uterus
4. Lateral tilt of the operating table and/or use of a sponge stick in the vagina to improve visualization
5. Careful peritoneal entry with use of Hasson technique or entry at Palmer's point
6. Lowering the insufflation pressure during surgery
7. Avoidance of touching the uterus within the peritoneal cavity
8. Avoidance of routine use of tocolytics

**Measurements and Main Results:** The patient recovered well without any obstetrical or postoperative complications.

#### Conclusion

When performing laparoscopic surgery in pregnancy, a surgeon should remember these key perioperative modifications for a safe and efficient procedure.

Source: Journal of Minimally Invasive Gynecology (JMIG), The, 2020-11-01, Volume 27, Issue 7, Pages S6-S6, 2020

### Social Media in Minimally Invasive Gynecologic Surgery: What is #trending?

R Sinha, R K Shibata, A Patel and J A Sternchos

#### Abstract 2

**Study Objective:** Surveys report seven-in-ten Americans use some form of social media<sup>1</sup>. Risks of social media platforms include spread of misinformation and information overload. Patients share and obtain health-care related information on such platforms. We aim to evaluate content and authorship of popular gynecological topics posted on Instagram.

**Design:** Retrospective content analysis.

**Setting:** Instagram

**Patients or Participants:** N/A

**Interventions:** N/A


**Measurements and Main Results:** A query of endometriosis, adenomyosis, fibroids, and hysterectomy yielded 237 hashtags. The top 10 and most recent 20 posts (determined by Instagram's internal algorithm) for 10 popular hashtags were quantitatively (likes, comments) and qualitatively (content, authorship) reviewed. Posts cross-tagged with infertility, other chronic diseases; videos; or foreign language posts were excluded.

The 10 popular hashtags investigated were linked to 2,301,238 posts: #endometriosis (N=1,461,668), #endometriosisawareness (N=324,041), #fibroids (N=143,197), #adenomyosis (N=98,101), #hysterectomy (N=87,176), #endometriosiswarrior (N=52,503), #endometriosisawarenessmonth (N=47,728), #hysterectomyrecovery (N=35,124), #endometriosisucks (N=26,568), #endopain (N=25,132).

Of 300 posts evaluated, 97.3% were by non-healthcare authors (patients, 55%); 1.6% were authored by verified physicians/professional society. The most common content for non-healthcare authored posts was personal experience (30.67%). Educational content accounted for 4.6% posts; none were authored by a health-care profile ( $p<0.00001$ ). The most common post authored by a verified physician was promotion for uterine fibroid embolization (0.67%). Other promotional content irrespective of author included seed supplements, "yoni steam," and workshops with an "endometriosis coach" and "period fixer."

## Conclusion

Over 2 million posts on gynecological conditions were identified on Instagram. The majority were authored by patients sharing their personal experience. The most popular topic was endometriosis. Few educational posts were identified. Official healthcare presence was significantly lacking. Physician involvement in social media may lead to improvements in patient education, physician-patient relationship, and knowledge in MIGS.



## Centre of IVF and Human Reproduction **SIR GANGA RAM HOSPITAL**

Your Safety is Our Priority

Restarting Essential Fertility and IVF Services

Continuing Obstetrics Services

### Restarting IVF treatment at Sir Ganga Ram Hospital

- ❖ Your work and travel commitments are less at this time
- ❖ SGRH is a COVID free hospital
- ❖ Less waiting time as fewer patients in the hospital
- ❖ All treatment by tele-medicine
- ❖ Multiple safety precautions setup by hospital
- ❖ Backup team of clinicians and embryologist for every patient

Dr Abha Majumdar

Dr Shweta Mittal

Dr Gaurav Majumdar

Dr M Kochhar

Dr Neeti Tiwari

Dr Ruma Satwik

For  
appointment call us at  
**+91-11-42254000**

For  
IVF appointments or  
queries call us at  
**+91-11-42251777**

Tele-consultations available to visit [www.sgrh.com](http://www.sgrh.com) or download my follow-up app



